

## CASE FOR DIAGNOSIS

### Crateriform Tumor of 2 Years' Duration\*



#### Tumor crateriforme de dos años de evolución

#### Medical History

A 49-year-old man with no medical or surgical history of interest consulted for a lesion on the skin of the right pectoral area that had appeared at least 2 years earlier. The lesion was asymptomatic and had not increased in size or shown other changes, although the patient reported discomfort caused by rubbing, and for this reason requested excision of the lesion.

#### Physical Examination

Physical examination revealed a solitary tumor of 15 mm in diameter located on the chest. The lesion was similar in color to the surrounding skin, and had a firm consistency with a keratotic, crateriform center (Fig. 1).

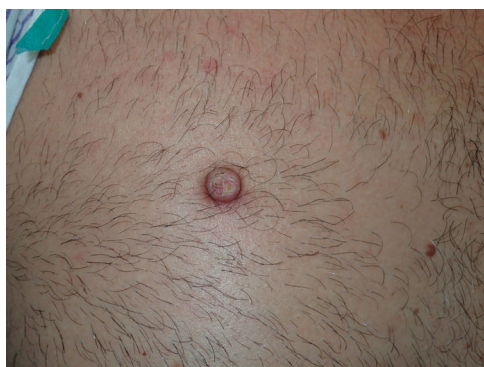

Figure 1 Macroscopic appearance of the lesion.

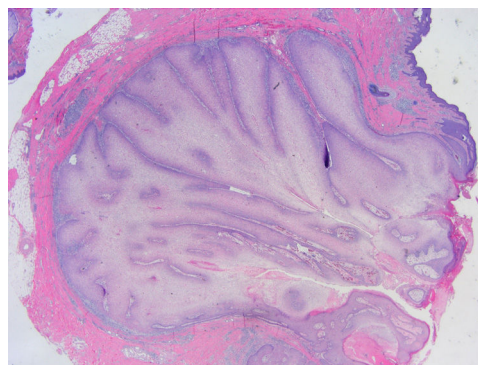


Figure 2 Hematoxylin-eosin, original magnification  $\times 40$ .

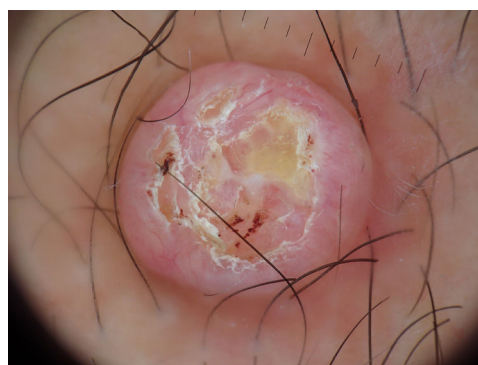

Figure 3 Dermoscopic image of the lesion.

#### Histopathology

Histopathology showed a branched, endophytic tumor of epithelial origin that had neat borders and a follicular appearance, contained clear cells without atypia, and did not reach the resection margin (Fig. 2).

#### Additional Tests

Dermoscopy revealed a tumor with a keratinized center and irregular yellowish areas. Fine radial vessels and some poorly focused fine telangiectasias were visible in the periphery (Fig. 3).

#### What is Your Diagnosis?

\* Please cite this article as: Gómez Arias PJ, Salido Vallejo R. Tumor crateriforme de dos años de evolución. *Actas Dermosifiliogr.* 2021;112:915–916.

**Diagnosis**

Inverted follicular keratosis.

**Course**

Complete excision of the lesion was carried out, without having confirmed recurrence during follow-up.

**Comment**

Inverted follicular keratosis is a rare benign tumor originating in the follicular infundibulum. It typically presents as a single nodule or papule, usually located on the face (mainly the eyelid, nose, upper lip, and cheek) and is more common in elderly men.<sup>1,2</sup>

Histology reveals an endophytic tumor in the form of an inverted cone that originates from the infundibular portion of the hair follicle and forms a lobulated mass of follicular sheath epithelium that extends into the dermis. The peripheral portion is composed of several rows of cells with a basaloid appearance. The center contains smaller basaloid cells mixed with keratinizing cells and keratin pearls. The lesion may be accompanied by fibrosis, a chronic inflammatory infiltrate, or increased vascularity.<sup>3</sup>

Some authors consider it a variant of seborrheic keratosis or the common wart, while others classify it as an independent entity owing to its follicular origin.<sup>2</sup> It has been speculated that inverted follicular keratosis is a lesion caused by human papillomavirus (HPV).<sup>1</sup> The presence of this lesion could constitute a marker of Cowden syndrome, especially in patients with multiple lesions.<sup>4</sup>

The differential diagnosis includes keratinizing tumors, such as cutaneous squamous carcinoma and keratoacanthoma, as well as other variants of pigmented keratosis pilaris, including pigmented basal cell carcinoma, seborrheic keratosis, common warts, and even melanoma.<sup>2</sup> Diagnosis is usually established based on histology of the excised lesion.

The most common dermoscopic finding in patients with inverted follicular keratosis is a keratoacanthoma-like pattern, with a central keratinized area surrounded by radially arranged hairpin vessels. The presence of a whitish-yellowish central area with radially arranged peripheral vessels and/or whitish or red blood cells has also been described.<sup>5</sup>

The most common treatment is surgical excision, although complete resolution has been reported after treatment with 5% imiquimod. Recurrence after complete excision is very rare.

**Funding**

This work has not received any type of funding.

**Conflicts of Interest**

The authors declare that they have no conflicts of interest.

**Acknowledgments**

The authors thank Dr. José Luis Rodríguez Peralto for his essential assistance with the histopathological diagnosis and description of the case.

**References**

1. Karadag AS, Ozlu E, Uzuncakmak TK, Akdeniz N, Cobanoglu B, Oman B. Inverted follicular keratosis successfully treated with imiquimod. *Indian Dermatol Online J.* 2016;7:177–9.
2. Thom GA, Quirk CJ, Heenan PJ. Inverted follicular keratosis simulating malignant melanoma. *Australas J Dermatol.* 2004;45:55–7.
3. Mehregan AH. Inverted follicular keratosis is a distinct follicular tumor. *Am J Dermatopathol.* 1983;5:467–70.
4. Larumbe A, Iglesias EM, Illarramendi JJ, Córdoba A, Gállego M. Acral keratoses and inverted follicular keratosis presenting Cowden disease. *Actas Dermosifiliogr.* 2007;98:425–9.
5. Llambrich A, Zaballos P, Taberner R, Terrasa F, Bañuls J, Pizarro A, et al. Dermoscopy of inverted follicular keratosis: study of 12 cases. *Clin Exp Dermatol.* 2016;41(July):468–73.

P.J. Gómez Arias,\* R. Salido Vallejo

*UGC de Dermatología Médico-Quirúrgica y Venereología, Hospital Universitario Reina Sofía, Córdoba, Spain*

\* Corresponding author.

*E-mail address:* [pjga10@hotmail.com](mailto:pjga10@hotmail.com) (P.J. Gómez Arias).