

## Hidradenitis Suppurativa Treated With Apremilast: A Case Series\*



### Hidradenitis suppurativa tratada con apremilast: serie de casos

To the Editor:

Therapeutic options for the treatment of hidradenitis suppurativa (HS) are limited, and are further reduced with increasing disease severity.<sup>1,2</sup> Apremilast is a phosphodiesterase 4 inhibitor that exerts an immunomodulatory effect, partially blocking the expression of pro-inflammatory cytokines and inducing expression of anti-inflammatory cytokines.<sup>3</sup> It is currently indicated in adult patients diagnosed with plaque psoriasis and/or psoriatic arthritis who do not respond to conventional systemic therapy. Based on the hypothesis that apremilast acts on multiple cells involved in the pathogenesis of HS (T cells, natural killer cells, neutrophils, monocytes, and dendritic cells), several studies have sought to characterize its efficacy in the treatment of this disease.<sup>4,5</sup>

We conducted an observational, descriptive, retrospective study of patients who were diagnosed with HS and treated with apremilast in our hospital between January 2015 and February 2020. [Tables 1 and 2](#) summarize the clinical variables and efficacy and safety findings. Seven patients (3 women and 4 men; mean age, 37.43 y) were recruited. Most had severe disease (Hurley stage III) when treatment began. The predominant phenotypes were type II (axillary) and type III (gluteal). Medical histories of interest included concomitant psoriasis in 3 patients, pyoderma gangrenosum and acne (pyoderma gangrenosum, acne, and suppurative hidradenitis [PASH] syndrome) in 1 patient, and chronic lymphatic leukemia in partial remission in 1 patient. Two patients had received no previous biological treatment, one due to a history of cancer and the other due to needle phobia. Treatment was discontinued in 2 patients at week 12 due to therapeutic failure.

In the intention-to-treat analysis, 43% of patients achieved hidradenitis suppurativa clinical response (HiSCR50) at week 24. We observed a reduction in the pain visual analog scale (VAS) score of  $\geq 2$  points in 57% of patients, a reduction in patient global assessment (PGA) score of  $\geq 1$  point in 29% of patients, and a decrease in the Dermatology Life Quality Index (DLQI) of  $\geq 30\%$  in 43% of patients at week 24. The evolution of the different response scales (international hidradenitis suppurativa severity score system [IHS4], PGA, pain VAS, and

DLQI) at 12 and 24 weeks is shown in [Figure 1](#). Analysis at 6 months revealed a significant reduction in pain ( $P=0.042$ ) and the impact of the disease on quality of life ( $P=0.043$ ). Only 2 patients had mild gastrointestinal adverse effects that did not require discontinuation of treatment.

In recent years, various published case series have supported the use of apremilast as a therapeutic alternative in patients with HS.<sup>3</sup> Moreover, 2 clinical trials have recently been conducted. The first,<sup>4</sup> a double-blind randomized clinical trial ( $n=15$ ), evaluated the efficacy and tolerance of apremilast for 16 weeks. The second,<sup>5</sup> an open phase II clinical trial ( $n=20$ ), evaluated efficacy and safety in patients with mild-to-moderate HS for 24 weeks. Both trials reported a similar response rate: 60% of patients achieved HiSCR50 and a reduction of at least 2 points in pain VAS score was observed in 30% of patients by week 24. Up to 45% of the patients experienced at least one adverse effect, the most frequent of which was diarrhea.

Comparison of the baseline characteristics of the patients in our series with those of the aforementioned clinical trials ([Table 2](#)) reveals a similar mean age, but a greater proportion of male patients and higher mean baseline PGA and DLQI values in our series. While a similar percentage of patients achieved HiSCR50 across the 3 studies, we observed a considerably greater reduction in pain VAS score at week 24. Therefore, despite the more severe baseline disease and greater impairment of quality of life in our series, the proportion of patients that achieved a therapeutic response was similar to that of the other 2 studies. The retrospective nature of our series may partly explain the lower percentage of adverse effects recorded.

Although psoriasis and HS may share pathogenic mechanisms, the combination of these 2 conditions is rare. We have found only 1 published case describing apremilast treatment of a patient diagnosed with both diseases.<sup>6</sup> In our series, 3 patients presented both diseases: a good response of both HS and psoriasis was observed in 2 of these patients, while the third patient stopped treatment due to primary HS treatment failure.

Apremilast could constitute a therapeutic alternative for HS patients who have exhausted other treatment options for which there is greater supporting evidence. We believe that apremilast may be beneficial for the treatment of HS patients with a history of neoplastic disease, paradoxical reactions to tumor necrosis factor (TNF) inhibitors, and active infections, as well as those who decline subcutaneous or parenteral treatments.

### Conflicts of Interest

The authors declare that they have no conflicts of interest.

\* Please cite this article as: Garbayo-Salmons P, Expósito-Serrano V, Ribera Pibernat M, Romaní J. Hidradenitis suppurativa tratada con apremilast: serie de casos. *Actas Dermosifiliogr.* 2021;112:936-939.

**Table 1** Summary of the Characteristics of the Patients 1–6 Included in our Series (n = 7).

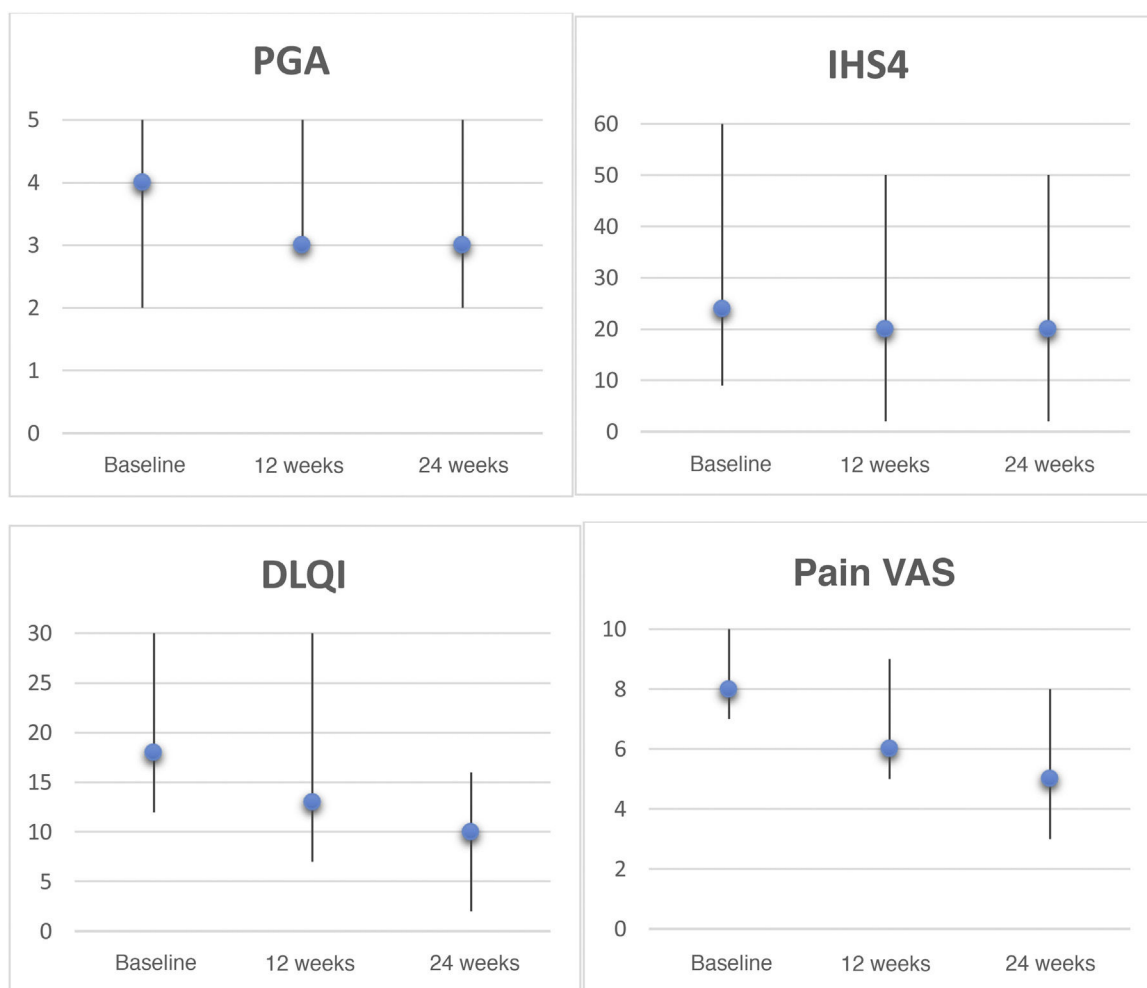
| Patient | Age, y | Sex | BMI, kg/m <sup>2</sup> | Medical History                              | Predominant HS Phenotype | Systemic Treatments Before Apremilast Treatment   | Reason for Starting Apremilast Treatment | Reason for Interrupting Apremilast Treatment | Baseline Hurley Stage | PGA (Baseline/Week 24) | IHS4 (Baseline/Week 24) | DLQI (Baseline/Week 24) | Pain VAS (Baseline/Week 24) |
|---------|--------|-----|------------------------|--|--------------------------|---|--|--|-----------------------|------------------------|-------------------------|-------------------------|-----------------------------|
| 1       | 43     | F   | 31.6                   | Psoriasis, depression                        | I                        | Oral antibiotics<br>Adalimumab<br>Infliximab  | Lack of response to previous treatments  | Lack of therapeutic response at 3 months     | III                   | 4/-                    | 20/-                    | 20/-                    | 7/-                         |
| 2       | 36     | M   | 28.6                   | Psoriasis, hypertension, diabetes mellitus 2 | III                      | Oral antibiotics<br>Systemic corticosteroids<br>Adalimumab<br>Infliximab<br>Ustekinumab | Lack of response to previous treatments  | NA   | III                   | 5/5                    | 60/50                   | 18/16                   | 10/8                        |
| 3       | 46     | F   | 34                     | None   | 1                        | Oral antibiotics<br>Systemic corticosteroids<br>Adalimumab<br>Infliximab                | Lack of response to previous treatments  | NA   | III                   | 4/3                    | 20/20                   | 18/13                   | 6/5                         |
| 4       | 27     | M   | 21                     | PASH syndrome                                | 2                        | Oral antibiotics  | Paradoxical response to TNF inhibitors   | NA   | III                   | 3/3                    | 40/20                   | 18/10                   | 9/3                         |
| 5       | 20     | M   | 25.7                   | None   | III                      | Adalimumab<br>Oral antibiotics  | Needle phobia                            | NA   | 2                     | 2/2                    | 9/2                     | 12/5                    | 6/3                         |
| 6       | 37     | M   | 36.3                   | Psoriasis, thalassemia                       | 1                        | Oral antibiotics<br>Systemic corticosteroids<br>Adalimumab<br>Infliximab<br>Ustekinumab | Lack of response to previous treatments  | NA   | III                   | 4/3                    | 25/8                    | 22/6                    | 8/6                         |
| 7       | 53     | F   | 28                     | Chronic lymphocytic leukemia                 | III                      | Oral antibiotics<br>Systemic corticosteroids  | Comorbidities (concomitant neoplasia)    | Lack of therapeutic response at 3 months     | III                   | 4/-                    | 24/-                    | 30/-                    | 10/-                        |

Abbreviations: BMI, body mass index; DLQI, Dermatology Life Quality Index; F, female; IHS4, International HS Severity Score System; M, male; NA, not applicable; PASH, pyoderma gangrenosum, acne, and hidradenitis suppurativa; PGA, Physician's Global Assessment; TNF, tumor necrosis factor; VAS, pain visual analogical scale.

**Table 2** Comparison of the Results of Previous Clinical Trials and of the Present Series.

|   | Vossen et al    | Kerdel et al   | Present Series |
|---|-----------------|----------------|----------------|
| <b>Baseline patient characteristics</b> |                 |                |                |
| Number of patients                      | 15              | 20             | 7              |
| Follow-up duration, wk                  | 16              | 24             | 24             |
| Mean baseline PGA                       | 3               | 2.7            | 3.71           |
| Mean age, y                             | 35.7            | 32.5           | 37.43          |
| Sex                                     | 12/3            | 14/6           | 3/4            |
| Mean baseline DLQI                      | 14.6            | 11             | 19.71          |
| Mean pain VAS score (0–10)              | 5               | 2.6            | 8              |
| <b>Efficacy and safety</b>              |                 |                |                |
|   | n, % (wk)       | n, % (wk)      | n, % (wk)      |
| HiSCR50                                 | 8/15; 53.3 (16) | 12/20; 60 (24) | 3/7; 43 (24)   |
| Decrease in pain VAS $\geq 2$ points    | -               | 6/20; 30 (24)  | 4/7; 57 (24)   |
| Decrease in PGA $\geq 1$ point          | -               | 10/20; 50 (24) | 2/7; 29 (24)   |
| Decrease in DLQI $\geq 30\%$            | -               | -              | 3/7; 43 (24)   |
| $\geq 1$ adverse effect                 | 6/15; 40 (16)   | 9/20; 45 (24)  | 2/7; 28.6 (24) |

Abbreviations: DLQI, Dermatology Life Quality Index; HiSCR50, hidradenitis suppurativa clinical response; PGA, Physician’s Global Assessment; VAS, pain visual analogue scale.



**Figure 1** Clinical rating scales for hidradenitis suppurativa patients treated with apremilast. Graphs depict the Physician’s Global Assessment (PGA), International HS Severity Score System (IHS4), Dermatology Life Quality Index (DLQI), and pain visual analogue scale (VAS, 0–10) scores, expressed as the median and range, at baseline, week 12, and week 24. Statistical analyses were performed to evaluate decreases after 6 months using the Wilcoxon test for paired samples: PGA,  $P=0.157$ ; IHS4,  $P=0.068$ ; DLQI,  $P=0.043$ ; pain VAS,  $P=0.042$ .

## References

- Zouboulis CC, Bechara FG, Dickinson-Blok JL, Gulliver W, Horváth B, Hughes R, et al. Hidradenitis suppurativa/acne inversa: A practical framework for treatment optimization—systematic review and recommendations from the HS ALLIANCE working group. *J Eur Acad Dermatol Venereol*. 2019;33:19–31.
- Martorell A, García FJ, Jiménez-Gallo D, Pascual JC, Pereyra-Rodríguez J, Salgado L, et al. Update on hidradenitis suppurativa (Part II): Treatment. *Actas Dermosifiliogr*. 2015;106:716–24.
- Weber P, Seyed Jafari SM, Yawalkar N, Hunger RE. Apremilast in the treatment of moderate to severe hidradenitis suppurativa: A case series of 9 patients. *J Am Acad Dermatol*. 2017;76:1189–91.
- Vossen ARJV, van Doorn MBA, van der Zee HH, Prens EP. Apremilast for moderate hidradenitis suppurativa: Results of a randomized controlled trial. *J Am Acad Dermatol*. 2019;80:80–8.
- Kerdel FR, Azevedo FA, Kerdel Don C, Don FA, Fabbrocini G, Kerdel FA. Apremilast for the treatment of mild-to-moderate hidradenitis suppurativa in a prospective, open-label phase 2 study. *J Drugs Dermatol JDD*. 2019;18:170–6.
- Lanna C, Mazzilli S, Zangrilli A, Bianchi L, Campione E. One drug and two diseases: A case of multidrug-resistant hidradenitis suppurativa and psoriasis treated with apremilast. *Dermatol Ther*. 2019;32:e13089.

P. Garbayo-Salmons\*, V. Expósito-Serrano, M. Ribera Pibernat, J. Romani

*Servicio de Dermatología, Hospital Universitario Parc Taulí, Sabadell, Spain*

\* Corresponding author.

E-mail address: [pgarbayo@gmail.com](mailto:pgarbayo@gmail.com) (P. Garbayo-Salmons).

<https://doi.org/10.1016/j.adengl.2021.09.009>

1578-2190/ © 2021 Published by Elsevier España, S.L.U. on behalf of AEDV. This is an open access article under the CC BY-NC-ND license (<http://creativecommons.org/licenses/by-nc-nd/4.0/>).

## Leflunomide-Induced Phototoxic Reaction in a Woman With Systemic Lupus Erythematosus<sup>☆</sup>



### Erupción fototóxica inducida por leflunomida en una paciente con lupus eritematoso sistémico

To the Editor:

Leflunomide is an immunosuppressive agent that has been approved by the United States Food and Drug Administration for the treatment of rheumatoid arthritis and psoriatic arthritis. It is also widely used off-label in other diseases, such as ankylosing spondylitis and systemic lupus erythematosus (SLE). Leflunomide can produce adverse effects, the most common of which are gastrointestinal symptoms, hypertension, and alopecia. Although considered an efficacious and safe drug for the treatment of SLE, leflunomide has been associated with cases of skin rash, such as erythema multiforme<sup>1</sup>, toxic epidermal necrolysis<sup>2</sup>, and vasculitis<sup>3</sup>, and it has even triggered skin lesions in subacute lupus erythematosus<sup>4</sup>.

A 25-year-old woman had been followed by the rheumatology department for a 4-year history of SLE. The diagnostic criteria did not include a history of photosensitivity. Initial treatment was with rituximab (500 mg every 15 days, 2 sessions), oral prednisone in tapering doses, and subcutaneous methotrexate (17.5 mg weekly). Owing to gastrointestinal adverse effects, methotrexate was replaced by leflunomide (3 daily doses of 100 mg followed by a maintenance dose of

20 mg/d) 3 months after initiation. Two months after starting treatment with leflunomide and after intense exposure to sunlight at the beach, the patient came to the clinic with a 24-h history of very pruritic generalized maculopapular rash (Fig. 1A-B), which progressed to vesicular-bullous lesions in 48 hours. These mainly affected the arms (Fig. 1C) and were associated with pustules on the forehead (Fig. 2A), vesicles on the area of the lips (Fig. 2B), and ecchymotic macules and papules on both axillae (Fig. 2C). Examination of the oral and genital mucosa was normal. The laboratory workup revealed high titers for antinuclear antibodies (1/640 U/mL), anti-Ro/SSA-60 (157), anti-Ro/SSA-52 (167), and rheumatoid factor (80 U/mL). Values for the remaining parameters, including C3 and C4, were normal. Serology testing (herpes simplex virus, cytomegalovirus, Epstein-Barr virus, and human herpesvirus 6) yielded negative results. Histopathology of a punch biopsy specimen from a bullous lesion on the posterior trunk revealed an atrophied epidermis with foci of necrotic keratinocytes and spongiosis, together with a subepidermal bullous formation and a moderate inflammatory perivascular mononuclear infiltrate of lymphocytes and eosinophils in the dermis that was compatible with phototoxic rash. Direct immunofluorescence was negative. Treatment with leflunomide was interrupted, and systemic treatment with oral prednisone (1 mg/kg/d) was started. The lesions had resolved completely after 10 days except for some residual hyperpigmentation.

Patients with SLE are particularly sensitive to sunlight, which is considered a trigger or aggravating factor of the disease. It is rare for a diagnosis of SLE not to include photosensitivity as a criterion. Of the various treatments used in SLE, leflunomide is not a first choice; therefore, it is used in selected patients who experience adverse effects associated with other drugs, such as methotrexate. The literature contains many articles that consider leflunomide as the sole cause of subacute cutaneous lupus erythematosus (SCLE)<sup>5</sup>, as well as SCLE associated with erythema multiforme-type lesions and erythema multiforme major. Some authors are in favor of diagnosing the co-occurrence of lupus erythematosus and erythema multiforme in the same patient as Rowell

<sup>☆</sup> Please cite this article as: Navarro-Triviño FJ, Lucas-Collado N, Salvatierra-Ossorio J. Erupción fototóxica inducida por leflunomida en una paciente con lupus eritematoso sistémico. *Actas Dermosifiliogr*. 2021;112:939–941.