

S. Igari, T. Ito, M. Ishikawa, T. Hiraiwa, T. Yamamoto*

Department of Dermatology, Fukushima Medical University, Fukushima, Japan

* Corresponding author.

E-mail address: toyamade@fmu.ac.jp (T. Yamamoto).

<https://doi.org/10.1016/j.adengl.2021.06.004>

1578-2190/ © 2021 Published by Elsevier España, S.L.U. on behalf of AEDV. This is an open access article under the CC BY-NC-ND license (<http://creativecommons.org/licenses/by-nc-nd/4.0/>).

Pityriasis Rosea in a Confirmed COVID-19 Pediatric Patient[☆]



Pitiriasis rosada en un paciente pediátrico con diagnóstico confirmado de COVID-19

Dear Editor:

On December 31, 2019, the World Health Organization identified a novel coronavirus (SARS-CoV-2) in the city of Wuhan in China that spread very quickly and has to date resulted in the deaths of thousands of people by causing COVID-19 disease. Various Coronavirus disease-19 (COVID-19) associated dermatological manifestations have been reported. Among these, Pityriasis rosea (PR) and PR-like rash have been published previously. During the COVID-19 pandemic, the diagnosis of PR has become more common¹⁻⁵.

PR is a self-limited inflammatory skin disease that can be induced viral agents especially HHV-6 (Human herpes virus 6), HHV-7 (Human herpes virus 7), autoimmunity, psychogenic factors, vaccines and drugs^{1,2}.

We present here a case of PR in a confirmed COVID-19 pediatric patient.

A 10-year-old boy presented with a 20-day history of skin rash. It was learned that he had Covid-19 infection about 1 month ago and he did not use any medication. In dermatological examination, there were small plaques with erythema and collary scaly located parallel to the ribs on the body (Fig. 1). Complete blood count, liver and kidney function tests, hepatitis markers, sedimentation and CRP values were in normal ranges. Histopathology of one lesion's biopsy showed focal parakeratotic peaks, spongiosis, focal spongiotic vesiculation, lymphocyte exocytosis, mildly irregular acanthosis with mild homogenization of collagen in the dermis, mild to moderate perivascular erythrocyte infiltration in the superficial vascular plexus, scattered lymphocyte infiltration, sparse lymphocytes was seen (Fig. 2). The diagnosis of PR after Covid -19 infection was established with clinical and histopathologic findings. The patient was treated with betamethasone valerate ointment, 10% urea and cetirizine. Lesions regressed one month later.

The association between PR and COVID-19 infection is not clearly known. In the literature, patients with confirmed COVID-19 developed PR and PR-like rash, some of them while asymptomatic or symptomatic disease, others after COVID-19 infection²⁻⁵. Therefore, in a patient presenting

with PR and PR-like rash, it is necessary to keep in mind Covid-19 infection and suggest SARS-CoV-2 testing for necessary patients. PR could be directly dependent to COVID-19 infection, or to viral reactivation (HHV-6, HHV-7, EBV)¹⁻⁵. In addition, the increased psychological stress caused by the pandemic period may have contributed to the trigger¹. Due to the limited number of data, it is very difficult to prove a causal relation in these cases.

In conclusion, dermatologists should be aware that cutaneous symptoms may be linked to COVID-19 infection.

Acknowledgment

The patient and his family in this manuscript have given written informed consent to publication of his case details.

References

1. Dursun R, Temiz SA. The clinics of HHV-6 infection in COVID-19 pandemic: Pityriasis rosea and Kawasaki disease. *Dermatol Ther.* 2020;33:e13730.

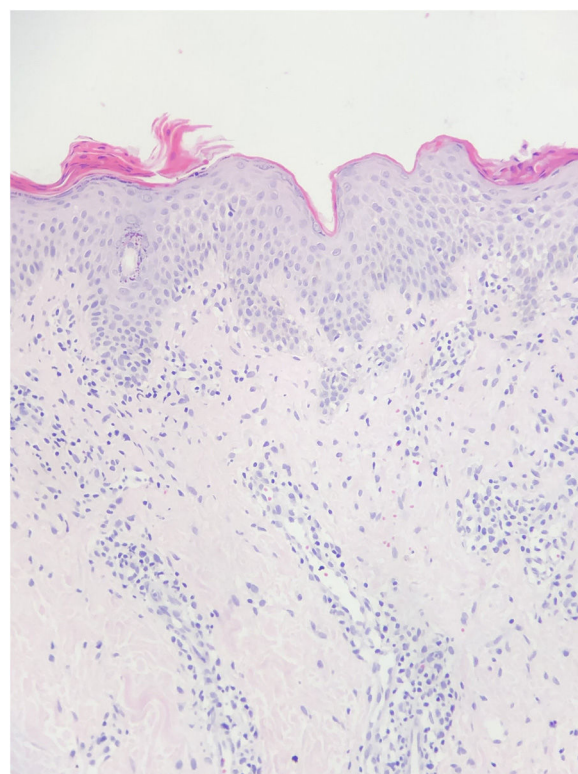


Figure 1 Diffuse erythematous lesions on the trunk and many of lesions had peripheral scales.

[☆] Please cite this article as: Öncü İNS, Güler D, Gürel G, Yalçın GŞ. Pitiriasis rosada en un paciente pediátrico con diagnóstico confirmado de COVID-19. *Actas Dermosifiliogr.* 2021;112:864–865.

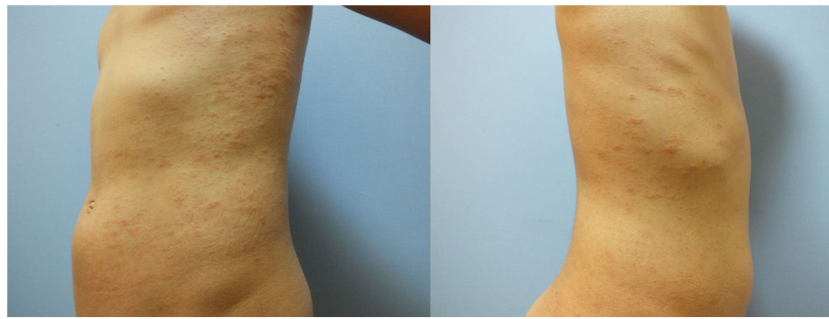


Figure 2 Focal mounds of parakeratosis, mild exocytosis of lymphocytes, mild perivascular mononuclear inflammatory cells and some extravasated erythrocytes (Hematoxylin & eosin, $\times 200$).

2. Veraldi S, Romagnuolo M, Benzecry V. Pityriasis rosea-like eruption revealing COVID-19. *Australas J Dermatol.* 2020;10:1111.
3. Drago F, Ciccarese G, Rebora A, Parodi A. Human herpesvirus-6, -7, and Epstein-Barr virus reactivation in pityriasis rosea during COVID-19. *J Med Virol.* 2020;24(10):1002.
4. Veraldi S, Spigariolo CB. Pityriasis rosea and COVID-19. *J Med Virol.* 2020;18(10):1002.
5. Johansen M, Chisolm SS, Aspey LD, Brahmbhatt M. Pityriasis rosea in otherwise asymptomatic confirmed COVID-19-positive patients: a report of 2 cases. *JAAD Case Rep.* 2021;7:93–4.

I.N.S. Öncü,^{a,*} D. Güler,^a G. Gürel,^a G.Ş. Yalçın^b

^a *Departamento de Dermatología, Facultad de Medicina, Afyonkarahisar Health Sciences University, Afyonkarahisar, Turkey*

^b *Departamento de Patología, Facultad de Medicina, Afyonkarahisar Health Sciences University, Afyonkarahisar, Turkey*

* Corresponding author.

E-mail address: oncuisin@gmail.com (I.N.S. Öncü).

<https://doi.org/10.1016/j.adengl.2021.07.006>
1578-2190/ © 2021 Published by Elsevier España, S.L.U. on behalf of AEDV. This is an open access article under the CC BY-NC-ND license (<http://creativecommons.org/licenses/by-nc-nd/4.0/>).

Plaque psoriasis in a patient with sarcoidosis[☆]



Psoriasis en placa en un paciente con sarcoidosis

Dear Editor,

A 65-year-old man was admitted to the respiratory department of our hospital, for the detail investigation of bilateral hilar lymphadenopathy. Examination by lung computed tomography revealed lymph node adenopathy (Fig. 1) and bronchoscopic lung biopsy revealed non-caseating epithelioid granulomas, and thus he was diagnosed with sarcoidosis. Also, he was suffering from diabetes mellitus for five years previously. During admission, he was referred to our department complaining of itchy eruptions of the upper limbs and ears. He stated that he was diagnosed with psoriasis eight years previously and treated with topical corticosteroids but without sufficient effects. On physical examination, scaly erythematous plaques were scattered on the knees, elbows, fingers and ears. Nail involvement was

not observed, and he had no arthritis. Skin lesions suggestive of sarcoidosis were not seen on the scalp, trunk and extremities including the knee. Results of laboratory examination elevated serum angiotensin converting enzyme (34.0 U/ml, normal; 8.3-21.4), sIL-2R (1850 U/ml,¹⁻⁴ normal; 121-613) and negative tuberculin reaction. Neither ocular nor cardiac sarcoidosis was detected in detailed examination. Histological examination from the knee lesion showed regular epidermal proliferation, intraepidermal neutrophil infiltration, parakeratosis, dilated vessels in the dermal papilla, and perivascular cellular infiltrates. CD4⁺ and CD8⁺ T-cells were detected in the epidermis and upper dermis. Sarcoid granulomas were not observed in the dermis or subcutis. The patient was treated with topical corticosteroid ointment.

The present patient first developed psoriasis, and five years later the diagnosis of sarcoidosis was made. He had been treated with topical therapy only, therefore it is unexpected that sarcoidosis was induced by medications for psoriasis. He had ocular and lung sarcoidosis, whereas cutaneous sarcoid lesions were not observed, at least at the initial visit to our department. To date, several cases of co-existence of psoriasis and sarcoidosis have been reported¹. Those cases usually present both cutaneous psoriatic and sarcoid skin lesion, whereas our patient did not exhibit cutaneous sarcoidosis. T helper(Th)1 type cytokines are favored in the initial phase of sarcoidosis. In particular, tumor necrosis factor (TNF)- α is important in the formation of sarcoid granuloma². A shared TNF- α -mediated patho-

[☆] Please cite this article as: Ishikawa M, Yamamoto T. Psoriasis en placa en un paciente con sarcoidosis. *Actas Dermosifiliogr.* 2021;112:865–866.