

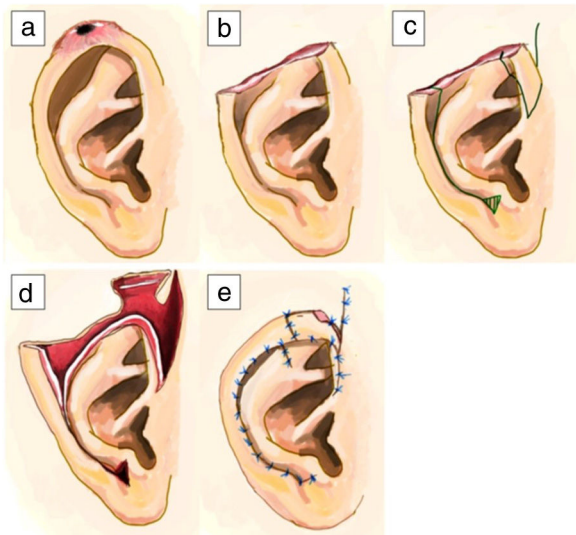Figure 3 Step-by-step schematic of the Antia-Buch technique for the upper pole: lesion in the upper pole of the ear (a). Defect after tumor resection (b). Flap design (c). Dissection of the chondrocutaneous advancement flaps (d). Positioning and suture of the flaps (e).

The Antia-Buch technique plays an important role in reconstruction of the upper pole of the ear; however, more complex techniques are preferred for defects measuring more than 20 mm.³ One of the concerns with the Antia-Buch flap for large defects is cup ear deformity. However, modifications to this technique, such as half-moon or wedge cuts of the antihelix and concha can avoid this problem.^{2,7,8} A main advantage of this technique is that it only requires one operation. This is desirable in patients of advanced age, those with comorbidities,⁷ or those with difficulties traveling to hospital; 3 conditions often seen in our everyday practice. With this case, we would like to highlight the simplicity and usefulness of this technique for reconstruction of large defects of the pinna in the upper pole, particularly when only one operation is desirable.

Conflicts of interest

The authors declare that they have no conflicts of interest.

References

1. Pérez-Paredes MG, Cucunubo-Blanco HA, González-Sixto B, Rodríguez Prieto M. Chondrocutaneous island flap for reconstruction of an antihelix defect. *Actas Dermosifiliogr.* 2015;106:503–4.
2. Kronic AL, Weitzul S, Taylor RS. Chondrocutaneous advancement flap for reconstruction of helical rim defects in dermatologic surgery. *Australas J Dermatol.* 2006;47:296–9.
3. Hénoux M, Espitalier F, Hamel A, Dréno B, Michel G, Malard O. Vascular supply of the auricle: anatomical study and applications to external ear reconstruction. *Dermatol Surg.* 2017;43:87–97.
4. Brodland DG. Advanced reconstruction of the ear. *Dermatol Surg.* 2014;40:S71–85.
5. Antia NH, Buch VI. Chondrocutaneous advancement flap for the marginal defect of the ear. *Plast Reconstr Surg.* 1967;39:472–7.
6. De Schipper HJ, van Rappard JH, Dumont EA. Modified Antia Buch repair for full-thickness middle auricular defect. *Dermatol Surg.* 2012;38:124–7.
7. Bialostocki A, Tan ST. Modified Antia-Buch repair for full-thickness upper pole auricular defects. *Plast Reconstr Surg.* 1999;103:1476–9.
8. Valesky EM, Kaufmann R, Meissner M. Chondrocutaneous helix rim advancement flap: two classical and two new modifications for very large defects of the ear. *J Eur Acad Dermatol Venereol.* 2015;29:2248–51.

J.C. Barrera Gamboa^{a,*}, Á.E. Acosta Madiedo de Hart^b

^a *Instituto Nacional de Cancerología, Bogotá D.C., Colombia*

^b *Instituto Nacional de Cancerología, programa curricular de dermatología, Universidad Nacional de Colombia, Bogotá D.C., Colombia*

* Corresponding author.

E-mail address: jcbgmd@hotmail.com

(J.C. Barrera Gamboa).

<https://doi.org/10.1016/j.adengl.2021.03.007>

1578-2190/ © 2020 AEDV. Published by Elsevier España, S.L.U. This is an open access article under the CC BY-NC-ND license (<http://creativecommons.org/licenses/by-nc-nd/4.0/>).

Ultrasound Features of Facial and Extrafacial Granuloma Facial. A Case Series[☆]

Características ecográficas del granuloma facial y extrafacial. Una serie de casos

Dear Editor:

Granuloma faciale (GF) is a rare benign inflammatory dermatosis of unknown aetiology, characterized by single or



multiple red-brown or violaceous cutaneous nodules or plaques, most frequently occurring on the face. GF is considered a form of localized chronic fibrosing vasculitis.¹ Diagnosis is commonly confirmed by skin biopsy, although the histopathological diagnosis of GF may be challenging, because precise histopathological criteria have not been defined. Differential diagnosis is broad and includes inflammatory diseases, malignancies and infections. High resolution ultrasound (HRU) is being used increasingly in dermatology, both for the diagnosis and monitoring of diverse inflammatory dermatoses and tumoral lesions.² We have not found publications about ultrasonographic features of GF. We aimed to describe the ultrasonographic characteristics of GF in a series of patients.

Patients with biopsy-proven GF who consulted at a Spanish tertiary referral hospital between January 2016 and May 2018 were included. Lesions were assessed using an Esaote MyLab Class C ultrasound machine with 18 and 22 MHz

[☆] Please cite this article as: Morgado-Carrasco D, Giavedoni P, Mascaró JM, Iranzo P. Características ecográficas del granuloma facial y extrafacial. Una serie de casos. *Actas Dermosifiliogr.* 2021;112:559–563.

Table 1 Characteristics of patients with granuloma faciale.

Case n	Sex/age (years)	Time of evolution (years)	Anatomic location	Previous treatments	Histological description	Ultrasound features (B-mode)	Doppler mode
1	m/39	5	right cheek	topical corticosteroids, hydroxychloroquine, dapsone, laser, topical tacrolimus	Presence of Grenz zone. Dense inflammatory infiltrate constituted mainly by eosinophils, few histiocytes, lymphocytes and occasional plasma cells.	Hypoechoic, heterogeneous and ill-defined lesion in dermis and hypodermis.	Increased vascularity
2	m/59	8	scalp	topical corticosteroids, doxycycline, topical tacrolimus	Presence of Grenz zone. Dense perivascular and perianexial inflammatory infiltrate constituted by histiocytes, lymphocytes, plasma cells and occasional eosinophils.	Subepidermal hypoechoic band Hypoechoic, heterogeneous and ill-defined lesion in dermis and hypodermis.	Vessels in dermis up to 0.63 mm in diameter. Increased vascularity
3	m/67	12	Ear	topical and intralesional corticosteroids, topical tacrolimus, hydroxychloroquine	Presence of Grenz zone. Dense lymphoplasmocytic inflammatory infiltrates in dermis.	Subepidermal anechoic band Hypoechoic, heterogeneous and ill-defined lesion in dermis and hypodermis.	Vessels in dermis up to 1.4 mm in diameter (PSV 9.2 cm/sec, EDV 2.7 cm/sec). Increased vascularity Vessels in dermis up to 0.8 mm in diameter.

Table 1 (Continued)

Case n	Sex/age (years)	Time of evolution (years)	Anatomic location	Previous treatments	Histological description	Ultrasound features (B-mode)	Doppler mode
4	f/68	1	Umbilicus	topical and intralesional corticosteroids, topical tacrolimus, hydroxychloroquine	Presence of Grenz zone. Dense lymphoplasmocytic inflammatory infiltrates in dermis.	Hypoechoic, heterogeneous and well-defined lesion in dermis and hypodermis.	Increased vascularity.
			nose	none	Presence of Grenz zone. Perivascular and interstitial inflammatory infiltrate constituted mainly by histiocytes, neutrophils, eosinophils and occasional plasma cells.	Subepidermal hypoechoic band Hypoechoic, heterogeneous and ill-defined lesion in dermis and hypodermis	Vessels in dermis up to 1.4 mm in diameter Increased vascularity.
5	m/71	13	nose	Imiquimod, cryotherapy	Dense inflammatory infiltrate constituted mainly by eosinophils, histiocytes, neutrophils and plasma cells. Papillary dermal Fibrosis.	Subepidermal anechoic band Hypoechoic and ill-defined lesion in dermis and hypodermis with posterior enhancement.	Vessels in dermis up to 0.96 mm in diameter (PSV 17.6 cm/sec, EDV 7.2 cm/sec). Increased vascularity
							Vessels in dermis up to 0.66 mm in diameter (PSV 16.3 cm/sec, EDV 5.9 cm/sec).

m, male; f, female PSV, Peak systolic velocity; EDV, end-diastolic velocity.

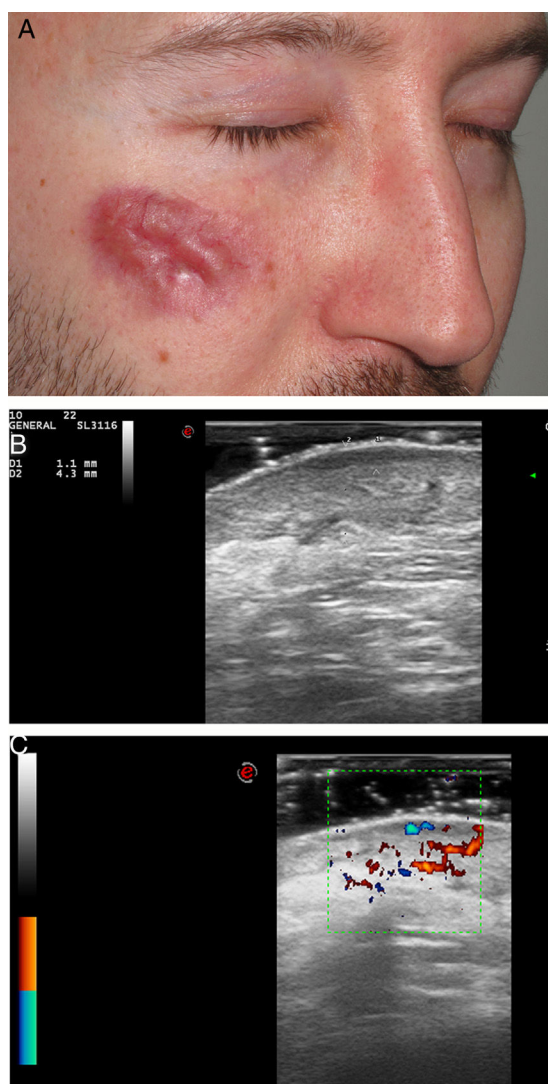

Figure 1 Granuloma faciale. A. Case 1: erythematous-violaceous plaque on the right cheek. B. Hypoechoic, heterogeneous lesion in dermis and hypodermis, measuring 4,3 mm thick. Note the subepidermal hypoechoic band (22 MHz probe, B-mode). C. Increased vascularity on color Doppler mode.

probes. All the sonographic examinations were performed by following published guidelines for studying dermatologic lesions that include grayscale and color Doppler imaging.³ All patients gave oral and written consent for inclusion in the research and for publication of images.

Five patients (six lesions) (four men and one woman) with a median age of 67 years (range, 39-71) and a biopsy-proven GF were included. In three of patients the lesions were located on the face, one on the scalp, one on the ear and one on the umbilicus. Most patients had undergone several treatments without clinical improvement (Table 1). On ultrasonographic evaluation, GF presented in all patients as a hypoechoic and heterogeneous lesion in dermis and hypodermis with an increased vascularity on color Doppler mode (Fig. 1-2). Almost all lesions (5/6) were ill-defined. In 5/6 GF a marked subepidermal hypoechoic/anechoic band was observed. One lesion (case 5, nose) presented a pos-

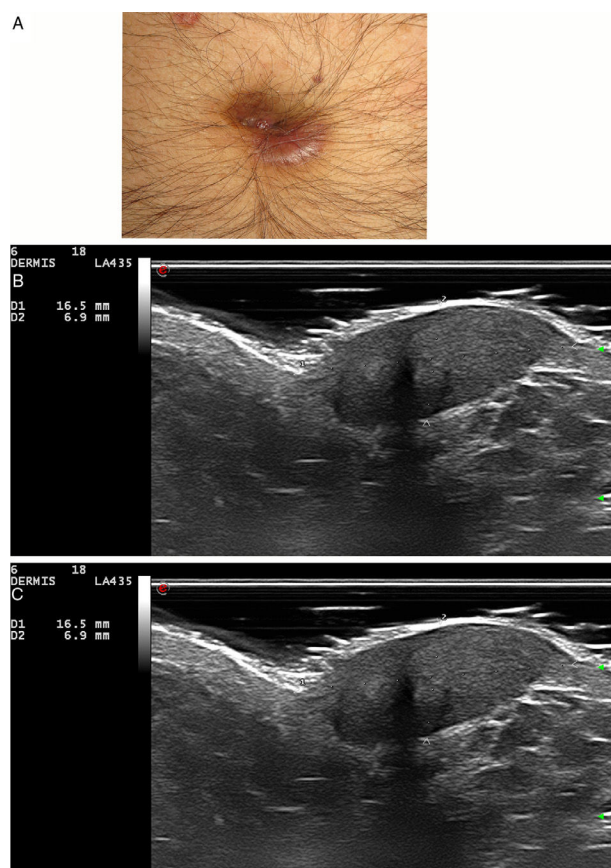


Figure 2 Granuloma faciale. A. Case 3: violaceous nodule on the umbilicus. B. Hypoechoic, well-defined and heterogeneous lesion in dermis and hypodermis, measuring 6.9 mm thick (18 MHz probe, B-mode). C. Marked increase in vascularity (18 MHz probe, color Doppler mode).

terior enhancement. There were no significant differences in ultrasound characteristics between facial and extrafacial GF (Table 1).

Diagnosis of erythematous skin lesions occurring on the face can be challenging. GF can be a highly disfiguring pathology, and it is essential to perform the differential diagnosis with dermatosis of similar clinical appearance, but different treatment such as sarcoidosis, lupus vulgaris, rosacea, fungal infection, mycobacteriosis, discoid lupus erythematosus, adverse reactions to fillers, cutaneous lymphomas and pseudolymphomas.¹

HRU is a rapid, low-cost and safe technique. It can be used for diagnosis, follow-up, monitoring response to treatment and to guide interventional procedures in dermatology.⁴ Literature about ultrasonographic features of facial dermatoses is scarce. We have not found previous reports of ultrasonographic descriptions of GF. In our study facial and extrafacial granuloma faciale presented in most cases as a hypoechoic, heterogeneous and ill-defined lesion on dermis and hypodermis with increased vascularity on ultrasound examination. A marked subepidermal hypoechoic band was also found in almost all cases, and it may be secondary to cutaneous inflammation, to the presence of a Grenz zone on histopathology (a characteristic histopathologic feature of GF⁵) or to

photo-ageing, as most lesions were located on sun-exposed skin. Sonographic characteristics may allow to differentiate GF from subacute cutaneous lupus erythematosus as the latter shows thickening and hypoechogenicity of the dermis with a plateau shape, and increased echogenicity of the upper hypodermis with a “foggy appearance”,⁶ and from inflammatory complications of cosmetic fillers, where the patient is occasionally reluctant to admit the procedure, such as hyaluronic acid and pure silicone (anechoic pseudocysts), liquid silicone (snowstorm appearance), polymethylmethacrylate and calcium hydroxyapatite (hyperechoic dots and bands, respectively).⁷ Also, HRU may help to differentiate GF from primary cutaneous lymphomas (PCLs) occurring on the face such as primary cutaneous CD4⁺ small/medium T cell lymphoproliferative disorder, primary cutaneous anaplastic large cell lymphoma, primary cutaneous marginal zone lymphoma and primary cutaneous follicle center lymphoma, among others. In PCLs HRU reveals thickening of dermis with no evidence of necrosis, calcification or posterior acoustic shadowing. Papules of PCLs are seen as focal infiltrative lesions, whilst nodules are seen as pseudonodules and nodules (more frequently in B cell PCLs), and plaques, as hypoechoic, diffusely infiltrative lesions (more predominant in T cell PCLs). On colour Doppler mode, PCLs show hypervascularity, although initial focal infiltrative lesions may be avascular.⁸

Clinical and histopathological diagnosis of GF may be challenging. We believe that knowing the sonographic characteristics of GF may help in the diagnosis of this disease. Further studies describing ultrasonographic features of inflammatory dermatoses of the face are required.

Conflicts of interest

The authors have nothing to disclose.

References

- Ortonne N, Wechsler J, Bagot M, Grosshans E, Cribier B. Granuloma facial: a clinicopathologic study of 66 patients. *J Am Acad Dermatol.* 2005;53:1002–9.
- Echeverría-García B, Borbujo J, Alfageme F. The use of ultrasound imaging in dermatology. *Actas Dermosifiliogr.* 2014;105:887–90.
- Wortsman X, Alfageme F, Roustán G, Arias-Santiago S, Martorell A, Catalano O, et al. Proposal for an Assessment Training Program in Dermatologic Ultrasound by the DERMUS Group. *J Ultrasound Med Off J Am Inst Ultrasound Med.* 2016;35:2305–9.
- Wortsman X. Common Applications of Dermatologic Sonography. *J Ultrasound Med.* 2012;31:97–111.
- Abbas O, Mahalingam M. The grenz zone. *Am J Dermatopathol.* 2013;35:83–91.
- Wortsman X. *Atlas of Dermatologic Ultrasound.* Springer International Publishing; 2018.
- Wortsman X, Wortsman J. Sonographic outcomes of cosmetic procedures. *AJR Am J Roentgenol.* 2011;197:W910–918.
- Mandava A, Koppula V, Wortsman X, Catalano O, Alfageme F. The clinical value of imaging in primary cutaneous lymphomas: Role of high resolution ultrasound and PET-CT. *Br J Radiol.* 2019;92:20180904.

D. Morgado-Carrasco, P. Giavedoni*, J.M. Mascaró, P. Iranzo

Departamento de Dermatología, Hospital Clínic de Barcelona, Universidad de Barcelona, Barcelona, Spain

* Corresponding author.

E-mail address: giavedonip@gmail.com (P. Giavedoni).

<https://doi.org/10.1016/j.adengl.2021.02.002>
1578-2190/ © 2021 AEDV. Published by Elsevier España, S.L.U. This is an open access article under the CC BY-NC-ND license (<http://creativecommons.org/licenses/by-nc-nd/4.0/>).

The Reading Man Flap: An Alternative for Reconstructing Defects in Areas of Flexion and Extension[☆]



Colgajo del lector como alternativa reconstructiva en regiones sometidas a movimientos de flexoextensión

Dear Editor,

The so-called *reading man flap* was described by Mutaf et al.¹ in 2008 as a new technique for covering circular defects. It takes its name from the form of the defect with

the Z-plasties, which is reminiscent of the silhouette of someone reading (Fig. 1A). The technique is based on development of an asymmetric Z-plasty. It has been mainly used for reconstruction of facial defects. Given its most important characteristic is that it guarantees tension-free closure, we believe that it could be of great use for closure of defects at sites subject to flexion and tension movements.

Case History

A 102-year-old man, who was partially dependent for basic activities of daily living, but with complete mobility in his arms and who could eat without assistance, underwent a single surgical procedure in regimen of major outpatient surgery, under local anesthetic and sedation, for a circular squamous cell carcinoma in the radial dorsal region of the left wrist (Fig. 1B). The resulting defect measured 4 cm (Fig. 1C). A reading man flap was designed for reconstruction of the defect, which was sutured directly with silk 3/0 stitches (Fig. 1D). Daily dressing changes were done with chlorhexidine and soft bandaging, and the stitches were removed after 10 days. The patient was recommended not

[☆] Please cite this article as: Martínez de Espronceda Ezquerro Í, Azcona Rodríguez M, Sarriugarte Aldecoa-Otalora J, Iglesias Zamora ME. Colgajo del lector como alternativa reconstructiva en regiones sometidas a movimientos de flexoextensión. *Actas Dermosifiliogr.* 2021;112:563–565.