

CASE AND RESEARCH LETTERS

Mycobacterium marinum Infection in a Woman Taking Adalimumab[☆]



Infección por *Mycobacterium marinum* en una paciente en tratamiento con adalimumab

Dear Editor:

A 54-year-old woman who was being treated with subcutaneous adalimumab (40 mg/2 wk) for 1 year for rheumatoid arthritis was seen for a pruritic rash on her left hand. The rash had appeared 10 days earlier after she cut the third finger of the left hand while preparing fish in her workplace. The patient reported no previous contact with standing water (e.g. aquariums, ponds). Physical examination revealed multiple erythematous-violaceous papules of 3–4 mm on the dorsal aspect (Fig. 1) and palm of the left hand and on the wrist (Fig. 2). An erosion on the palmar aspect of the third finger of the same hand was identified by the patient as the initial injury (Fig. 2).

Biopsy revealed an epidermis with acanthosis and isolated apoptotic keratinocytes, band-like inflammatory infiltrate, and basal vacuolar damage. Well-defined granulomas consisting of histiocytes and lymphocytes were observed

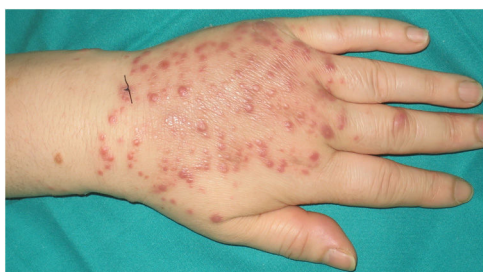

Figure 1 Multiple erythematous-violaceous papules of 3–4 mm on the back of the left hand.

in the reticular dermis and hypodermis (Fig. 3A). Giemsa, periodic acid-Schiff, and Grocott silver staining were negative for microorganisms. Fite-Faraco staining revealed the presence of acid-alcohol resistant bacilli (Fig. 3B).

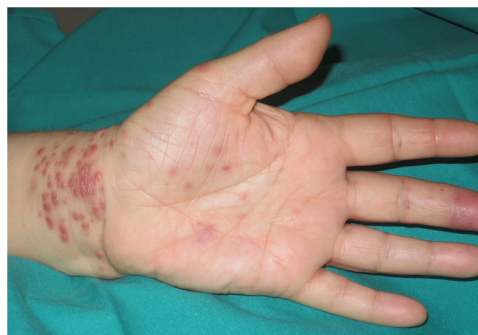

Figure 2 Similar lesions on the palm and wrist of the left hand, and an erosion on the palmar aspect of the third finger of the same hand.

Culture of the biopsy material in Löwenstein-Jensen medium resulted in positive growth after 20 days, and *Mycobacterium marinum* was subsequently isolated by matrix-assisted laser desorption/ionization time-of-flight mass spectrometry (MALDI-TOF MS), enabling definitive diagnosis. The patient was diagnosed with a localized skin infection caused by *M. marinum*, with a non-lymphocutaneous distribution. Antibiotic susceptibility testing showed that the microorganism was sensitive to kanamycin (high load), rifampin, ethambutol, ethionamide, cycloserine, and capreomycin, and was resistant to streptomycin, isoniazid, pyrazinamide, and paraaminosalicylic acid. The patient was initially prescribed minocycline (100 mg/12 h). After 2 months of treatment a marked improvement in the lesions was observed. However, because some active lesions persisted, antibiotic treatment was switched from minocycline to clarithromycin (500 mg/12 h). After another 2 months of treatment, the only remaining lesions were brownish macules, and antibiotic treatment was permanently discontinued. The patient experienced no subsequent recurrence after 6 months of follow-up.

Mycobacterial species other than those of the *Mycobacterium tuberculosis* complex and *Mycobacterium leprae* are known as nontuberculous mycobacteria. The incidence of infections caused by these mycobacteria is increasing dramatically, mainly due to the prevalence of AIDS and the use of immunosuppressive therapies.¹ The use of tumor necrosis factor inhibitors is associated with an increased risk of tuberculosis and of infection caused by nontuberculous mycobacteria.²

The infection caused by *M. marinum* is historically known as swimming pool or fish tank granuloma, owing to the wide distribution of this microorganism in aquatic environments,

[☆] Please cite this article as: Peña Merino L, Mendieta-Eckert M, Méndez Maestro I, Gardeazabal García J. Infección por *Mycobacterium marinum* en una paciente en tratamiento con adalimumab. Actas Dermosifiliogr. 2020;111:525–526.

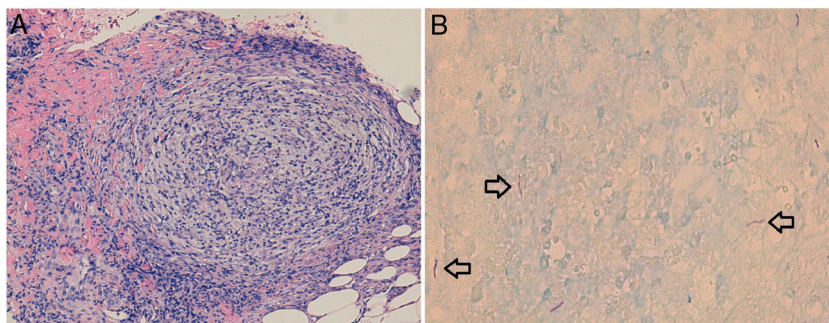


Figure 3 A, Hematoxylin-eosin staining shows well-defined granulomas, consisting of histiocytes and peripheral lymphocytes, located in the reticular dermis and hypodermis. B, Fite-Faraco staining reveals the presence of acid-alcohol resistant bacilli.

especially in stagnant water such as that found in fish ponds or swimming pools not treated with chlorine. The skin infection is acquired by contact with *M marinum*-contaminated water or with marine animals such as fish or crustaceans, and requires an entry site (usually minor skin trauma, which can be pre-existing or can coincide with exposure to the microorganism).

The most common clinical presentation is nodular (60% of cases), consisting of a single lesion at the inoculation site, usually affecting the upper extremities. Multiple nodular lesions occur in 35% of cases, and are generally arranged linearly following a lymphatic path from the point of inoculation, producing a classical sporotrichoid or lymphocutaneous pattern. Disseminated infections have also been described in several immunocompromised patients.^{3,4}

Diagnosis is confirmed by culture of biopsy material. *M marinum* colonies are normally detected after 10 to 28 days of incubation, although cultures should be monitored for at least 6 weeks.⁵ In one study, only a third of acid-fast-stained samples were positive.⁶

A reasonable therapeutic strategy is to prescribe 2 active agents for up to 1 or 2 months after resolution of clinical signs (usually 3 or 4 months in total). For most patients, clarithromycin and ethambutol tend to provide an optimal balance of efficacy and tolerance.⁷

A search of the literature reveals 7 other cases of *M marinum* infection in patients receiving treatment with adalimumab for different diseases: rheumatoid arthritis (2), psoriasis (2), Crohn's disease (1), psoriatic arthritis (1), and ankylosing spondylitis (1).⁸

In conclusion, we present a case of *M marinum* infection with an atypical clinical presentation. This case underscores the risk of infection by nontuberculous mycobacteria in patients being treated with TNF inhibitors, and the importance of suspecting these infections, especially in individuals with a compatible exposure history.

Conflicts of interest

The authors declare that they have no conflicts of interest.

References

1. Dodiuk-Gad R, Dyachenko P, Ziv M, Shani-Adir A, Oren Y, Mendelovici S, et al. Nontuberculous mycobacterial infections of the skin: a retrospective study of 25 cases. *J Am Acad Dermatol.* 2007;57:413–20.
2. Brode SK, Jamieson FB, Ng R, Campitelli MA, Kwong JC, Paterson JM, et al. Increased risk of mycobacterial infections associated with anti-rheumatic medications. *Thorax.* 2015;70:677–82.
3. García Acebes CR, Barchino Ortiz L, Aboín González S, Díaz Ley B, Ruiz Fernández P, Sánchez de Paz F. Infección por *Mycobacterium marinum*. Presentación de un nuevo caso y revisión de la literatura. *Actas Dermosifiliogr.* 2006;97:653–7.
4. Bartralot R, García-Patos V, Sitjas D, Rodríguez-Cano L, Mollet J, Martín-Casabona N, et al. Clinical patterns of cutaneous nontuberculous mycobacterial infections. *Br J Dermatol.* 2005;152:727–34.
5. Gluckman SJ. *Mycobacterium marinum*. *Clin Dermatol.* 1995;13:273–6.
6. Wu TS, Chiu CH, Yang CH, Leu HS, Huang CT, Chen YC, et al. Fish Tank Granuloma caused by *Mycobacterium marinum*. *PLoS One.* 2012;7:e41296.
7. Griffith DE, Aksamit T, Brown-Elliott BA, Catanzaro A, Daley C, Gordin F, et al. An official ATS/IDSA statement: diagnosis, treatment, and prevention of nontuberculous mycobacterial diseases. *Am J Respir Crit Care Med.* 2007;175:367–416.
8. Timoney I, Lynch M, Timoney L, Feeney E, Kirby B. *Mycobacterium marinum* infection contracted from seaweed wrap in a psoriasis patient undergoing treatment with adalimumab. *Dermatol Online J.* 2017;23, pii: 13030/qt7zx7m93c.

L. Peña Merino*, M. Mendieta-Eckert, I. Méndez Maestro, J. Gardeazabal García

Servicio de Dermatología, Hospital Universitario Cruces, Barakaldo, Vizcaya, Spain

* Corresponding author.

E-mail address: lander_merino@hotmail.com (L. Peña Merino).

<https://doi.org/10.1016/j.adengl.2018.11.026>

1578-2190/ © 2020 AEDV. Published by Elsevier España, S.L.U. This is an open access article under the CC BY-NC-ND license (<http://creativecommons.org/licenses/by-nc-nd/4.0/>).