

CASE FOR DIAGNOSIS

Blistering Lesions Involving the Palms[☆]



Lesiones ampollosas en las palmas

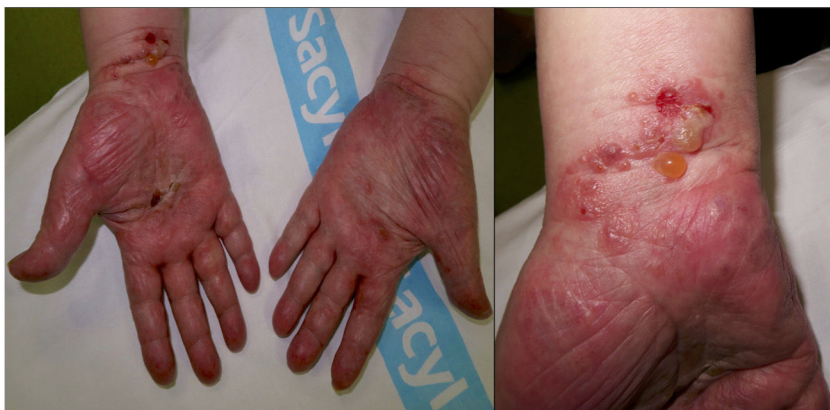

Figure 1

Case Description

An 88-year-old man with no history of interest came to the clinic with pruritus and vesicles on both hands that had first appeared 5 days earlier. He had not previously experienced insect bites or injury and had had no previous history of lesions of this type. Physical examination revealed the presence of multiple, tense vesicles that were round-oval in shape and contained a serous or serosanguineous fluid. They were scattered over the palms and wrists, although the thenar and hypothenar eminences were spared (Fig. 1). The vesicles were frequently on areas of erythematous-edematous skin. No similar lesions were found on other areas of the body or on the mucous membranes.

We therefore decided to order a biopsy. We obtained 2 skin fragments for study with hematoxylin-eosin staining and direct immunofluorescence. Examination of the biopsy specimen revealed an orthokeratotic epidermis with irregular acanthosis, marked exocytosis of eosinophils, and

spongiosis with spongiotic vesicles. The superficial and mid dermis revealed perivascular dermatitis comprising a mixed infiltrate that was mainly lymphocytic with abundant eosinophils (Fig. 2).

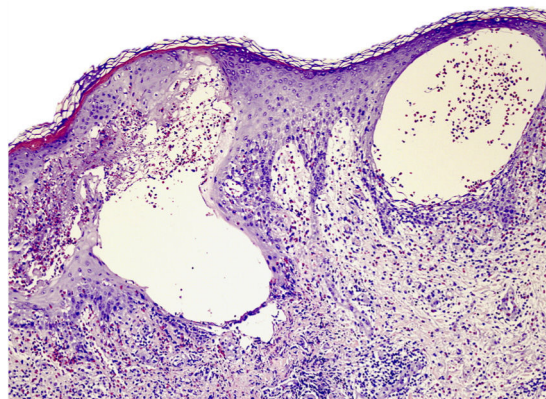


Figure 2 Hematoxylin-eosin, original magnification, $\times 20$.

[☆] Please cite this article as: Conde-Ferreirós A, Santos-Briz Terrón Á, Cañueto J. Lesiones ampollosas en las palmas. Actas Dermosifiliogr. 2020;111:321–322.

What is your diagnosis?

Diagnosis

Dyshidrosiform bullous pemphigoid (DBP).

Clinical Course and Comment

Direct immunofluorescence revealed the presence of linear deposits of immunoglobulin (Ig) G and complement component C3 (C3) in the basement membrane. The clinical and pathological findings enabled us to confirm a diagnosis of DBP. We initiated treatment with oral prednisone (0.5 mg/kg), together with topical zinc sulfate 1/1000 and clobetasol dipropionate cream, once per day. The lesions improved significantly after 5 days.

DBP is a rare variant of bullous pemphigoid that was first described in 1979 by Levine et al.¹ It most commonly affects elderly patients, and its etiology is unknown. DBP is characterized by tense blisters with clear and often hemorrhagic content, which are found initially or exclusively on the palms and soles. In some cases, the blisters develop after pruritic eczematous or urticarial lesions, whereas in others, the urticarial lesions persist without formation of blisters. Bullous pemphigoid is characterized by subepidermal blisters with abundant eosinophils in histopathology. However, intradermal spongiotic vesicles with eosinophils in the interior may also be present.² This phenomenon, which is known as eosinophilic spongiosis, is characterized by intercellular edema composed of an inflammatory eosinophilic infiltrate. It constitutes a reactive pattern in the epidermis that is observed in a wide range of skin conditions.³ According to Crotty et al.,³ this histopathological finding is very frequently associated with bullous pemphigoid. Nevertheless, additional histopathological criteria must be fulfilled before the diagnosis of bullous pemphigoid can be confirmed.

As with bullous pemphigoid, DBP is characterized by linear deposits of IgG and C3 in the basement membrane. The lesions frequently resolve with residual hyperpigmentation, although without scarring or milia.⁴ Treatment consists of topical or systemic corticosteroids according to the severity and/or extension of the process and the disease. The

disease can progress via 3 different pathways: (a) the bullous lesions remain confined to the palms and soles; (b) onset is in acral regions of the palms and soles, with subsequent extension to the rest of the skin; and (c) concomitant appearance of lesions on the palms and soles, together with generalized lesions.⁵ The patient in the present case is in complete remission, with no new vesicles on the palms or soles or on other areas. Residual hyperpigmentation persisted for several weeks.

Conflicts of Interest

The authors declare that they have no conflicts of interest.

References

1. Levine N, Freilich A, Barland P. Localized pemphigoid simulating dyshidrosiform dermatitis. *Arch Dermatol.* 1979;115:320–1.
2. Joshi R. Spongiotic intra-epidermal blister: a pitfall in the histopathologic diagnosis of bullous pemphigoid. *Indian J Dermatol.* 2013;58:410.
3. Crotty C, Pittelkow M, Muller SA. Eosinophilic spongiosis: a clinicopathologic review of seventy-one cases. *J Am Acad Dermatol.* 1983;8:337–43.
4. Behlim T, Sharma YK, Chaudhari ND, Dash K. Dyshidrosiform pemphigoid with Parkinsonism in a nonagenarian Maharashtrian female. *Indian Dermatol Online J.* 2014;5:482–4.
5. Caldarola G, Fania L, Cozzani E, Feliciani C, de Simone C. Dyshidrosiform pemphigoid: a well-defined clinical entity? *Eur J Dermatol.* 2011;21:112–3.

A. Conde-Ferreirós,^{a,*} Á. Santos-Briz Terrón,^b J. Cañueto^a

^a *Servicio de Dermatología Médico-Quirúrgica y Venereología, Hospital Clínico Universitario de Salamanca, Salamanca, Spain*

^b *Servicio de Anatomía Patológica, Hospital Clínico Universitario de Salamanca, Salamanca, Spain*

* Corresponding author.

E-mail address: alconfe25@yahoo.com (A. Conde-Ferreirós).