




# ACTAS Derma-Sifiliográficas

Full English text available at  
www.actasdermo.org



## CASE AND RESEARCH LETTERS

### Aggressive Inferior Eyelid Basal Cell Carcinoma: Advantage of Neoadjuvant Vismodegib [[es]]Carcinoma basocelular agresivo del párpado inferior: ventaja del vismodegib neoadyuvante<sup>☆</sup>



#### PALABRAS CLAVE

Carcinoma basocelular;  
Terapia neoadyuvante;  
Vismodegib

#### KEYWORDS

basal cell carcinoma;  
neoadjuvant therapy;  
vismodegib

#### To the Editor:

Basal cell carcinoma (BCC) is the most common skin cancer and represents 90% of malignant eyelid tumors.<sup>1</sup> Management options are mainly surgical, including Mohs micrographic surgery and wide surgical excision.<sup>1</sup> However, some of these lesions can progress to an advanced locally stage and represent a therapeutic challenge. In 2012 the US Food and Drug Administration (FDA) approved Vismodegib, an oral hedgehog pathway inhibitor, for the treatment of locally advanced and metastatic BCCs which are inappropriate for surgery or radiotherapy.<sup>2,3</sup> Herein, we report a patient with an infraorbital locally advanced BCC who was offered oral vismodegib before surgery reducing surgery-associated morbidity and allowing the preservation of functional and aesthetic aspect of the affected area.

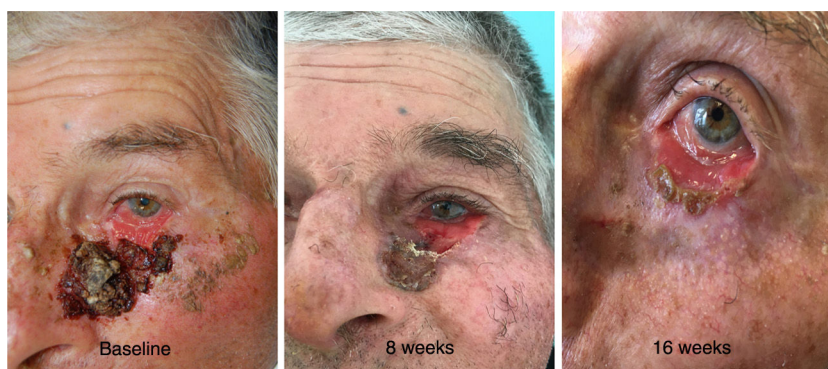
A 81-year-old man presented with a 6-year history of a progressively growing lesion in the left lower eyelid. Examination of the ocular adnexae showed an extensive, infiltrated and centrally erosive lesion, covered by a crust with 6 cm of major axis and involving all the left lower eyelid with ectropion and extending onto the left malar cheek (Fig. 1). Biopsy showed a ulcerated BCC and com-

puted tomography (CT) scan of the head did not identify alterations in the facial bones (left maxilla, inferior orbital rim, and base of the nasal bone). Due to the advanced nature of the lesion and involvement of more than two-thirds of the tarsal conjunctiva with a complex location for surgery and radiotherapy, the patient was offered oral vismodegib 150 mg PO daily in order to shrink the tumor before surgery and reduce surgery-associated morbidity.

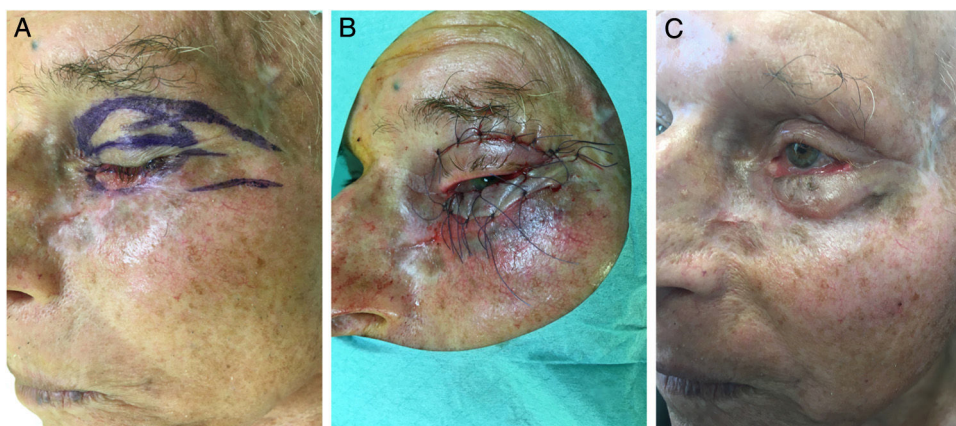
The reassessment was performed at 4, 8 and 16 weeks after initiation of oral therapy (Fig. 1). At 16 weeks the lesion showed a significant clinical improvement with substantial regression and a biopsy of the tarsal conjunctiva was performed. The histopathologic examination of the tarsal conjunctiva was compatible with “absence of neoplasia”. Vismodegib treatment was discontinued at 23 weeks and wide excision of the residual lesion with reconstruction was performed. The pre-surgical clinically visible lesion size was 2,5 × 0,8 cm and the final surgical defect measured 3,2 × 1,5 cm. For the reconstruction of the defect, it was suggested to perform a modified Tripiet flap (Fig. 2A). A single pedicle, randomized and lateral, was drawn with a relatively wide base (Fig. 2B). The surgical solution was consistent with a good functional result. Histological evaluation of the surgical specimen revealed “absence of neoplasia”. The follow-up 6 months after surgery revealed no recurrences and an excellent functional and aesthetic result (Fig. 2C). The patient tolerated vismodegib very well just reporting a slight muscles spasm, dysgeusia and alopecia of the eyebrows and eyelids. All the side effects were graded as 1 using the Common Terminology Criteria for Adverse Events (CTCAE). No severe adverse events were observed.

It is established that neoadjuvant treatment with vismodegib for an average of 4 months before surgery reduces tumor area and surgical defect size.<sup>4,5</sup> In literature, a clinical trial with short-term vismodegib showed a reduction of the surgical defect area by 31% if used for at least 3 months in non-recurrent BCCs of functionally sensitive locations.<sup>5</sup> Furthermore, previous studies revealed that the clinical appearance of tumors after vismodegib was variable and did not predict histologic cure.<sup>3,5</sup> This achievement enhances the importance of performing biopsies or diagnostic techniques such as confocal laser scanning microscopy in order to identify residual tumor nests. The margins performed in this case had the intention to excise the clinical residual lesion with 10 mm margin and the reconstruction of the inferior eyelid ectropion. Some studies support the idea that vismodegib “cure” is temporary, as BCCs recur at the same site within a few months of drug discontinuation.<sup>3,5</sup> We consider that probably the best surgical option after vismodegib would be micrographic Mohs surgery (MMS) as this surgical

<sup>☆</sup> Please cite this article as: Monteiro AF, Rato M, Trigo M, Martins C. Carcinoma basocelular agresivo del párpado inferior: ventaja del vismodegib neoadyuvante. Actas Dermosifiliográficas. 2019;110:863–865.



**Fig. 1** Clinical regression of left lower eyelid basal cell carcinoma during vismodegib therapy.



**Fig. 2** Intraoperative stages with excision of the residual suspected lesion in the lower eyelid and reconstruction with a modified Tripiier flap of the upper eyelid (A,B) and 6-month postoperative result (C).

technique allows to localize residual nests of BCC that can remain during the reduction of the tumor.<sup>6</sup>

In our clinical case, a modified Tripiier flap was performed as eyelid wound repair must be carefully designed so that eyelid function is maintained and the globe is protected. The original Tripiier flap is considered a myocutaneous bipedicular flap originating from the upper eyelid and recommended for the reconstruction of lower lateral eyelid defects.<sup>7</sup> Usually this technique is time-consuming and requires a second surgical stage for sectioning the lateral pedicles.<sup>8</sup> Its modification consists in planning a single pedicle, lateral, randomized in one-stage surgery which does not rely on the inclusion of orbicularis muscle or innervation. The surgical solution of our case demonstrates an option of the lower eyelid reconstruction, simple and versatile without ectropion or eyelid distortion.

This case highlights the potential of short-term vismodegib as neoadjuvant to surgery for high-risk locally advanced basal cell carcinomas, especially in functionally sensitive locations as the periocular and orbital areas.

### Conflicts of interest

Dr. César Martins is a member of the Roche Pharmaceuticals Advisory board. The other authors declare no conflicts of interest.

### Funding sources

None.

### References

- Gill HS, Moscato EE, Chang ALS, Soon S, Silkiss RZ. Vismodegib for periocular and orbital basal cell carcinoma. *JAMA Ophthalmol.* 2013;131:1591.
- Sekulic A, Migden MR, Oro AE, Dirix L, Lewis KD, Hainsworth JD, et al. Efficacy and safety of vismodegib in advanced basal-cell carcinoma. *N Engl J Med.* 2012;366:2171–9.
- Bichakjian CK, Olencki T, Aasi SZ, Alam M, Andersen JS, Berg D, et al. Basal cell skin cancer, Version 1.2016, NCCN clinical practice guidelines in oncology. *J Natl Compr Canc Netw.* 2016;14:574–97.
- Apalla Z, Papageorgiou C, Lallas A, Sotiriou E, Lazaridou E, Vakirlis E, et al. Spotlight on vismodegib in the treatment of basal cell carcinoma: an evidence-based review of its place in therapy. *Clin Cosmet Investig Dermatol.* 2017;10:171–7.
- Ally MS, Aasi S, Wysong A, Teng C, Anderson E, Bailey-Healy I, et al. An investigator-initiated open-label clinical trial of vismodegib as a neoadjuvant to surgery for high-risk basal cell carcinoma. *J Am Acad Dermatol.* 2014;71:904–11, e1.
- Alcalay J, Tauber G, Fenig E, Hodak E. Vismodegib as a neoadjuvant treatment to Mohs surgery for aggressive basal cell carcinoma. *J Drugs Dermatol.* 2015;14:219–23.
- Bickle K, Bennet RG. Tripiier flap for medial lower eyelid reconstruction. *Dermatologic Surg.* 2008;34:1545–8.
- Machado WLG, Gurfinkel PC de M, Gualberto GV, Sampaio FMS, Melo MLC, Treu CM. Modified tripiier flap in reconstruction of the lower eyelid. *An Bras Dermatol.* 2015;90:108–10.

Ana Filipe Monteiro,<sup>a,\*</sup> Margarida Rato,<sup>a</sup> Miguel Trigo,<sup>b</sup> César Martins<sup>a</sup>

<sup>a</sup> *Dermatology Department, Hospital de Santarém EPE, Santarém, Portugal, Avenida Bernardo Santarém, 2005-177 Santarém, Portugal*

<sup>b</sup> *Plastic Surgery Department, Centro Hospitalar de Lisboa Ocidental EPE, Estrada do Forte do Alto do Duque, 1449-005 Lisboa, Portugal*

\*Corresponding author.

E-mail addresses: [anafilipemonteiro@gmail.com](mailto:anafilipemonteiro@gmail.com) (A.F. Monteiro), [margaridagaiorato@gmail.com](mailto:margaridagaiorato@gmail.com) (M. Rato), [trigo75@live.com.pt](mailto:trigo75@live.com.pt) (M. Trigo), [wmed.medicos@sapo.pt](mailto:wmed.medicos@sapo.pt) (C. Martins).

8 January 2018 23 May 2018

<https://doi.org/10.1016/j.adengl.2018.05.039>  
1578-2190/

© 2019 Elsevier España, S.L.U. and AEDV. Published by Elsevier España, S.L.U. All rights reserved.

## Rheumatoid Nodulosis in an Adult Patient Negative for Rheumatoid Factor<sup>☆</sup>



### Nodulosis reumatoideos en una paciente adulta con factor reumatoide negativo

To the Editor

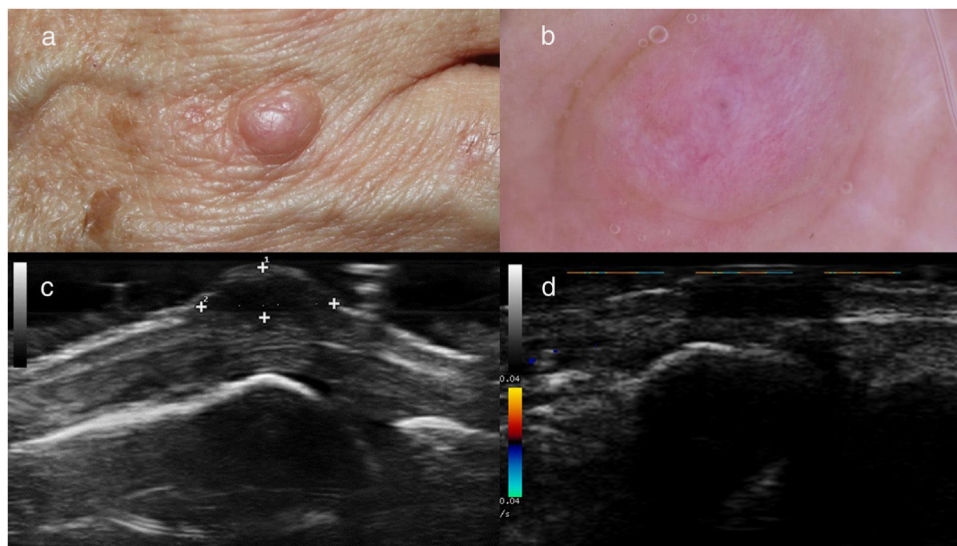
A 56-year-old woman was seen for asymptomatic nodules that had appeared several months earlier and were located on the elbows and the backs of the hands at the metacarpophalangeal joints. She reported no local or systemic symptoms apart from mild, periodic, nondisabling pain of the finger joints that did not require regular use of medication. Physical examination revealed painless, skin-colored or slightly erythematous subcutaneous nodules that were attached to deep planes (Fig. 1A). The lesions did not compromise joint function. Dermoscopy findings were nonspecific, and included a lesion with a flesh-colored background and white, mainly crystalline structures, as well as poorly focused irregular vascular structures (Fig. 1B).

Ultrasound revealed a well defined nodule with hypoechoic content and no power Doppler activity that was in contact with the extensor tendon of the fourth finger (Fig. 1C and D). In laboratory tests C-reactive protein levels and the erythrocyte sedimentation rate were consistently within the normal range in successive analyses. Rheumatoid factor and anti-cyclic citrullinated peptide (anti-CCP) antibody were negative. An X-ray of the hands revealed no joint alterations. The X-ray was evaluated by staff at the rheumatology department of our hospital, who found that no criteria for any specific arthropathy were fulfilled.

An excisional biopsy of one of the nodules on the hands showed granulomas with an eosinophilic center surrounded by palisaded histiocytes, with absence of mucin (Fig. 2A and B). The histological diagnosis was compatible with a rheumatoid nodule. Because the patient did not meet the criteria for rheumatoid arthritis, a diagnosis of rheumatoid nodulosis has been established after more than 5 years of follow-up.

### Discussion

Rheumatoid nodulosis is characterized by the presence of histologically confirmed rheumatoid nodules with absent or



**Figure 1** A, Skin-colored nodule located on the back of the hand at the metacarpophalangeal joint. B, Dermoscopic image of the lesion shown in A, showing a skin-colored background and nonspecific crystalline structures, as well as poorly focused irregular vascular structures. C, Ultrasound image of the lesion shown in A, showing a well-defined hypoechoic nodule located deep in the dermis. D, Ultrasound image of the lesion showing no power Doppler activity.

<sup>☆</sup> Please cite this article as: Álvarez-Chinchilla PJ, Poveda Montoyo I, Illán F, Bañuls Roca J. Nodulosis reumatoideos en una paciente adulta con factor reumatoide negativo. *Actas Dermosifiliogr.* 2019;110:865–867.