

E-IMAGES IN DERMATOLOGY

Carcinoma en Cuirasse[☆]

Carcinoma en coraza

V. Flores-Climente,* E. Rozas-Muñoz, L. Puig



Servicio de Dermatología, Hospital de la Santa Creu i Sant Pau, Barcelona, España

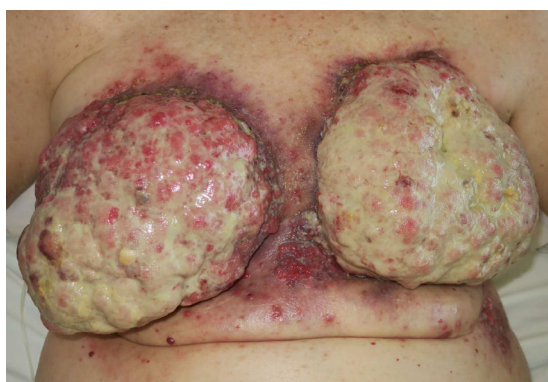

Figure 1

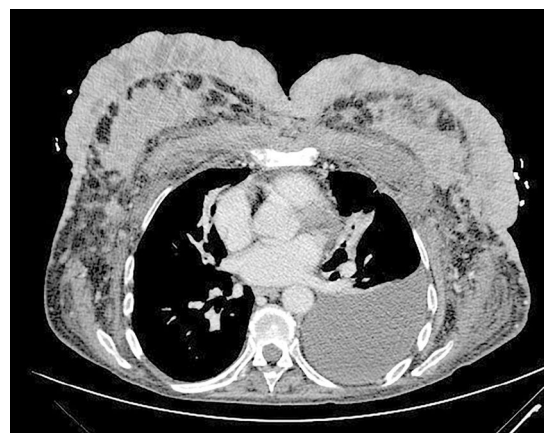


Figure 2

A 64-year old woman presented with extensive and painful lesions in both breasts that developed over the last 3 months. Physical examination revealed multiple fleshy, exophytic, malodorous and ulcerated masses involving the entire surface of both breasts. Erythematous and ulcerated plaques were also seen surrounding the lesions. [Figure 1]. Her past medical history was remarkable for in situ adenocarcinoma of her left breast treated with wide surgical excision and radiotherapy twenty years ago.

Histopathological examination showed diffuse cutaneous infiltration of high-grade adenocarcinoma of the breast. Tumor cells were negative for hormonal and HER2/neu receptors. Computed tomography revealed involvement of thorax muscles with left pleural effusion and enlargement of the mediastinal lymph nodes [Figure 2]. Two liver nodules were also observed. With the diagnosis of stage IV breast adenocarcinoma, chemotherapy with paclitaxel was initiated with only partial improvement.

Carcinoma en cuirasse was first described by Velpeau in 1838; this name was chosen because of its resemblance to the steel breastplate of a cuirassier. This form is a very uncommon clinicopathological presentation of cutaneous metastasis of breast carcinoma with poor prognosis that usually appears as a tumoral recurrence after a mastectomy.

[☆] Please cite this article as: Flores-Climente V, Rozas-Muñoz E, Puig L. Carcinoma en coraza Eczema y urticaria en Portugal. 2019;110:e2.

* Corresponding author.

E-mail address: vflores@santpau.cat (V. Flores-Climente).