

5. Finlay AY, Khan GK. Dermatology Life Quality Index (DLQI): A simple practical measure for routine clinical use. *Clin Exp Dermatol*. 1994;19:210–6.

P. Martín-Carrasco,* M. Morillo-Andújar, M. Sendín-Martín, J. Conejo-Mir

Unidad de Gestión Clínica de Dermatología, Hospital Universitario Virgen del Rocío, Sevilla, España

*Corresponding author.

E-mail address: pablo_ronda@hotmail.com
(P. Martín-Carrasco).

19 November 2017 11 February 2018
1578-2190/

© 2018 Elsevier España, S.L.U. and AEDV. Published by Elsevier España, S.L.U. All rights reserved.

Clinical and Ultrasound Image of a Cutaneous Fibrolipomatous Hamartoma[☆]



Imagen clínica y ecográfica de un hamartoma fibrolipomatoso cutáneo

To the Editor:

Cutaneous fibrolipomatous hamartoma (CFH) is characterized by the presence of lobules of mature adipose tissue surrounded by fibrous septa in the mid-to-deep dermis. In the literature, this entity has several different names, although the most widely used is precalcaneal congenital fibrolipomatous hamartoma.¹

Clinically, the condition presents as a soft, flesh-colored, asymptomatic, solitary mass. It is generally bilateral and symmetrical and located on the inner part of the plantar aspect of the heel, or precalcaneal region. Cases of unilateral involvement have been reported,^{2,3} and, although this is a congenital lesion, it is sometimes first noticed years after birth.³ Most cases are sporadic, although the possibility of autosomal dominant or X-linked inheritance has been postulated.^{1,3,4}

The diagnosis is mainly clinical. However, in doubtful cases, such as unilateral involvement or uncharacteristic sites, biopsy is usually the approach taken. The differential diagnosis is with infantile hemangioma, congenital hemangioma, vascular malformations, lipoma, and neurofibroma. Skin imaging with high-frequency ultrasound can facilitate the differential diagnosis and confirm the clinical suspicion, thus obviating the need for invasive diagnostic tests.

Case Description

We present a clinical and ultrasound image of CFH in a 5-month-old girl with no personal history of interest. Clinically, the image shows an asymptomatic flesh-colored mass that was soft in consistency. The lesion had been present since birth and had grown in proportion with the patient. No similar change was observed on the contralateral foot (Fig. 1).

The patient was an only child, and the parents did not have similar abnormalities.

The ultrasound image confirmed the clinical suspicion and made it possible to rule out differential diagnoses (Fig. 2). We did not observe any masses or tumors or clusters of anechoic channels with or without internal flow. The lacunae did not disappear on compression of the skin by the transducer. Doppler mode did not reveal a signal in the interior or periphery of the lesion.

The parents were informed that the lesion was benign and did not require treatment. The lesion was to be reviewed only in the case of changes or onset of symptoms.

Discussion

Skin imaging with high-frequency ultrasound is increasingly used in childhood dermatologic diseases. The differential diagnosis of tumors is one of its main applications. Unlike tumors, hamartomas appear as thickening of the dermis and/or subcutaneous cellular tissue and not as masses. The echogenicity of a hamartoma depends on the most abundant element. In the case of CFH, the reticular dermis thickens owing to the presence of islands of fatty tissue between collagen fibers that can extend to the hypodermis. Ultrasound reveals hypoechoic islands surrounded by hyperechoic bundles in the deep dermis and in the subcutaneous cellular tissue. The literature contains few references to ultrasound assessment of CFH. Cambiaghi et al.⁵ present a series of 3 cases and report on the usefulness of ultrasound in the differential diagnosis, although they do not describe or present their imaging findings. Grilo et al.⁶ describe CFH as a poorly

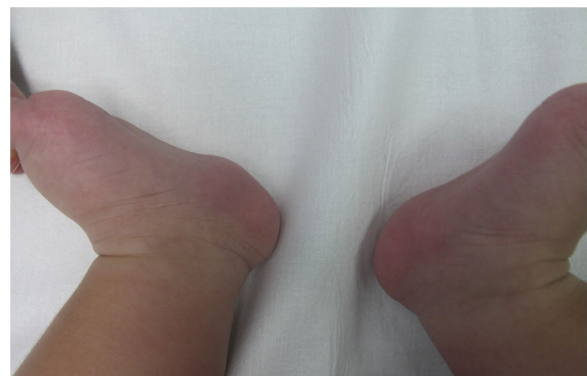

Figure 1 Clinical image of a fibrolipomatous hamartoma in a 5-month-old girl. The image shows a flesh-colored tumor with a soft consistency on the precalcaneal region of the left heel.

[☆] Please cite this article as: Rodríguez-Bandera AI, Feito-Rodríguez M, de Lucas-Laguna R. Imagen clínica y ecográfica de un hamartoma fibrolipomatoso cutáneo. 2019;110:513–515.

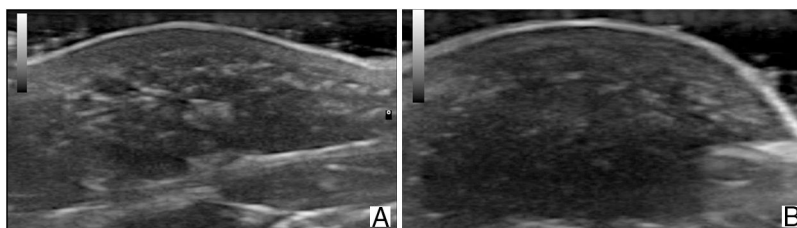


Figure 2 Ultrasound image (18 MHz) of fibrolipomatous hamartoma. A, Longitudinal plane (A). B, Transversal plane (B). Note the thickening of the dermis and hypodermis at the expense of hypoechoic islands with fatty echogenicity intermingled between hyperechoic lines in the deep dermis, which extend to the subcutaneous cellular tissue.

Table 1 Ultrasound of Cutaneous Fibrolipomatous Hamartoma and of Entities Included in the Differential Diagnosis.

Entity	Margins	Echogenicity	Distinctive Finding	Doppler
Cutaneous fibrolipomatous hamartoma	Poorly defined	Heterogeneous, mainly hypoechoic	Hypoechoic lacunae separated by hyperechoic bundles running in different directions	–
Lipoma	Well defined	Isoechoic or hyperechoic	Hyperechoic lines that are parallel to each other and to the skin surface	–
Neurofibroma	Variable	Variable	Lateral prolongations	+ / –
Infantile hemangioma	Poorly defined	Variable, depending on the course of the lesion	Proliferative phase: increased vessel density. Mixed vascularization with arterial and venous flow and arteriovenous shunts Involution phase: reduced vessel density ¹¹	+++
Congenital hemangioma	Poorly defined	Heterogeneous	Increased vessel density. Enlarged veins Calcifications ¹²	+++
Vascular malformation	Poorly defined	Heterogeneous, mainly hypoechoic	Compressible anechoic lacunae Phleboliths in venous malformation	+ / –

defined, homogeneous, slightly hyperechoic lesion adjacent to the subcutaneous cellular tissue; however, their report does not show the ultrasound image. Our search of the literature revealed only 4 ultrasound images, and, despite differences in the descriptions, each of the 4 images shows findings similar to those we report.^{2,7-9} It seems reasonable to think that the more or less hypoechoic appearance of the lesion depends on the amount of adipose tissue in the hamartoma.

Fibrolipomatous hamartoma affecting a nerve is located at a deeper level and is observed as hypoechoic thickening of the nerve on ultrasound,¹⁰ since both fibrous and adipose tissue present higher echogenicity than the nerve.

Given that CFH is not accompanied by increased blood flow, color Doppler can facilitate the differential diagnosis with vascular lesions such as infantile hemangioma, congenital hemangioma, or specific vascular malformations. Other lesions that can be confused with CFH can be ruled out using ultrasound (Table 1).

This case of unilateral precalcaneal CFH illustrates the usefulness of ultrasound in the differential diagnosis of this lesion. Therefore, we believe that high-frequency

ultrasound is a useful technique for confirming a clinical suspicion of CFH and can obviate the need for biopsy at a site that is particularly painful and where scarring can cause chronic discomfort. Furthermore, ultrasound enables us to reassure parents by showing and explaining the lesion to them.

Conflicts of Interest

The authors declare that they have no conflicts of interest.

References

1. Espana A, Pujol RM, Idoate MA, Vazquez-Doval J, Romani J. Bilateral congenital adipose plantar nodules. *Br J Dermatol.* 2000;142:1262–4.
2. Yang JH, Park OJ, Kim JE, Won CH, Chang SE, Lee MW, et al. Precalcaneal congenital fibrolipomatous hamartoma. *Ann Dermatol.* 2011;23:92–4.
3. Garcia-Mata S, Hidalgo-Ovejero A. Anteromedial plantar nodules of the heel in childhood: A variant of the normality? *J Pediatr Orthop B.* 2010;19:108–13.

4. Meyer P, Soennichsen K, Buchenau W. Autosomal dominant precalcaneal congenital fibrolipomatous hamartoma. *Pediatr Dermatol.* 2005;22:355–6.
5. Cambiaghi S, Galloni C, Restano L, Cavalli R. Precalcaneal congenital fibrolipomatous hamartoma. *Int J Dermatol.* 2006;45:1202–3.
6. Grilo E, Nascimento J, Estanqueiro P, Salgado M. Symmetric asymptomatic plantar nodules in an infant. *J Pediatr.* 2016;172:219.
7. Semadeni BL, Mainetti C, Itin P, Lautenschlager S. Precalcaneal congenital fibrolipomatous hamartomas: Report of 3 additional cases and discussion of the differential diagnosis. *Dermatology.* 2009;218:260–4.
8. Choudhary AK, Adapa P. Precalcaneal congenital soft-tissue lesions in children: A case report of fibrous hamartoma of infancy and an approach to differential diagnosis. *Radiol Case Rep.* 2010;5:373.
9. Rodríguez Bandera AI, Saylor DK, Beato-Merino MJ, North J, Frieden IJ. Cutaneous fibrolipomatous hamartoma: report of two cases with retrocalcaneal location. *Pediatric Dermatol.* 2018;35:498–501.
10. Whittle C, Schonstedt V, Schiappacasse G. Fibrolipomatous hamartoma and its ultrasound diagnosis: Case series and review of the literature. *Ultrasound Q.* 2014;30:282–6.
11. Wortsman X, Wortsman J, Aranibar AC. Congenital diseases of the skin. In: Wortsman X, Jemec GBE, editors. *Dermatologic ultrasound with clinical and histologic correlations.* New York: Springer; 2013. p. 39–72.
12. Gorincour G, Kokta V, Rypens F, Garel L, Powell J, Dubois J. Imaging characteristics of two subtypes of congenital hemangiomas: Rapidly involuting congenital hemangiomas and non-involuting congenital hemangiomas. *Pediatr Radiol.* 2005;35:1178–85.

A.I. Rodríguez-Bandera,* M. Feito-Rodríguez,
R. de Lucas-Laguna

*Servicio de Dermatología, Hospital Universitario La Paz,
Madrid, Spain*

*Corresponding author.

E-mail address: anarb85@gmail.com

(A.I. Rodríguez-Bandera).

1578-2190/

© 2018 Elsevier España, S.L.U. and AEDV. Published by Elsevier España, S.L.U. All rights reserved.