

Acknowledgments

The authors would like to thank Dr Ana Cristina Ruiz and Dr Natalia Olaya for their contributions to the case.

References

- Bakar Ö, Seçkin D, Demirkesen C, Baykal C, Büyükbabani N. Two clinically unusual cases of folliculotropic mycosis fungoides: One with and the other without syringotriposism. *Ann Dermatol.* 2014;26:385–91.
- Willemsze R, Jaffe ES, Burg G, Cerroni L, Berti E, Swerdlow SH, et al. WHO-EORTC classification for cutaneous lymphomas. *Blood.* 2005;105:3768–85.
- Marschalckó M, Erős N, Kontár O, Hídvégi B, Telek J, Hársing J, et al. Folliculotropic mycosis fungoides: Clinicopathological analysis of 17 patients. *J Eur Acad Dermatol Venereol.* 2015;29:964–72.
- Mantika P, Helsing P, Gjersvik P, Bassarova A, Clausen O, Delabie J. Clinical and histopathological features of folliculotropic mycosis fungoides: A Norwegian patient series. *Acta Derm Venereol.* 2013;93:325–9.
- Brown DN, Wfieser I, Wang C, Dabaja BS, Duvic M. Leontine facies (LF) and mycosis fungoides (MF): A single-center study and systematic review of the literature. *J Am Acad Dermatol.* 2015;73:976–86.
- Ishibashi M, Ohshima K, Chen KR. Folliculotropic mycosis fungoides with eosinophilia and CD30⁺ large-cell transformation: A case with a fatal outcome presenting with multifocal lesions and leontine facies. *Clin Exp Dermatol.* 2010;35:33–136.
- van Santen S, Roach REJ, van Doorn R, Horváth B, Bruijn MS, Sanders CJG, et al. Clinical staging and prognostic factors in folliculotropic mycosis fungoides. *JAMA Dermatol.* 2016;152:992–1000.
- Sandberg Y, Heule F, Lam K, Lugtenburg PJ, Wolvers-Tettero ILM, van Dongen JMM, et al. Molecular immunoglobulin/T-cell receptor clonality analysis in cutaneous lymphoproliferations. Experience with the BIOMED-2 standardized polymerase chain reaction protocol. *Haematologica.* 2003;88:659–70.
- Villamizar-Rivera N, Olaya N. Determinación de la clonalidad en tejidos humanos. *latreia.* 2015;28:269–82.
- Uribe-Bojanini, ^{a,*} C. Santa-Vélez, ^{a,b} X. Rueda-Cadena, ^b S.D. Morales^b
^a *Universidad CES, Medellín, Colombia*
^b *Instituto Nacional de Cancerología, Bogotá, Colombia*

*Corresponding author.

E-mail address: uribe-esteban@uces.edu.co (E. Uribe-Bojanini).

1578-2190/

© 2018 Elsevier España, S.L.U. and AEDV. Published by Elsevier España, S.L.U. All rights reserved.

Spontaneous Regression of Medium-Sized Congenital Melanocytic Nevus: Report of 3 New Cases[☆]



Regresión espontánea de tres nevus melanocíticos congénitos medianos

To the Editor:

Congenital melanocytic nevi (CMN) are genetically determined benign proliferations of cells that arise from the neural crest and which are present from birth or the first weeks of life.^{1–3} They may remain unchanged or present a dynamic course.^{1,3} Regression is a rare process that causes progressive loss of pigment and may occur in different ways.^{1–5} It is frequently associated with the formation of distant achromic lesions.^{2,4}

Case 1

An 8-year-old boy was examined for changes in CMN lesions, which had appeared on his left leg 3 years earlier. These

changes began with a halo and subsequent disappearance of pigment on the surface and of the hair covering the lesion. At the same time, the patient developed distant achromic lesions (in the region of the right iliac fossa and in the occipital region of the scalp) (Fig. 1A–C). Topical treatment was instated with mometasone furoate for 3 weeks, followed by tacrolimus 0.1% ointment, and repigmentation was achieved by sectors of both the nevus (Fig. 1D) and the distant achromic lesions, though without changes to the poliosis.

Case 2

A 5-year-old girl was examined due to changes in CMN lesions, which had appeared a month earlier. Physical examination revealed a brown lesion measuring 9 × 5 cm; the lesion was brown with a whitish central area, a corrugated surface, and a fibrous appearance, and had white hairs on the surface (Fig. 2A). At the same time, an achromic macule appeared on the upper left eyelid. Treatment was instated with tacrolimus 0.03% ointment for both lesions. The patient did not return.

Case 3

A 5-year-old girl was examined due to progressive depigmentation of her CMN lesions; this process had begun with a halo and gradual reduction of the pigment on the surface of the halo. At the same time, the patient developed achromic lesions on the upper eyelids. In the following years, she

[☆] Please cite this article as: Alperovich R, Fiandrino MJ, Asial R, Boente MC. Spontaneous Regression of Medium-Sized Congenital Melanocytic Nevus: Report of 3 New Cases. *Actas Dermosifilogr.* 2019;110:414–416.

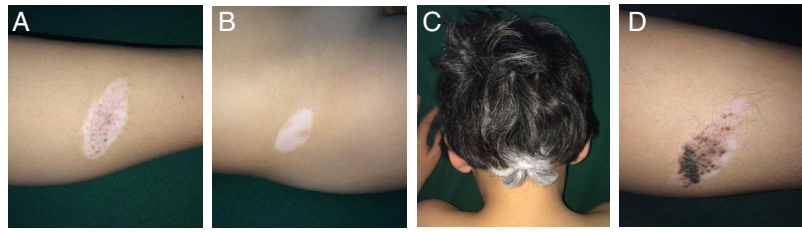


Figure 1 A, CMN showing loss of pigment and persistence of pigment in the central area. B, Achromic macule in the right iliac fossa. C, Occipital poliosis. D, Areas of repigmentation of the CMN 4 months after treatment. gr1.

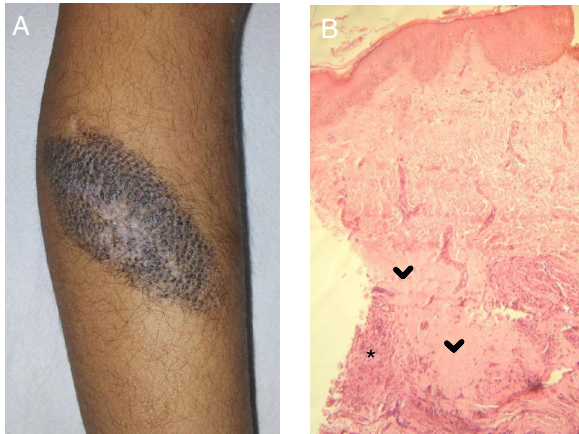


Figure 2 A, CMN with blackish-brown coloring and a whitish central area with a fibrotic appearance. Note the white hairs in this area. B, Histology: areas of collagen homogeneity (>) in the deep dermis, involving adnexa, surrounded by nevus cells and an inflammatory infiltrate (*). gr2.

developed areas of fibrosis and follicular atrophy inside the CMN lesions. Treatment with pimecrolimus 1% was instated for the distant achromic lesions and no repigmentation was observed (Fig. 3A-C).

In all of the patients, histology revealed nevus cells and a predominantly lymphocytic inflammatory infiltrate in the

deep dermis. Replacement of the nevus cells with fibrous tissue was observed in Cases 2 and 3 (Fig. 2B).

In all 3 cases, dermatoscopy revealed perifollicular hyperpigmentation, a blue-gray pigment associated with the deep component, globules, and pink areas without structures.

Discussion

CMN are classified by size into small (less than 1.5 cm), medium (1.5 to 10 cm), large (10 to 20 cm), and giant (greater than 20 cm). They may be located on any part of the skin surface and may appear in isolation or as part of more complex syndromes.^{1,3}

Torrelo et al.⁶ suggest that nevi reflect mosaicisms and show that they follow certain skin patterns and phenotypic characteristics. Postzygotic mutations of the H-Ras gene have also been shown in these nevi.^{3,6,7}

The course of CMN is variable and they may remain stable throughout life, increase in size, change color and thickness, become more hairy, become malignant, and even regress.^{1,3,4} To date, multiple forms have been reported in which these nevi show signs of regression.^{1,2,4,5} The most frequent form starts with a halo phenomenon that spontaneously regresses from the periphery to the center. Another more frequent form lacks this halo phenomenon.⁶ In exceptional cases, regression occurs by means fibrosis of the lesions.⁵

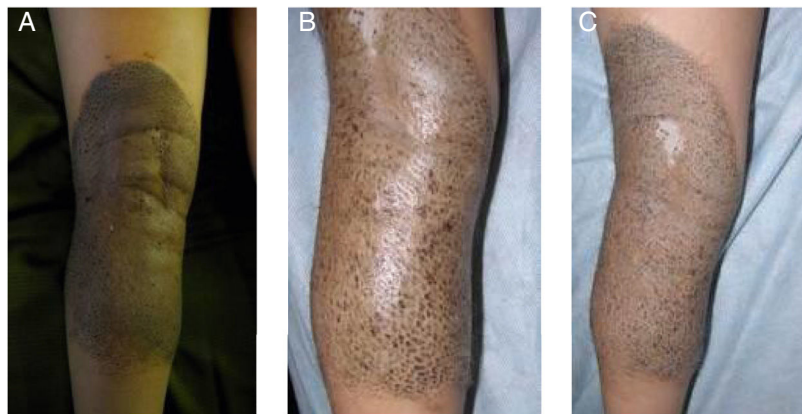


Figure 3 A, Medium CMN with small areas of regression. B, Follow-Up: note the progressive loss of pigmentation to follicular predominance. C, Detail of follicular atrophy. Note the unpigmented hairs. gr3.

The halo phenomenon is an area of depigmentation that may occur around CMN and other entities.² It affects 1% of the general population and incidence is higher in patients with pediatric vitiligo.^{2,8} There are many theories regarding its pathophysiology, including cellular and/or humoral immune responses to nevus cells or melanocytic nevi, which may present associated antigens or nonspecific abnormalities, even leading to cross-reactivity with distant melanocytes.⁸ The latter would explain the appearance of distant achromic lesions. Drakensjö et al.¹ believed that nevus cells remained in the dermis despite the regression.

Both vitiligo and the halo phenomenon share immunologic mechanisms and it has been shown that, when both are present, they are associated with some subtypes of the human leukocyte antigen HLA complex.^{4,8}

Regression of CMN without the halo phenomenon is very rare and alternative regression mechanisms have been proposed, such as reduced melanin synthesis and/or nevus cell apoptosis. In Case 2, the CMN regressed without a prior halo phenomenon but with distant achromic lesions.

Regression by means of fibrosis has been reported very rarely and the underlying mechanism is unknown. One variant of this form of regression by fibrosis, described by Ruiz-Maldonado et al.,⁹ is desmoplastic nevus. In that case, the authors proposed the immune system as a trigger.^{9,10} Histology shows replacement of nevus cells with connective tissue, and the most salient clinical finding is induration of the lesion. The principal differential diagnosis is malignant transformation and clinical and histologic follow-up is therefore essential.^{9,10}

The immune response to neoplastic cells would act concomitantly against the melanocytic nevus cells. Although an association has been described between the halo phenomenon and melanoma, it is rarely associated with CMN.⁵

We believe that these clinical cases are of interest as they provide examples of the different forms of regression. Knowledge of this process will make it possible to anticipate the potential development of vitiligo and follow-up with therefore allow for deary diagnosis and treatment. Case 2 is notable, as regression occurred without a prior halo phenomenon, despite the appearance of distant achromic lesions, suggesting that the immune system played an important role in the process.

Conflicts of Interest

The authors declare that they have no conflicts of interest.

References

1. Drakensjö IT, Hedblad MA, Wahlgren CF. Rapidly involuting congenital melanocytic naevi in two children. *Acta Derm Venereol.* 2012;92:605–6.
2. Stierman SC, Tierney EP, Shwayder TA. Halo congenital nevocellular nevi associated with extralesional vitiligo: a case series with review of the literature. *Pediatr Dermatol.* 2009;26:414–24.
3. Boente MC. Congenital melanocytic nevi. In: Silverberg NB, McKinstler CD, Tay YK, editors. *Pediatric skin of color.* New York: Springer Science+Business Media; 2015. p. 249–60.
4. Polat Ekinci A, Kiliç S, Baykal C. Pigment loss in patients with large congenital melanocytic nevi: various clinical presentations documented in a large series. *Pediatr Dermatol.* 2016;33:307–10.
5. Wong EK, Mahmood MN, Salopek TG. Spontaneous regression of a congenital melanocytic nevus by sclerosis. *Pediatr Dermatol.* 2016;33:368–71.
6. Torrelo A, Baselga E, Nagore E, Zambrano A, Happle R. Delineation of the various shapes and patterns of nevi varius. *Eur J Dermatol.* 2005;15:439–50.
7. Kinsler VA, Thomas AC, Ishida M, Bulstrode NW, Loughlin S, Hing S, et al. Multiple congenital melanocytic nevi and neurocutaneous melanosis are caused by postzygotic mutations in codon 61 of NRAS. *J Invest Dermatol.* 2013;133:2229–36.
8. Cohen BE, Mu EW, Orlow SJ. Comparison of childhood vitiligo presenting with or without associated halo nevi. *Pediatr Dermatol.* 2016;33:44–8.
9. Ruiz Maldonado R, Orozco-Covarrubias L, Ridaura-Sanz C, Duran-McKinster C, del Mar Saez de Ocariz Gutierrez M, Tamayo-Sánchez L. Desmoplastic hairless hypopigmented naevus: a variant of giant congenital melanocytic naevus. *Br J Dermatol.* 2003;148:1253–7.
10. Boente MC, Asial RA. Desmoplastic hairless hypopigmented nevus (DHHN). A distinct variant of giant melanocytic nevus. *Eur J Dermatol.* 2005;15:1–3.

R. Alperovich,^{a,*} M.J. Fiandrino,^a R. Asial,^b M.C. Boente^b

^a *Dermatología, Hospital del Niño Jesús, Tucumán, Argentina*

^b *Centro Integral de Dermatología, Tucumán, Argentina*

* Corresponding author.

E-mail address: ruthalperovich@hotmail.com (R. Alperovich).

24 October 2017 24 March 2018

1578-2190/

© 2018 Elsevier España, S.L.U. and AEDV. Published by Elsevier España, S.L.U. All rights reserved.