

- Leishmania* en el Viejo Mundo: una localización excepcional. *Actas Dermo-Sifiliogr.* 2014;105:628–30.
7. Calvopina M, Gomez EA, Uezato H, Kato H, Nonaka S, Hashiguchi Y. Atypical clinical variants in New World cutaneous leishmaniasis: disseminated erysipeloid, and recidiva cutis due to *Leishmania* (V.) *panamensis*. *Am J Trop Med Hyg.* 2005;73:281–4.
  8. Ceyhan AM, Yildirim M, Basak PY, Akkaya VB, Erturan I. A case of erysipeloid cutaneous leishmaniasis: atypical and unusual clinical variant. *Am J Trop Med Hyg.* 2008;78:406–8.
  9. Aronson N, Herwaldt BL, Libman M, Pearson R, Lopez-Velez R, Weina P, et al. Diagnosis and treatment of leishmaniasis: clinical practice guidelines by the Infectious Diseases Society of America (IDSA) and the American Society of Tropical Medicine and Hygiene (ASTMH). *Am J Trop Med Hyg.* 2017;96:24–45.
  10. Handler MZ, Patel PA, Kapila R, Al-Qubati Y, Schwartz RA. Cutaneous and mucocutaneous leishmaniasis: differential diagnosis, diagnosis, histopathology, and management. *J Am Acad Dermatol.* 2015;73:911–26.

E. Rojas Mora,\* A. Garrido Ríos, B. Echeverría García, J. Borbujo

*Servicio de Dermatología, Hospital Universitario de Fuenlabrada, Fuenlabrada, Madrid, Spain*

\* Corresponding author.

E-mail address: [esromo16@gmail.com](mailto:esromo16@gmail.com) (E. Rojas Mora). 1578-2190/

© 2018 Published by Elsevier España, S.L.U. on behalf of Elsevier España, S.L.U. and AEDV.

## Circumscribed Palmar Hypokeratosis: Treatment with Cryotherapy<sup>☆</sup>



### Hipoqueratosis circunscrita palmar: tratamiento mediante crioterapia

To the Editor:

Circumscribed palmar hypokeratosis (CPH) is a skin disorder characterized by a well-circumscribed, depressed, reddish area with a scaly border. Lesions tend to be solitary and are typically located on the thenar and hypothenar eminences of the palms. There are no established treatments. We present 2 cases of CPH treated with cryotherapy on the thenar eminence of the palms of 2 patients.

The first patient was a 60-year-old woman with no relevant medical history who presented with a well-circumscribed, erythematous, depressed, lesion with a stair-like border on the thenar eminence of the right hand (Fig. 1A). The lesion was not hard to the touch and had appeared a year earlier. It had been treated with topical corticosteroids but shown no improvement. The second patient was a 66-year-old woman, also with no relevant past history, who presented with a similar plaque of 7 years' duration on the thenar eminence of the right palm (Fig. 2A). The lesion had grown progressively over the years. Both patients denied triggers.

Dermoscopy in both cases revealed an erythematous-pink, round, central area with white spots and a stair-like border with desquamation. In both cases, histologic examination showed depression of the epidermis with a sharp stair-like border between the normal and affected skin (Fig. 3). The depressed epidermis showed hypokeratosis

and hypogranulosis compared with the surrounding skin. A cornoid lamella was not observed in serial slices. There were also no signs of atypia. The histologic findings were consistent with a diagnosis of CPH. CPH was first described in 2002.<sup>1</sup> It clinically presents as a round, erythematous, circumscribed, asymptomatic, generally solitary, lesion on the thenar or hypothenar eminences of the palms, although plantar lesions have been reported. The condition usually affects women aged between 51 and 70 years, although there has been a report of a congenital case.<sup>2,3</sup> Numerous hypotheses have been proposed to explain the etiology and pathogenesis of CPH, including human papillomavirus

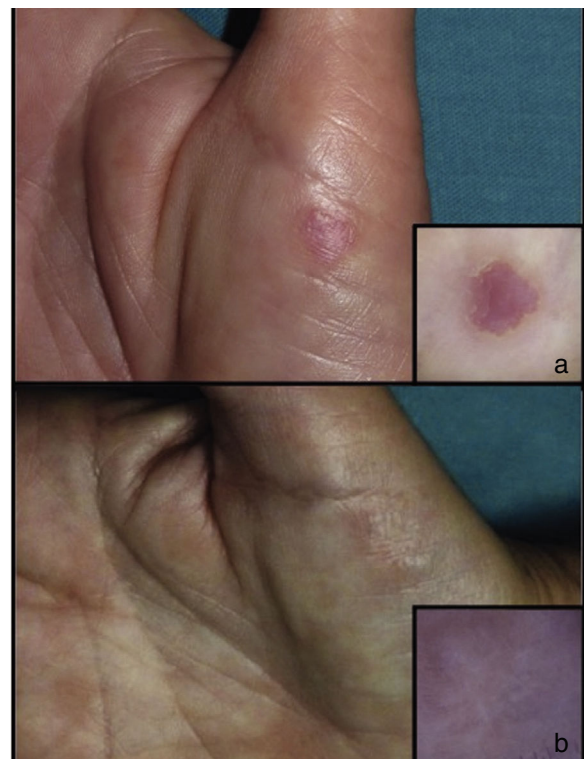
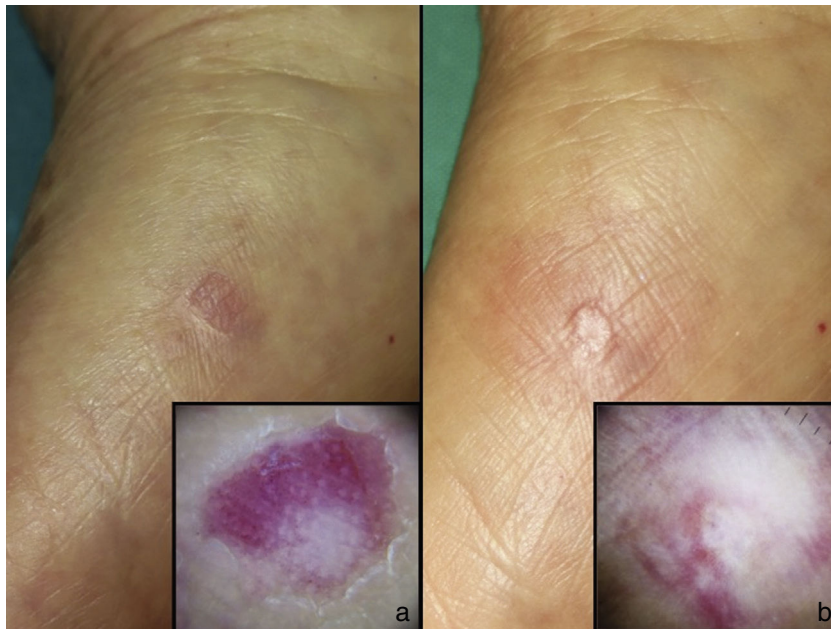
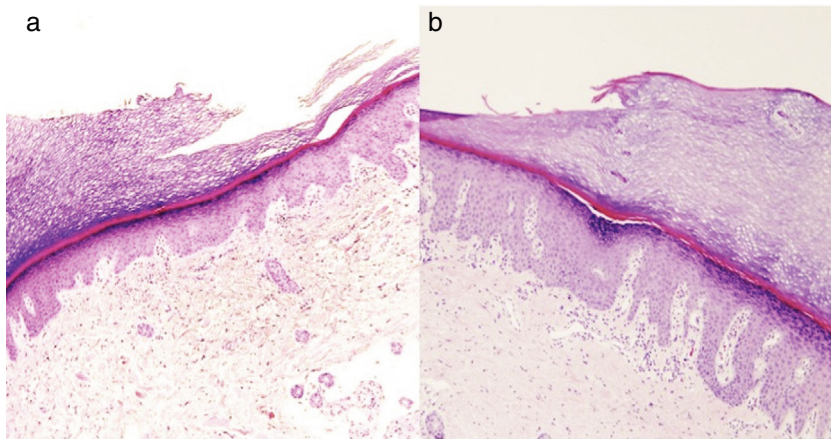


Figure 1 Case 1. Before (A) and after (B) treatment.

<sup>☆</sup> Please cite this article as: Boix-Vilanova J, Montis-Palos MC, Giacaman A, Antón-Valentí E. Hipoqueratosis circunscrita palmar: tratamiento mediante crioterapia. *Actas Dermosifiliogr.* 2019;110:174–176.



**Figure 2** Case 2. Before (A) and after (B) treatment.



**Figure 3** Note the sudden stair-like epidermal thinning in both patients showing a depressed, hypokeratotic epidermal area and hypogranulosis (hematoxylin-eosin, original magnification  $\times 10$ ).

infection, repeated trauma, or a defect in keratinization in the affected area. This last hypothesis is the most widely accepted one.

The defect in keratinization was originally thought to be due to a localized epidermal malformation,<sup>1</sup> but it is currently thought that it might be due to clonal expansion of altered keratinocytes, as there have been reports of slow-growing lesions,<sup>3-5</sup> like the one in our second patient.

The differential diagnosis should include porokeratosis of Mibelli, Bowen disease, the base of a blister in the erosion stage, or more rarely, pitted keratolysis.<sup>3</sup>

CPH is considered to be a benign disease, but there has been a case in which histologic changes associated with actinic keratosis were observed, suggesting possible malignant transformation.<sup>6</sup> Follow-up is therefore recommended.

There are no established treatments. Surgical excision, photodynamic therapy, topical corticosteroids, 5-fluorouracil, and topical calcipotriol have all been used, but with highly variable results.<sup>3</sup> There has also been a case of CPH that had resolved completely by the 2-month visit following treatment with two 15-second cycles of liquid nitrogen cryotherapy.<sup>7</sup> As cryotherapy is affordable, has few adverse effects, and is readily available in routine practice, we decided to use the same cryotherapy regimen in our 2 patients. In the first patient the lesion resolved completely (Fig. 1B) and in the second patient, it also cleared, but left a scar-like papular area (Fig. 2B). The rationale for the use of cryotherapy is the existence of altered keratinocytes undergoing clonal expansion that would be destroyed and replaced by adjacent healthy keratinocytes, thereby resolving the defect.

Finally, and in agreement with Boffa and Degaetano,<sup>7</sup> we believe that cryotherapy could be considered a first-line, safe, accessible, affordable, and effective treatment for CPH.

## Conflicts of Interest

The authors declare that they have no conflicts of interest.

## References

- Pérez A, Rütten A, Gold R, Urbina F, Misad C, Izquierdo MJ, et al. Circumscribed palmar or plantar hypokeratosis: A distinctive epidermal malformation of the palms or soles. *J Am Acad Dermatol.* 2002;47:21–7.
- Arbesman J, Loss LC, Helm KF, Rothman IL. A congenital case of circumscribed acral hypokeratosis. *Pediatr Dermatol.* 2012;29:485–7.
- Urbina F, Pérez A, Requena L, Rütten A. Hipoqueratosis circunscrita palmar o plantar. Conocimientos y controversias tras 10 años de su descripción. *Actas Dermosifiliogr.* 2014;105:574–82.
- Obermoser G, Zelger B. Multifocal circumscribed palmar hypokeratosis: Malformation or not? *J Am Acad Dermatol.* 2003;49:1197–8.
- Ishiko A, Dekio I, Fujimoto A, Kameyama K, Sakamoto M, Benno Y, et al. Abnormal keratin expression in circumscribed palmar hypokeratosis. *J Am Acad Dermatol.* 2007;57:285–91.
- Kanitakis J, Lora V, Balme B, Roby J. Premalignant circumscribed palmar hypokeratosis: A new form of circumscribed palmar hypokeratosis? Case report and literature review. *Dermatology.* 2010;220:143–6.
- Boffa MJ, Degaetano JS. Circumscribed palmar hypokeratosis: Successful treatment with cryotherapy. *J Eur Acad Dermatol Venereol.* 2007;21:420–1.

J. Boix-Vilanova,<sup>a,\*</sup> M.C. Montis-Palos,<sup>a</sup> A. Giacaman,<sup>a</sup> E. Antón-Valentí<sup>b</sup>

<sup>a</sup> Servicio de Dermatología, Hospital Universitari Son Espases, Palma de Mallorca, Islas Baleares, Spain

<sup>b</sup> Servicio de Anatomía Patológica, Hospital Universitari Son Espases, Palma de Mallorca, Islas Baleares, Spain

\* Corresponding author.

E-mail address: julian.boix@gmail.com (J. Boix-Vilanova). 1578-2190/

© 2018 Elsevier España, S.L.U. and AEDV. Published by Elsevier España, S.L.U. All rights reserved.

## Usefulness of Reflectance Confocal Microscopy For in Vivo Diagnosis of Sebomatricomas<sup>☆</sup>



### Utilidad de la microscopía confocal de reflectancia para el diagnóstico in vivo de los sebomatricomas

To the Editor:

There is a spectrum of sebaceous neoplasms, ranging from indolent lesions to sebaceous carcinoma. The nomenclature used in the literature is somewhat controversial, and to date no standardized classification scheme exists.<sup>1</sup> Sánchez Yus and coworkers<sup>2</sup> suggested that sebaceous adenoma and sebaceoma represent 2 extremes of a spectrum of benign neoplasms with sebaceous differentiation and differing degrees of maturation, with higher and lower percentages of mature cells, respectively, and proposed the term *sebomatricoma* to describe this spectrum. We present 2 cases that illustrate the usefulness of reflectance confocal microscopy (RCM) for the diagnosis and characterization of sebomatricoma.

## Case 1

The patient was a 48-year-old woman with hypothyroidism who was seen for a slow-growing lesion on the nasal dorsum that had appeared several years earlier. Dermoscopic examination of the 4-mm, skin-colored papule revealed brown globules predominating in the upper half, yellowish unstructured areas in the lower half, and regular linear vessels (Fig. 1). RCM revealed the presence of ovoid cells with a dark, round, central nucleus and abundant bright granular cytoplasm with very well-defined borders, features typical of sebocytes. There were few very large, bright speckled cells (mature sebocytes) and a predominance of less reflective cells with less abundant cytoplasm (immature sebocytes) that were aggregated within nodules. RCM also revealed circular hyporeflexive spaces (ducts with sebaceous differentiation), rounded, hyperreflective structures surrounded by a dark halo (corneal cysts), and abundant bright, cotton-like cells with no visible nucleus, irregular morphology, and poorly-defined borders that were gathered in small groups (macrophages). A diagnosis of sebaceoma was proposed based on the RCM findings, and was confirmed by histology (Fig. 2).

## Case 2

The patient was an 81-year-old woman with dyslipidemia and no past history of interest. She was seen for a lesion on the abdomen that had appeared 1 year earlier. The lesion was an orange, erythematous plaque of 2.5 × 1.5 cm with well-defined borders. Dermoscopy

<sup>☆</sup> Please cite this article as: Burillo-Martínez S, Gamo R, Pinedo F, López-Esteban JL. Utilidad de la microscopía confocal de reflectancia para el diagnóstico in vivo de los sebomatricomas. *Actas Dermosifiliogr.* 2019;110:176–179.