



ACTAS Derma-Sifiliográficas

Full English text available at
www.actasdermo.org



REVIEW

Guidelines for Diagnosis and Treatment of Cutaneous Sarcomas: Dermatofibrosarcoma Protuberans[☆]



B. Llombart,^{a,*} C. Serra,^a C. Requena,^a M. Alsina,^b D. Morgado-Carrasco,^b V. Través,^c O. Sanmartín^a

^a Servicio de Dermatología, Instituto Valenciano de Oncología, Valencia, Spain

^b Servicio de Dermatología, Hospital Clínic de Barcelona, Universitat de Barcelona, Barcelona, Spain

^c Servicio de Anatomía Patológica, Instituto Valenciano de Oncología, Valencia, Spain

Received 6 December 2017; accepted 23 May 2018

KEYWORDS

Sarcoma;
Dermatofibrosarcoma
protuberans;
Diagnosis;
Treatment

Abstract Sarcomas comprise a broad group of tumors, many of whose biological behavior and aggressiveness differ from one type to another. The therapeutic approach is generally multidisciplinary and often complex. Developments in surgical and oncological dermatology during the last few decades have positioned dermatologists as specialists in the diagnosis and treatment of skin cancer. The aim of this article is to review the main soft tissue sarcomas that typically affect the skin. Dermatofibrosarcoma protuberans is a low-grade malignant sarcoma. It exhibits slow-growth, is locally invasive, and has low metastatic potential (< 3%). Mohs micrographic surgery is the treatment of choice. The *COL1A1-PDGFB* translocation should be analyzed in cases of unclear diagnosis and when it is necessary to identify candidates for tyrosine kinase inhibitors. Imatinib is indicated for the treatment of locally advanced and metastatic dermatofibrosarcoma protuberans.

© 2018 Published by Elsevier España, S.L.U. on behalf of Elsevier España, S.L.U. and AEDV.

PALABRAS CLAVE

Sarcoma;
Dermatofibrosarcoma
protuberans;
Diagnóstico;
Tratamiento

Sarcomas cutáneos: directrices para el diagnóstico y tratamiento. Dermatofibrosarcoma protuberans

Resumen Los sarcomas constituyen un grupo amplio de tumores, muchos de ellos con comportamiento biológico y agresividad diferentes entre sí, que habitualmente requieren un tratamiento multidisciplinario, frecuentemente complejo. El desarrollo en las últimas décadas de la dermatología quirúrgica y oncológica ha permitido que los dermatólogos se conviertan en

[☆] Please cite this article as: Llombart B, Serra C, Requena C, Alsina M, Morgado-Carrasco D, Través V, et al. Sarcomas cutáneos: directrices para el diagnóstico y tratamiento. Dermatofibrosarcoma protuberans. Actas Dermosifiliogr. 2018;109:868–877.

* Corresponding author.

E-mail address: beatriz.llombart@uv.es (B. Llombart).

los especialistas responsables del diagnóstico y tratamiento del cáncer cutáneo. El propósito de este artículo es revisar los principales sarcomas de partes blandas de localización típicamente cutánea.

El dermatofibrosarcoma protuberans es un sarcoma de bajo grado de malignidad, con un crecimiento lento e infiltrativo localmente y escasa capacidad metastásica (< 3%). El tratamiento de elección es la cirugía micrográfica de Mohs. Es recomendable solicitar el estudio de la translocación COL1A1-PDGFB cuando existen dudas diagnósticas, y para determinar qué pacientes pueden responder a los fármacos inhibidores de la tirosina quinasa. El imatinib está indicado en el dermatofibrosarcoma protuberans localmente avanzado y metastásico.

© 2018 Publicado por Elsevier España, S.L.U. en nombre de Elsevier España, S.L.U. y AEDV.

Introduction

Sarcomas are a large, heterogeneous group of rare tumors that are typically treated using a multidisciplinary, often complex, approach. Developments in surgical and oncological dermatology in recent decades have positioned dermatologists as specialists in the diagnosis and treatment of skin cancer. This is a particularly pertinent consideration in the case of cutaneous soft tissue sarcomas. Sarcoma treatment is dealt with in numerous guidelines, but none of these specifically deal with sarcomas involving the skin. In addition, they have been drawn up by experts from specialties involved in the different stages of diagnosing and treating sarcomas (oncologists, pathologists, radiologists, traumatologists, and general and plastic surgeons), but they are missing input from dermatologists. This input is essential, as in many cases, the treatment of a retroperitoneal sarcoma cannot be extrapolated to that of a cutaneous sarcoma. The aim of this article is to provide clear recommendations, supported by the best possible clinical evidence, on the management of the main cutaneous sarcomas from a dermatological perspective to facilitate good clinical practice.

General Background

Sarcomas are a large group of tumors that in many cases have varying biologic behavior and levels of aggressiveness. Soft tissue sarcomas are a heterogeneous group of rare tumors of mesenchymal origin. They account for less than 1% of all malignant tumors in adults and 12% of those in children.^{1,2} The vast majority (80%) arise in the soft tissues (including the skin), whilst the remainder originate in the bone, or, less frequently, the organs.

Soft tissue sarcomas have a broad histopathologic spectrum, possibly because the embryonic mesenchymal cells from which they are derived can differentiate into many types of tissue. The World Health Organization's classification of soft tissue sarcomas is based on the possible tissue origin of different types of tumors, including fibrosarcoma, angiosarcoma, liposarcoma, leiomyosarcoma, rhabdomyosarcoma, and synovial sarcoma. Over 100 histologic subtypes are contemplated in this classification.^{1,2}

The most common subtype of soft tissue sarcoma is undifferentiated pleomorphic sarcoma, followed by liposarcoma, leiomyosarcoma, and myxofibrosarcoma. The main

cutaneous variants are dermatofibrosarcoma protuberans (DFSP) and Kaposi sarcoma.³

Soft tissue sarcomas are diagnosed and classified according to histologic patterns, immunohistochemical findings, and associated cytogenetic alterations.^{1,3,4} Histologic assessment continues to be the main diagnostic tool in sarcomas. Immunohistochemistry is a useful tool for exploring histogenetic origin, while molecular techniques such as fluorescence in situ hybridization (FISH) techniques, reverse transcription polymerase chain reaction (RT-PCR), and sequencing enable the identification of specific chromosomal translocations in many sarcomas.

Several grading and staging systems have been developed to guide prognosis. The 2 most widely used systems are the French *Fédération Nationale de Centres de Lutte Contre le Cancer* (FNCLCC) grading system (Table 1) and the American Joint Committee on Cancer (AJCC) Staging Manual (Table 2).⁵⁻⁷ The FNCLCC system is based on histologic differentiating parameters, number of mitoses, and the presence or absence of necrosis, while the AJCC system takes into account tumor size and location (superficial or deep), lymph node involvement, metastasis, and histologic differentiation.^{8,9}

Hematogenous spread is more common than lymphatic spread in soft tissue sarcomas. Overall, lymph node involvement is uncommon, but it is relatively frequent in certain entities, such as rhabdomyosarcoma, synovial sarcoma, clear cell sarcoma, and epithelioid sarcoma. Tumors with a poor prognosis based on the FNCLCC grading system (large, deep, and high-grade tumors) are associated with metastasis, typically to the lungs; 10% of all patients with soft tissue sarcomas have metastasis on diagnosis.⁶ Most soft tissue sarcomas seen by dermatologists, however, have a low risk of hematogenous spread, with the exception of angiosarcoma and subcutaneous leiomyosarcoma (Table 3).⁶

In this review, we examine soft tissue sarcomas with a typical cutaneous location, with a particular focus on dermatofibrosarcoma protuberans (DFSP), pleomorphic dermal sarcoma, leiomyosarcoma, angiosarcoma, and Kaposi sarcoma. We have excluded other sarcomas that can affect the skin, such as epithelioid sarcoma, malignant nerve sheath tumor, and liposarcoma, as they are rarely seen by dermatologists.

The purpose of this article is not to provide an exhaustive review of all possible cutaneous and/or superficial sarcomas, but rather to provide dermatologists with a general

Table 1 Fédération National de Centres de Lutte Contre le Cancer (FNCLCC) Grading System for Soft Tissue Sarcomas.⁷

FNCLCC Grading Parameters	
Parameter	Criterion
<i>Tumor differentiation</i>	
Score 1	Sarcoma resembling normal adult mesenchymal tissue
Score 2	Sarcomas for which histologic typing is certain
Score 3	Embryonal and undifferentiated sarcomas: sarcomas of doubtful type
<i>Mitotic count</i>	
Score 1	0-9/10 high-power fields (HPFs)
Score 2	10-19/10 HPFs
Score 3	20/10 HPFs
<i>Necrosis (microscopic)</i>	
Score 1	No necrosis
Score 2	≤ 50% tumor necrosis
Score 3	> 50% tumor necrosis
<i>Histologic grade</i>	
Grade 1	Total score 2, 3
Grade 2	Total score 3, 4
Grade 3	Total score 5, 6

guide to diagnosing and treating the most common tumors seen.

Dermatofibrosarcoma Protuberans

Introduction

DFSP is a rare, slow-growing, and generally indolent cutaneous sarcoma that accounts for 5% of all sarcomas. Approximately 80% to 90% of DFSPs are low-grade tumors and fewer than 3% metastasize, although local recurrence is common due to the invasive nature of the tumor. Complete surgical excision is the treatment of choice. Five-year survival is very high (99%-100%).¹²

Epidemiology and Clinical Diagnosis

DFSP accounts for less than 0.1% of all skin tumors.¹⁰ Its estimated incidence is between 0.8 and 5 cases per million inhabitants per year.¹¹ It is more common in young adults (with onset occurring between the second and fifth decades of life), although it can appear at any age, from birth to old age.^{13,14} It appears to affect men and women equally. DFSP is seen in people of all racial backgrounds, but it is more common in black people, in particular Bednar tumor, which is a pigmented form of DFSP. The trunk is the most common site for DFSP, with approximately 50% to 60% of all tumors occurring in this region.¹⁰ The next most common sites are the proximal extremities (20%-30%) and the head and neck (10%-15%), particularly, the scalp, forehead, and supraclavicular fossa.^{15,16}

DFSP is a solitary, multilobulated tumor of varying shapes and sizes. The lesion feels very firm on palpation, and it is fixed to overlying but not underlying tissue.¹⁷ The clinical appearance of DFSP depends on time since onset. It grows very slowly and there have even been reports of tumors being diagnosed 50 years after onset.¹⁸ It tends to

present as a solitary, firm, asymptomatic, indurated plaque with a violaceous, reddish-brown, or pink appearance; it has a hard consistency and is fixed to the skin but not the deep layers (Fig. 1 A and B).¹⁹ The plaque can remain stable for long periods of time, grow slowly, or enter a phase of rapid growth characterized by the development of multiple nodules that gave rise to the term *protuberans* (Fig. 1 C and D). Data from large series, however, indicate that over 50% of tumors have a protruding morphology from the outset.²⁰ DFSP lesions include morphea-like plaques, depressed lesions similar to those seen in atrophoderma, and erythematous or violaceous plaques resembling hemangioma. The most common presentation in adults is a large plaque with multiple superficial nodules. Children more commonly have nonprotruding lesions that resemble a morphea plaque, or in congenital cases, an atrophoderma plaque or vascular malformation.

Lesion size is variable and depends on time to diagnosis, which can be considerable. Lesions normally measure 2 to 5 cm in diameter, although there have been reports of giant lesions measuring over 20 cm.^{10,13,15,16} A clinical suspicion of DFSP must be confirmed by biopsy prior to surgery.

Histologic Diagnosis

The biopsy specimen must include subcutaneous tissue. Histology shows a poorly delimited tumor invading the full thickness of the dermis and extending into the subcutaneous tissue (Fig. 2 A, B, and C). It is formed by a dense, uniform proliferation of monomorphous spindle cells with long nuclei, intercellular collagen, and small capillaries. Spindle cells have short interlaced, whorled fascicles that form a pattern typically described as *storiform*. In some areas, the cells irradiate from an acellular, fibrous focus, creating a characteristic cartwheel pattern.¹⁷

Neoplastic cells in DFSP are minimally pleomorphic and mitotic activity is low (generally < 2 mitotic figures per 10

Table 2 TNM Classification of Soft Tissue Sarcomas From the American Joint Committee on Cancer (AJCC) Staging Manual (7th Edition, 2010), 2016 version.⁵

AJCC Definitions and Staging System					
<i>Primary tumor (T)</i>					
TX: Primary tumor cannot be assessed					
T0: No evidence of primary tumor					
T1: Tumor ≤ 5 cm in greatest dimension					
T1a: Superficial tumor: located above superficial fascia without invasion of the fascia					
T1b: Deep tumor: located beneath the superficial fascia or superficial to the fascia but with invasion of or through the fascia					
T2: Tumor with a maximum diameter ≥ 5 cm					
T2a: Superficial tumor					
T2b: Deep tumor					
<i>Regional lymph nodes (N)</i>					
NX: Regional lymph nodes cannot be assessed					
N0: No regional lymph node metastasis					
N1: Regional lymph node metastasis					
<i>Distant metastasis (M)</i>					
Mx: Distant metastasis cannot be assessed					
M0: No distant metastasis					
M1: Distant metastasis					
<i>Histologic grade</i>					
GX: Grade cannot be assessed					
G1: Well differentiated					
G2: Moderately differentiated					
G3: Poorly differentiated or undifferentiated					
Stage	Grade	Primary Tumor	Regional Lymph Nodes	Metastasis	
IA	G1 or GX	T1a or T1b	N0	M0	
IB	G1 or GX	T2a or T2b	N0	M0	
IIA	G2 or G3	T1a or T1b	N0	M0	
IIB	G2	T2a or T2b	N0	M0	
III	Any G	Any T	Any N	M0	
IV	Any G	Any T	Any N	M1	

Table 3 Main Cutaneous Sarcomas Classified by Histologic Subtype and Approximate 5-Year Survival Rates.

Histologic Subtype	Histologic Grade			Prognosis	
	I	II	III	5-Year Survival	
Kaposi sarcoma	→			60%-100% depending on immune status	
Dermatofibrosarcoma protuberans	→			97%-100%	
Fibrosarcomatous dermatofibrosarcoma	→			90%-95%	
Congenital fibrosarcoma	→			90%-100%	
Leiomyosarcoma	→			97% dermal	65% subcutaneous
Liposarcoma	→			80%	
Pleomorphic sarcoma	→			80%-90%	
Epithelioid sarcoma	→			70%	
Malignant peripheral nerve sheath tumor	→			60%	
Angiosarcoma	→			35%-40%	

high-power fields). Cells are denser in the center than at the periphery, where the edges of the tumor extend into the dermis and subcutaneous tissue. DFSP is characterized by tentacle-like projections that invade the subcutaneous tissue and can reach considerable distances from the center of

the tumor. These irregular cords of spindle cells can extend quite far, both horizontally and vertically, and on occasions they resemble fibrous connective tissue,¹⁶ possibly explaining why certain tumors recur after what appeared to be an adequate resection.

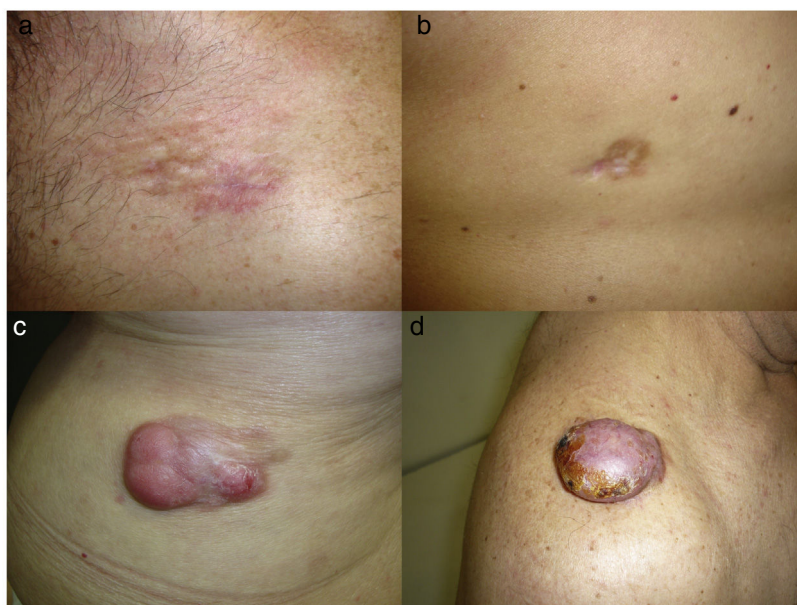


Figure 1 A, A dermatofibrosarcoma protuberans (DFSP) morphea-like plaque in the clavicular region. B, A DFSP atrophic plaque on the back. C, A multinodular DFSP in the lumbar area. D, A nodular DFSP on the shoulder.

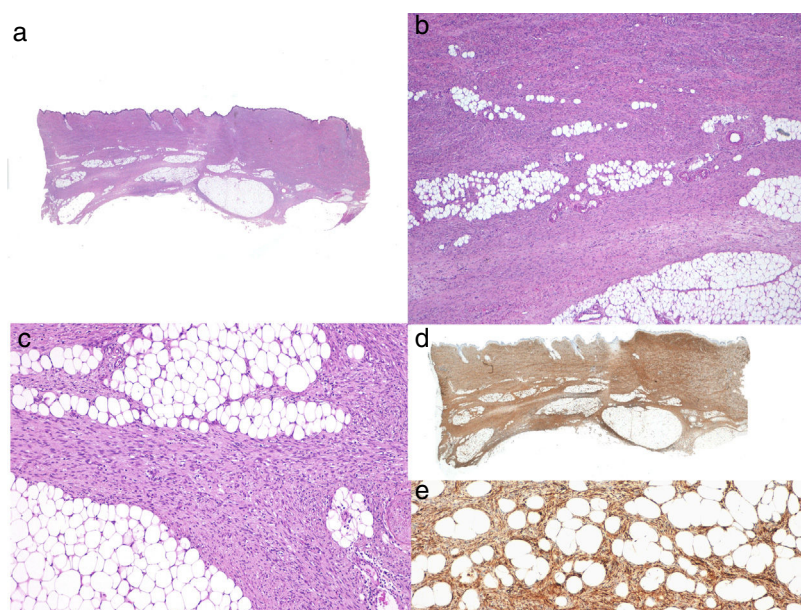


Figure 2 Typical histologic features of a DFSP. A, Panoramic view with hematoxylin-eosin. B and C, Tumor invasion of the dermis and hypodermis. D, Panoramic view of strong CD34 expression. E, Detail of spindle cells among adipocytes with strong CD34 positivity.

Different clinicopathologic subtypes of DFSP have been defined (Table 4).²¹⁻²⁸ The histologic subtype of DFSP with the worst prognosis is fibrosarcomatous DFSP (DFSP-FS), which accounts for approximately 10% to 20% of cases.²⁹ DFSP-FS should be suspected in patients with large, fast-growing lesions that invade the muscle.¹⁵

Pathologists should describe fibrosarcomatous areas in the pathology report due to the prognostic implications, namely that DFSP-FS is associated with a greater tendency

to recur and metastasize.^{30,31} Fibrosarcomatous areas can occupy between 5% and 90% of tumors. Fibrosarcomatous areas are characterized by a denser proliferation of spindle cells arranged in long fascicles that intersect at various angles, creating a fishbone pattern. The transition between fibromatous and conventional areas may be gradual or abrupt. Invasion by the fibrosarcomatous component of DFSP is characterized by greater compression. This component also has a higher rate of mitosis and cellular atypia than classic DFSP.

Table 4 Dermatofibrosarcoma Protuberans (DFSP): Histologic Subtypes.

Atrophic
Giant cell DFSP
Sclerosing or sclerotic
Giant cell fibroblastoma or juvenile DFSP
Bednar tumor or pigmented DFSP
Fibrosarcomatous
Myoid
Myxoid
Subcutaneous

When there is histologic evidence of DFSP, an immunohistochemical study should be performed to rule out other tumors with similar features. The most characteristic immunohistochemical finding in DFSP is CD34 positivity, which is seen in 80% to 100% of neoplastic cells (Fig. 2 D and E).^{10,32} Absence of this marker, however, does not necessarily exclude a diagnosis. In fact, CD34 expression may be weak or absent in fibrosarcomatous areas; this marker can be used to identify the presence of a fibrosarcomatous component.^{29,33} CD34 is also very useful for checking for tumor-free margins after surgery, differentiating between neoplastic cells (CD34⁺) and fibroblasts in healthy adjacent skin (CD34⁻),³⁴ and distinguishing between residual tumor and tumor scarring in cases of recurrent DFSP.³⁵ Nonetheless, like all immunohistochemical markers, CD34 is not only found in neoplastic DFSP cells, but has also been described in other benign and malignant tumors, including solitary fibrous tumor, dermal dendrocyte hamartoma, spindle cell lipoma, angiosarcoma, sclerotic fibroma, epithelioid sarcoma, and fibroblastic connective tissue nevus.

A repeat biopsy is recommended when a clinically suspicious DFSP is not confirmed histologically³⁶ (Fig. 3).

Molecular Profiling

DFSP has a characteristic translocation of genetic material involving 2 genes: the platelet-derived growth factor subunit B gene (*PDGFB*) and the collagen type 1 alpha 1 gene (*COL1A1*), whose fusion gives rise to a new chimeric gene with transformative capacity.

The *COL1A1-PDGFB* fusion gene in DFSP can be detected by isolating RNA from the tumor using FISH or molecular biology techniques or by performing RT-PCR. This chimeric gene is present in 90% of DFSPs.^{33,37-39} While detection of the gene thus confirms a diagnosis, failure to do so does not rule one out.

The *COL1A1-PDGFB* fusion gene has been found in all clinicopathologic variants of DFSP, confirming that all these entities constitute a single tumor entity, albeit with varying histologic phenotypes.³³

Identification of the t(17;22) translocation by FISH or RT-PCR is not necessary for diagnosis in most cases. However, considering the specific nature of this translocation, molecular assays are very useful, and advisable, when there are diagnostic doubts or in cases of advanced disease to identify candidates for tyrosine kinase inhibitors. FISH is more

sensitive and should be performed first. RT-PCR should be ordered in cases of unassessable or negative FISH tests.

Staging

Superficial DFSPs that are not clinically fixed to the deeper planes do not require imaging studies. When local involvement of the deep planes (fascia or muscle) is suspected, magnetic resonance imaging (MRI) is the preoperative test of choice (Fig. 3).⁴⁰ We recommend using MRI to investigate large tumors extending into the deeper layers, recurrent tumors, and tumors in complicated anatomic locations (head and neck).⁴¹

As metastasis is rare (<3% of cases), staging studies are not required, unless prompted by symptoms.^{36,42} A computed tomography scan of the lungs is advisable in patients with recurrent disease and DFSP-FS. The lungs are the most common site for metastasis from DFSP,⁴³ although the tumor has also been known to spread to the brain, bone, abdominal-pelvic region, and heart.

Like most sarcomas, DFSP rarely spreads to the regional lymph nodes. In fact, regional lymph node metastasis is 3 times less common than visceral metastasis. There have been isolated reports of mixed patterns of spread (hematogenous and lymphatic).^{44,45} Prognosis is dramatically worse for patients with metastasis (survival ≤ 2 years following diagnosis of disease spread).¹⁶

Treatment

Surgical Treatment

Complete surgical excision is the treatment of choice for DFSP. The growth of DFSP, with tentacles extending into fatty tissue, is highly asymmetric. These extensions may not be clinically evident and can even go unnoticed in conventional histology if the lateral and deep margins of the surgical specimen are not examined in their entirety.⁴⁶ Several recent studies that have compared conventional wide local excision (WLE) and Mohs micrographic surgery (MMS)^{47,48} have demonstrated that MMS is associated with a much lower recurrence rate than WLE (3% vs 30%), a smaller surgical defect (8.8 cm vs 10.7 cm), and greater sparing of healthy tissue.⁴⁷ In conclusion, MMS is currently the surgical treatment of choice for DFSP (supported by level of evidence 1B) (Fig. 3). The most widely accepted variant of MMS is slow Mohs (paraffin study), but other techniques have also been used, including the Breuninger technique, complete circumferential assessment, and 3D histology assessment of paraffin-embedded sections.^{36,49,50} The minimum excision depth should be 1 cm, i.e., it should extend down to the fascia, which does not need to be removed in the first step.

In hospitals where it is not possible to perform MMS or refer patients for this option, conventional surgery with deep margins of 2 to 3 cm, extending into the fascia, is recommended (Fig. 3).⁵¹⁻⁵⁵ MMS is essential for recurrent lesions, lesions in complicated locations, such as the head or neck, and uncommon or more aggressive histologic subtypes (DFSP-FS).

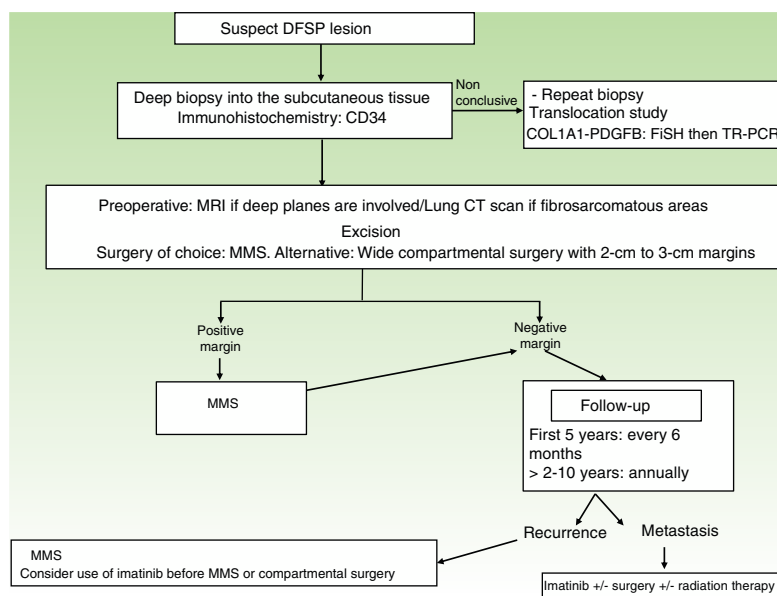


Figure 3 Algorithm for managing DFSP. CT indicates computed tomography; DFSP, dermatofibrosarcoma protuberans; FISH, fluorescence in situ hybridization; MMS, Mohs micrographic surgery; MRI, magnetic resonance imaging; RT-PCR, reverse transcript polymerase chain reaction.

Regardless of the technique employed, surgical resection must be carefully planned to take into account tumor size, location, and histologic subtype. It is very important to check that all traces of tumor have been removed prior to reconstruction and particularly before flap-repair procedures.

Radiation Therapy

The role of radiation therapy as an adjuvant treatment in DFSP has not been analyzed in a clinical trial to date. Radiation therapy is never a substitute for adequate surgical excision, and is not indicated as a postoperative treatment for patients with tumor-free margins.⁴² There have been isolated reports of radiation therapy being used when surgery would have led to major cosmetic or functional defects, and, more frequently, following surgical treatment with positive margins.^{56–59} Nevertheless, the series published to date have analyzed very few patients and the follow-up times have been very short. In addition, most of these studies were performed before the introduction of imatinib therapy. In our experience, MMS is essential in patients with DFSP with positive margins and radiation therapy should not be administered. In our department, we have treated 240 DFSPs with MMS; 3 of the tumors recurred and were resolved with repeat surgery; radiation therapy was not necessary in any of the cases. Regular monitoring is essential in patients administered radiation therapy, as there have been reports of conventional DFSP progressing to DFSP-FS following this treatment.^{60,61} In addition, radiation therapy could induce another sarcoma in the irradiated area. To conclude, radiation therapy should be reserved for truly exceptional cases, such as unresectable tumors (palliative local therapy) and metastatic DFSP.

Systemic Treatment

DFSP does not respond to conventional chemotherapy used to treat soft tissue sarcomas and should therefore not be used, at least as a first-line option.⁴²

In Europe, imatinib mesylate is approved for the treatment of inoperable primary tumors, inoperable local recurrent tumors, and metastatic DFSP.^{62,63} Tests to detect the fusion gene *COL1A1-PDGFB* are advisable prior to treatment with imatinib, as this drug acts by competitive binding to platelet-derived growth factor receptors on tumor cells, blocking their tyrosine kinase activity. Imatinib appears to be useful as a neoadjuvant treatment for reducing tumor size and facilitating surgery in locally advanced cases with extensive, difficult-to-access lesions. Partial responses of 50% to 80% have been reported by the series published to date.^{63–66} The recommended starting dose is 400 mg/d, as this dose offers the same efficacy as higher doses but is much better tolerated. The dose can be increased to 600 to 800 mg in the absence of response. Optimal duration of neoadjuvant treatment has not been well defined, but peak effects are achieved around month 5 or 6. Immunohistochemical and molecular profiling studies are recommended in patients treated with imatinib, as in some areas of the tumor, it can be difficult to determine the presence or absence of neoplastic cells. New tyrosine kinase inhibitors (sunitib, sorafenib, and pazopanib) are being used in patients resistant to imatinib.^{67–69}

Follow-up

Staging studies are not needed during follow-up, unless prompted by symptoms. Clinical examinations are necessary every 6 months over 5 years to enable early detection of local recurrences (Fig. 3). The recommendation thus is

to schedule annual follow-up visits for 10 years following surgery.³⁶ Most recurrences occur within 3 years of surgery, although much later recurrences have been described.

On occasions, local MRI can be useful for monitoring recurrent DFSP or DFSP-FS, complicated surgical cases (those requiring > 2 MMS steps), and tumors located on the head and neck.

Conclusions

Cutaneous sarcomas are an important entity in oncological dermatology. Dermatologists play an important role in the overall management of patients with DFSP.

Conflicts of Interest

The authors declare that they have no conflicts of interest.

References

- Fletcher CD. Recently characterized soft tissue tumors that bring biologic insight. *Mod Pathol*. 2014;27 Suppl 1:S98–112.
- Fletcher CDM, Bridge JA, Hogendoorn PCW, Mertens F. *World Health Organization Classification of tumours of soft tissue and bone*. 4th ed Lyon: IARC Press; 2013.
- Patt JC, Haines N. Soft tissue sarcomas in skin: Presentations and management. *Semin Oncol*. 2016;43:413–8.
- Compton LA, Doyle LA. Advances in the genetic characterization of cutaneous mesenchymal neoplasms: Implications for tumor classification and novel diagnostic markers. *Surg Pathol Clin*. 2017;10:299–317.
- Greene FL, Page DL, Fleming ID, Fritz A, Balch CM, Haller DG, et al. *American Joint Committee on Cancer: AJCC cancer staging manual*. 6th ed New York, NY, USA: Springer; 2002. p. 157–64.
- Deyrup AT, Weiss SW. Grading of soft tissue sarcomas: The challenge of providing precise information in an imprecise world. *Histopathology*. 2006;48:42–50.
- Coindre JM, Trojani M, Contesso G, David M, Rouesse J, Bui NB, et al. Reproducibility of a histopathologic grading system for adult soft tissue sarcoma. *Cancer*. 1986;58:306–9.
- Edge SB, Compton CC. *The American Joint Committee on Cancer: The 7th edition of the AJCC cancer staging manual and the future of TNM*. *Ann Surg Oncol*. 2010;17:1471–4.
- Fletcher CD. The evolving classification of soft tissue tumours - an update based on the new 2013 WHO classification. *Histopathology*. 2014;64:2–11.
- Gloster HM Jr. Dermatofibrosarcoma protuberans. *J Am Acad Dermatol*. 1996;35 3 Pt 1:355–74.
- Criscione VD, Weinstock MA. Descriptive epidemiology of dermatofibrosarcoma protuberans in the United States, 1973 to 2002. *J Am Acad Dermatol*. 2007;56:968–73.
- Reshadi H, Rouhani A, Mohajerzadeh S, Moosa M, Elmi A. Prevalence of malignant soft tissue tumors in extremities: an epidemiological study in syria. *Arch Bone Jt Surg*. 2014;2:106–10.
- Sanmartin O, Llombart B, Lopez-Guerrero JA, Serra C, Requena C, Guillen C. Dermatofibrosarcoma protuberans. *Actas Dermosifiliogr*. 2007;98:77–87.
- Llombart B, Serra-Guillen C, Monteagudo C, Lopez Guerrero JA, Sanmartin O. Dermatofibrosarcoma protuberans: A comprehensive review and update on diagnosis and management. *Semin Diagn Pathol*. 2013;30:13–28.
- Llombart B, Monteagudo C, Sanmartin O, Lopez-Guerrero JA, Serra-Guillen C, Poveda A, et al. Dermatofibrosarcoma protuberans: A clinicopathological, immunohistochemical, genetic (COL1A1-PDGFB), and therapeutic study of low-grade versus high-grade (fibrosarcomatous) tumors. *J Am Acad Dermatol*. 2011;65:564–75.
- Serra-Guillen C, Llombart B, Sanmartin O. Dermatofibrosarcoma protuberans. *Actas Dermosifiliogr*. 2012;103:762–77.
- Taylor HB, Helwig EB. Dermatofibrosarcoma protuberans. A study of 115 cases. *Cancer*. 1962;15:717–25.
- Rutgers EJ, Kroon BB, Albus-Lutter CE, Gortzak E. Dermatofibrosarcoma protuberans: Treatment and prognosis. *Eur J Surg Oncol*. 1992;18:241–8.
- Lambert WC, Abramovits W, Gonzalez-Sevra A, Souchon E, Schwartz RA, Little WP Jr. Dermatofibrosarcoma non-protuberans: Description and report of five cases of a morpheaform variant of dermatofibrosarcoma. *J Surg Oncol*. 1985;28:7–11.
- Martin L, Piette F, Blanc P, Mortier L, Avril MF, Delaunay MM, et al. Clinical variants of the preprotuberant stage of dermatofibrosarcoma protuberans. *Br J Dermatol*. 2005;153:932–6.
- Dupree WB, Langloss JM, Weiss SW. Pigmented dermatofibrosarcoma protuberans (Bednar tumor). A pathologic, ultrastructural, and immunohistochemical study. *Am J Surg Pathol*. 1985;9:630–9.
- Shmookler BM, Enzinger FM, Weiss SW. Giant cell fibroblastoma. A juvenile form of dermatofibrosarcoma protuberans. *Cancer*. 1989;64:2154–61.
- Zelger BW, Ofner D, Zelger BG. Atrophic variants of dermatofibroma and dermatofibrosarcoma protuberans. *Histopathology*. 1995;26:519–27.
- Orlandi A, Bianchi L, Spagnoli LG. Myxoid dermatofibrosarcoma protuberans: morphological, ultrastructural and immunohistochemical features. *J Cutan Pathol*. 1998;25:386–93.
- Diaz-Cascajo C. Myoid differentiation in dermatofibrosarcoma protuberans and its fibrosarcomatous variant. *J Cutan Pathol*. 1997;24:197–8.
- Diaz-Cascajo C, Weyers W, Borghi S. Sclerosing dermatofibrosarcoma protuberans. *J Cutan Pathol*. 1998;25:440–4.
- Banerjee SS, Harris M, Eyden BP, Hamid BN. Granular cell variant of dermatofibrosarcoma protuberans. *Histopathology*. 1990;17:375–8.
- Llombart B, Serra-Guillen C, Rubio L, Nagore E, Requena C, Traves V, et al. Subcutaneous dermatofibrosarcoma protuberans, a rare subtype with predilection for the head: A retrospective series of 18 cases. *J Am Acad Dermatol*. 2017;77, 503- 11 e1.
- Mentzel T, Beham A, Katenkamp D, Dei Tos AP, Fletcher CD. Fibrosarcomatous (“high-grade”) dermatofibrosarcoma protuberans: clinicopathologic and immunohistochemical study of a series of 41 cases with emphasis on prognostic significance. *Am J Surg Pathol*. 1998;22:576–87.
- Abbott JJ, Oliveira AM, Nascimento AG. The prognostic significance of fibrosarcomatous transformation in dermatofibrosarcoma protuberans. *Am J Surg Pathol*. 2006;30:436–43.
- Bowne WB, Antonescu CR, Leung DH, Katz SC, Hawkins WG, Woodruff JM, et al. Dermatofibrosarcoma protuberans: A clinicopathologic analysis of patients treated and followed at a single institution. *Cancer*. 2000;88:2711–20.
- Cohen PR, Rapin RP, Farhood AI. Dermatofibroma and dermatofibrosarcoma protuberans: Differential expression of CD34 and factor XIIIa. *Am J Dermatopathol*. 1994;16:573–4.
- Llombart B, Sanmartin O, Lopez-Guerrero JA, Monteagudo C, Serra C, Requena C, et al. Dermatofibrosarcoma protuberans: Clinical, pathological, and genetic (COL1A1-PDGFB) study with therapeutic implications. *Histopathology*. 2009;54:860–72.

34. Jimenez FJ, Grichnik JM, Buchanan MD, Clark RE. Immunohistochemical margin control applied to Mohs micrographic surgical excision of dermatofibrosarcoma protuberans. *J Dermatol Surg Oncol.* 1994;20:687–9.
35. Prieto VG, Reed JA, Shea CR. CD34 immunoreactivity distinguishes between scar tissue and residual tumor in re-excisional specimens of dermatofibrosarcoma protuberans. *J Cutan Pathol.* 1994;21:324–9.
36. Saiag P, Grob JJ, Lebbe C, Malvey J, del Marmol V, Pehamberger H, et al. Diagnosis and treatment of dermatofibrosarcoma protuberans. European consensus-based interdisciplinary guideline. *Eur J Cancer.* 2015;51:2604–8.
37. Llombart B, Sanmartin O, Lopez-Guerrero JA, Monteagudo C, Calabuig S, Botella R, et al. Analysis of the COL1A1-PDGFB fusion gene in a case of dermatofibrosarcoma protuberans with a fibrosarcoma component. *Actas Dermosifiliogr.* 2006;97:337–41.
38. Salgado R, Llombart B, Pujol RM, Fernandez-Serra A, Sanmartin O, Toll A, et al. Molecular diagnosis of dermatofibrosarcoma protuberans: A comparison between reverse transcriptase-polymerase chain reaction and fluorescence in situ hybridization methodologies. *Genes Chromosomes Cancer.* 2011;50:510–7.
39. Patel KU, Szabo SS, Hernandez VS, Prieto VG, Abruzzo LV, Lazar AJ, et al. Dermatofibrosarcoma protuberans COL1A1-PDGFB fusion is identified in virtually all dermatofibrosarcoma protuberans cases when investigated by newly developed multiplex reverse transcription polymerase chain reaction and fluorescence in situ hybridization assays. *Hum Pathol.* 2008;39:184–93.
40. Serra-Guillen C, Sanmartin O, Llombart B, Nagore E, Deltoro C, Martin I, et al. Correlation between preoperative magnetic resonance imaging and surgical margins with modified Mohs for dermatofibrosarcoma protuberans. *Dermatol Surg.* 2011;37:1638–45.
41. MacFarlane D, Shah K, Wysong A, Wortsman X, Humphreys TR. The role of imaging in the management of patients with non-melanoma skin cancer: Diagnostic modalities and applications. *J Am Acad Dermatol.* 2017;76:579–88.
42. Garcia del Muro X, Martin J, Maurel J, Cubedo R, Bague S, de Alava E, et al. Soft tissue sarcomas: Clinical practice guidelines. *Med Clin (Barc).* 2011;136:408, e1-8.
43. Bonnabeau RC Jr, Stoughton WB, Armanious AW, Cuono CB, Mossburg WL, Lancaster JR. Dermatofibrosarcoma protuberans. Report of a case with pulmonary metastasis and multiple intrathoracic recurrences. *Oncology.* 1974;29:1–12.
44. D'Ambrosio Rosso GM, Barbazza R, Calabro S, Degli Angeli G, Dal Farra F, Puccetti C. Dermatofibrosarcoma protuberans with pulmonary and lymph node metastasis. Description of a case and review of the literature. *G Ital Dermatol Venereol.* 1984;119:345–50.
45. Kahn LB, Saxe N, Gordon W. Dermatofibrosarcoma protuberans with lymph node and pulmonary metastases. *Arch Dermatol.* 1978;114:599–601.
46. Hobbs ER, Wheeland RG, Bailin PL, Ratz JL, Yetman RJ, Zins JE. Treatment of dermatofibrosarcoma protuberans with Mohs micrographic surgery. *Ann Surg.* 1988;207:102–7.
47. Lowe GC, Onajin O, Baum CL, Otley CC, Arpey CJ, Roenigk RK, et al. A comparison of Mohs micrographic surgery and wide local excision for treatment of dermatofibrosarcoma protuberans with long-term follow-up: The Mayo Clinic experience. *Dermatol Surg.* 2017;43:98–106.
48. Veronese F, Boggio P, Tiberio R, Gattoni M, Fava P, Caliendo V, et al. Wide local excision vs Mohs tubingen technique in the treatment of dermatofibrosarcoma protuberans: A two-centre retrospective study and literature review. *J Eur Acad Dermatol Venereol.* 2017;31:2069–76.
49. Irrarazaval I, Redondo P. Three-dimensional histology for dermatofibrosarcoma protuberans: Case series and surgical technique. *J Am Acad Dermatol.* 2012;67:991–6.
50. Serra-Guillen C, Llombart B, Nagore E, Guillen C, Requena C, Traves V, et al. Mohs micrographic surgery in dermatofibrosarcoma protuberans allows tumour clearance with smaller margins and greater preservation of healthy tissue compared with conventional surgery: A study of 74 primary cases. *Br J Dermatol.* 2015;172:1303–7.
51. DuBay D, Cimmino V, Lowe L, Johnson TM, Sondak VK. Low recurrence rate after surgery for dermatofibrosarcoma protuberans: A multidisciplinary approach from a single institution. *Cancer.* 2004;100:1008–16.
52. Gloster HM Jr, Harris KR, Roenigk RK. A comparison between Mohs micrographic surgery and wide surgical excision for the treatment of dermatofibrosarcoma protuberans. *J Am Acad Dermatol.* 1996;35:82–7.
53. Kimmel Z, Ratner D, Kim JY, Wayne JD, Rademaker AW, Alam M. Peripheral excision margins for dermatofibrosarcoma protuberans: a meta-analysis of spatial data. *Ann Surg Oncol.* 2007;14:2113–20.
54. Stojadinovic A, Karpoff HM, Antonescu CR, Shah JP, Singh B, Spiro RH, et al. Dermatofibrosarcoma protuberans of the head and neck. *Ann Surg Oncol.* 2000;7:696–704.
55. Farma JM, Ammori JB, Zager JS, Marzban SS, Bui MM, Bichakjian CK, et al. Dermatofibrosarcoma protuberans: How wide should we resect? *Ann Surg Oncol.* 2010;17:2112–8.
56. Suit H, Spiro I, Mankin HJ, Efid J, Rosenberg AE. Radiation in management of patients with dermatofibrosarcoma protuberans. *J Clin Oncol.* 1996;14:2365–9.
57. Ballo MT, Zagars GK, Pisters P, Pollack A. The role of radiation therapy in the management of dermatofibrosarcoma protuberans. *Int J Radiat Oncol Biol Phys.* 1998;40:823–7.
58. Sun LM, Wang CJ, Huang CC, Leung SW, Chen HC, Fang FM, et al. Dermatofibrosarcoma protuberans: Treatment results of 35 cases. *Radiother Oncol.* 2000;57:175–81.
59. Lindner NJ, Scarborough MT, Powell GJ, Spanier S, Enneking WF. Revision surgery in dermatofibrosarcoma protuberans of the trunk and extremities. *Eur J Surg Oncol.* 1999;25:392–7.
60. Wrotnowski U, Cooper PH, Shmookler BM. Fibrosarcomatous change in dermatofibrosarcoma protuberans. *Am J Surg Pathol.* 1988;12:287–93.
61. Argiris A, Dardoufas C, Aroni K. Radiotherapy induced soft tissue sarcoma: An unusual case of a dermatofibrosarcoma protuberans. *Clin Oncol (R Coll Radiol).* 1995;7:59–61.
62. McArthur GA, Demetri GD, van Oosterom A, Heinrich MC, Debiec-Rychter M, Corless CL, et al. Molecular and clinical analysis of locally advanced dermatofibrosarcoma protuberans treated with imatinib: Imatinib Target Exploration Consortium Study B2225. *J Clin Oncol.* 2005;23:866–73.
63. Rutkowski P, Van Glabbeke M, Rankin CJ, Ruka W, Rubin BP, Debiec-Rychter M, et al. Imatinib mesylate in advanced dermatofibrosarcoma protuberans: pooled analysis of two phase II clinical trials. *J Clin Oncol.* 2010;28:1772–9.
64. Ugurel S, Mentzel T, Utikal J, Helmbold P, Mohr P, Pfohler C, et al. Neoadjuvant imatinib in advanced primary or locally recurrent dermatofibrosarcoma protuberans: A multicenter phase II DeCOG trial with long-term follow-up. *Clin Cancer Res.* 2014;20:499–510.
65. Stacchiotti S, Pantaleo MA, Negri T, Astolfi A, Tazzari M, Dagrada GP, et al. Efficacy and biological activity of imatinib in metastatic dermatofibrosarcoma protuberans (DFSP). *Clin Cancer Res.* 2016;22:837–46.
66. Zhu JH, Li QW, Xiao WH, Sun JZ, Wang RL, Lu JY. Advanced dermatofibrosarcoma protuberans treated with imatinib mesylate. *Zhonghua Zhong Liu Za Zhi.* 2011;33:470–2.
67. Fu Y, Kang H, Zhao H, Hu J, Zhang H, Li X, et al. Sunitinib for patients with locally advanced or distantly metastatic dermatofibrosarcoma protuberans but resistant to imatinib. *Int J Clin Exp Med.* 2015;8:8288–94.

68. Miyagawa T, Kadono T, Kimura T, Saigusa R, Yoshizaki A, Miyagaki T, et al. Pazopanib induced a partial response in a patient with metastatic fibrosarcomatous dermatofibrosarcoma protuberans without genetic translocations resistant to mesna, doxorubicin, ifosfamide and dacarbazine chemotherapy and gemcitabine-docetaxel chemotherapy. *J Dermatol.* 2017;44, e21-e2.
69. Kamar FG, Kairouz VF, Sabri AN. Dermatofibrosarcoma protuberans (DFSP) successfully treated with sorafenib: Case report. *Clin Sarcoma Res.* 2013;3:5.