



IMAGES IN DERMATOLOGY

Violaceous Papules on an Achromatic Macule[☆]

Pápulas violáceas sobre mácula acrómica



A. Imbernón-Moya,^{a,*} F. Burgos,^b M.Á. Gallego-Valdés^a

^a Servicio de Dermatología, Hospital Universitario Severo Ochoa, Leganés, Madrid, Spain

^b Servicio de Anatomía Patológica, Hospital Universitario Severo Ochoa, Leganés, Madrid, Spain

A 24-year-old man with a personal history of vitiligo on the hands, ankles, and genitals that did not improve with topical corticosteroids and tacrolimus consulted for the recent appearance of a pruriginous skin lesion on his right knee. The patient denied having applied topical products or taken oral medication. He also denied having experienced injury or stings and having been exposed to sunlight. Examination revealed shiny erythematous-violaceous papules. These were indurated, confluent, and irregular and were arranged in a reticulated pattern on a whitish achromic macular base (Fig. 1A). Skin biopsy revealed lichenoid dermatitis with a band-like perivascular lymphocytic infiltrate and involvement of the hair follicle infundibulum and a significant

absence of melanocytes in the basement layer after staining with MelanA in the immunohistochemistry workup (Fig. 1B). The patient was diagnosed with lichen planus associated with vitiligo and prescribed topical corticosteroids. His condition did not improve.

The appearance of 2 different skin conditions at the same site is exceptional. If the first skin disease remains active when the second skin disease appears, the phenomenon is considered a concurrent isotopic response induced by alteration of the inflammatory response. There have been reports of cases of lichen planus and lichen nitidus appearing on areas previously affected by vitiligo.

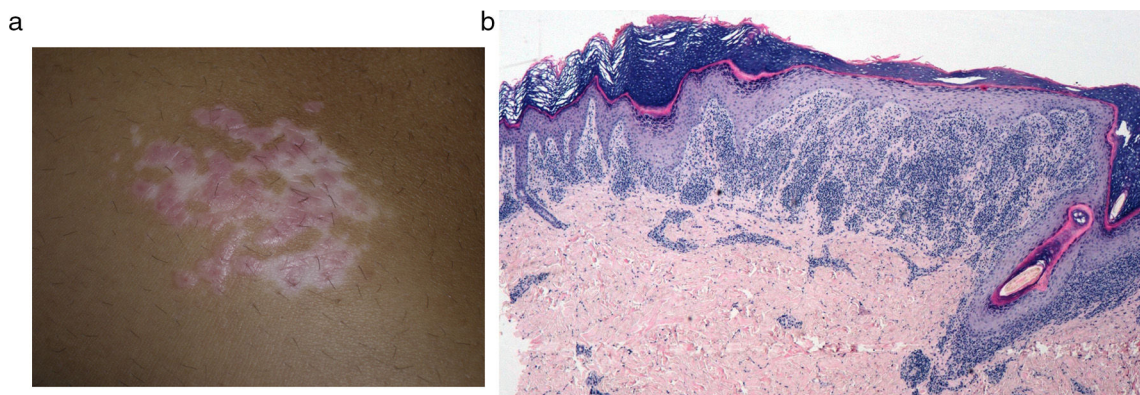


Figure 1

[☆] Please cite this article as: Imbernón-Moya A, Burgos F, Gallego-Valdés MÁ. Pápulas violáceas sobre mácula acrómica. Actas Dermosifiliogr. 2018;109:552.

* Corresponding author.

E-mail address: adrian_imber88@hotmail.com (A. Imbernón-Moya).