

10. Livneh A, Langevitz P, Zemer D, Zaks N, Kees S, Lidar T, et al. Criteria for the diagnosis of familial Mediterranean fever. *Arthritis Rheum.* 1997;40:1879–85.

L. Loidi Pascual,^{a,*} M. Larrea García,^a C. Llanos Chávarri,^b J.I. Yanguas Bayona^a

^a *Servicio de Dermatología, Complejo Hospitalario de Navarra, Pamplona, Navarra, Spain*

^b *Servicio de Anatomía Patológica, Complejo Hospitalario de Navarra, Pamplona, Navarra, Spain*

* Corresponding author.

E-mail address: leyre.loidi.pascual@cfnavarra.es (L. Loidi Pascual).

1578-2190/

© 2016 Elsevier España, S.L.U. and AEDV. All rights reserved.

Retrospective Observational Epidemiologic Study of Sensitization to Gold Sodium Thiosulfate in the Allergy Clinic of a Tertiary Hospital[☆]



Estudio epidemiológico, observacional y retrospectivo de la sensibilización a tiosulfato sódico de oro en la consulta de alergias de contacto de un hospital de tercer nivel

Dear Editor:

Gold sodium thiosulfate (GST) is a common sensitizer that is very prevalent in the environment. It was named allergen of the year by the North American Contact Dermatitis Society in 2001, and in 2012, it was included in the T.R.U.E. TEST allergen panel. T.R.U.E. TEST is a ready-to-use diagnostic test comprising 36 substances in 3 custom-prepared panels that provides the optimal allergen concentration in each of its patches. Consequently, since it first appeared, it has become increasingly used in dermatology departments, to the extent that it is now the standard series in many hospitals. The use of gold in patch tests is controversial. Its results are difficult to interpret, and, like many other metals, it is a common irritant. Consequently, it has been associated with late and persistent reactions (the possibility of active sensitization has even been considered). Furthermore, its relevance is difficult to identify, and the exact mechanisms by which this substance interacts with the human body remain unknown.¹⁻⁸

The objective of the present study was to determine where GST ranks in the order of frequency of sensitizers causing positive results in patients seen in the contact allergy department. We also aimed to identify the demographic characteristics of patients who tested positive to GST, establish the relevance of the positive results, and define the usefulness of standardized patch testing with the allergen.

We performed an observational retrospective epidemiological study of all patients seen in the contact allergy

department of a tertiary hospital from January to June 2015. Of the 234 patients seen, 85 (36.32%) were excluded because either they had not undergone patch testing or the results of their patch tests were negative. The series used was the T.R.U.E. TEST. For all patients, the variables studied were as follows: age, sex, profession, known allergies, intolerance to metals, time since lesions first appeared, symptoms, location, patient's identification of contactant, presence of any other skin complaint, and frequency of positive results in the T.R.U.E. TEST. Data were processed and analyzed using SPSS version 11.5 for Windows (SPSS Inc). Qualitative variables were compared using the chi-square test with a Yates correction or the Fisher exact test when the conditions for applying the chi-square test could not be met.

The 5 most common allergens were nickel sulfate, GST, thiazolinones, fragrance mix, and paraphenylenediamine. A total of 35 patients (23.5%) tested positive for GST, which came second to nickel sulfate (55.7%) in the present series. Dermatitis affected the hands in 57.1% of cases. No significant differences were detected with respect to age, sex, profession, intolerance to metal, and known allergies. Of the patients who tested positive to GST, 82.9% could not identify a contactant ($P = .012$). In addition, 17.1% were positive for GST only, whereas 99.1% of those who tested negative with GST were sensitized to ≥ 2 allergens ($P = .001$). We cannot rule out differences with respect to co-occurrence with other skin complaints ($P = .078$) (Table 1).

No contactant was identified in most of the GST-allergic patients. Many studies point to the ability of GST to cause irritation, persistent reaction, or even active sensitization. Although the dose used in the T.R.U.E. TEST series (75 $\mu\text{g}/\text{cm}^2$) meets the criteria for the minimum concentration for a positive reaction (+ or ++), some patients were seen to react to low concentrations of GST but not to slightly higher concentrations; therefore, reactivity to GST could involve underlying factors other than the concentration (eg, interactions between local amino acids, pressure, friction, skin damage, and eczema). The North American Contact Dermatitis Group recently decided to remove gold from its standard series,¹ and the Spanish Contact Dermatitis and Skin Allergy Research Group does not include gold in its standard series. Therefore, we propose withdrawing GST from the widely used T.R.U.E. TEST series. Furthermore, patients who test positive to GST are sensitized to a single allergen more commonly than patients who are sensitized to allergens other than GST, and patients with a positive T.R.U.E. TEST result who test negative for GST were followed more frequently in the dermatology department for other skin complaints. This observation could be associated with the major presence of gold in many areas of our lives.

[☆] Please cite this article as: Arteaga-Henríquez M, Latour-Álvarez I, García-Peris E, Pérez-Robayna N. Estudio epidemiológico, observacional y retrospectivo de la sensibilización a tiosulfato sódico de oro en la consulta de alergias de contacto de un hospital de tercer nivel. *Actas Dermosifiliogr.* 2017;108:164–166.

Table 1 Demographic Characteristics of Patients Who Tested Positive for ≥ 1 of the Allergens Tested.

Variable	Gold Sodium Thiosulfate		P Value	
	Negative	Positive		
Age, y	47.7	44.8	.51	
Female sex	75.4%	77.1%	.96	
Profession			.49	
	Homemaker	21.1%	Industrial materials	17.1%
	Industrial materials	18.4%	Homemaker	14.3%
	Hotel and catering	8.8%	Hotel and catering	11.4%
	Health care	7.9%	Health care	11.4%
	Construction	7.0%	Students	8.6%
	Students	7.0%	Construction	5.7%
	Hairdressers	3.5%	Agriculture	5.7%
	Long-term retired	2.6%	Hairdressers	5.7%
	Agriculture	0.9%	Long-term retired	2.9%
	Long-term unemployed	0.0%	Long-term unemployed	2.9%
	Other (low-risk)	17.5%	Other (low-risk)	11.4%
	Unknown	5.3%	Unknown	2.9%
Intolerance to metals	48.2%	48.6%	.97	
Known allergies			.30	
	None	62.3%	None	60.0%
	Other	14.9%	Drugs	20.0%
	Drugs	11.4%	Drugs and other	8.6%
	Foods	3.5%	Other	5.7%
	Drugs and other	3.5%	Foods and other	2.9%
	Drugs and foods	2.6%	All	2.9%
	Foods and other	0.9%	Foods	0.0%
	All	0.9%	Foods and drugs	0.0%
Personal history of atopy	39.0%	45.7%	.51	
High IgE levels	22.8%	28.6%	.49	
Positive RAST results	1: 3.5%	1: 0.0%	.53	
	> 2: 23.7%	> 2: 25.7%		
Course	39.5 mo	35.6 mo	.90	
Clinical manifestations				
	Acute eczema	81.6%	Acute eczema	74.3%
	Pruritus	64.9%	Pruritus	68.6%
	Nonspecific lesions	46.5%	Nonspecific lesions	45.7%
	Chronic eczema	35.1%	Chronic eczema	42.9%
	Urticaria	11.4%	Urticaria	2.9%
Location			.51	
	Various sites	37.7%	Upper limbs	40.0%
	Upper limbs	25.4%	Various sites	28.6%
	Head and neck	18.4%	Head and neck	11.4%
	Trunk	10.5%	Trunk	11.4%
	Lower limbs	7.0%	Lower limbs	5.7%
	Unknown	0.9%	Unknown	2.9%
Contactant identified	40.4%	17.1%	.01	
Other skin complaints	66.7%	50.0%	.08	
Only 1 positive result in the T.R.U.E. TEST	0.9%	17.1%	.00	

Abbreviation: RAST, radioallergosorbent test.

The considerable stability of gold means that it is difficult to find it in its ionic form at concentrations sufficiently high to cause reactions, although concentrations may be sufficiently high to cause sensitization.⁹

References

1. Chen J, Lampel H. Gold contact allergy. *Dermatitis*. 2015;26:69–77.
2. Boonchai W, Iamtharachai P. Risk factors for common contact allergens and patch test results using a modified European baseline series in patients tested during between 2000 and 2009 at Siriraj Hospital. *Asian Pac J Allergy Immunol*. 2013;32:60–5.
3. Mehta V, Balachandran C. Persistent nodular contact dermatitis to gold: Case report of two cases. *Indian J Dermatol Venereol Leprol*. 2010;76:397.
4. Möller H. Contact allergy to gold as a model for clinical-experimental research. *Contact Dermatitis*. 2010;62:193–200.
5. Thyssen J, Menné T. Metal allergy-A review on exposures, penetration, genetics, prevalence, and clinical implications. *Chem Res Toxicol*. 2010;23:309–18.
6. Andersen K, Jensen C. Long-lasting patch reactions to gold sodium thiosulfate occurs frequently in healthy volunteers. *Contact Dermatitis*. 2007;56:214–7.
7. Lee A, Eun H, Kim H, Moon K, Lee C, Kim G, et al. Multicenter study of the frequency of contact allergy to gold. *Contact Dermatitis*. 2001;45:214–6.
8. Fowler J. Gold allergy in North America. *Am J Contact Dermat*. 2001;12:3–5.
9. Bruze M, Conde-Salazar L, Goossens A, Kanerva L, White I. Thoughts on sensitizers in a standard patch test series. *Contact Dermatitis*. 1999;41:241–50.

M. Arteaga-Henríquez,* I. Latour-Álvarez, E. García-Peris, N. Pérez-Robayna

Servicio de Dermatología, Hospital Universitario de Canarias, San Cristóbal de La Laguna, Tenerife, España

*Corresponding author.

E-mail address: mariaarteagah@gmail.com

(M. Arteaga-Henríquez).

1578-2190/

© 2016 Elsevier España, S.L.U. and AEDV. All rights reserved.

Isotretinoin-Induced Elkonyxis[☆]



Elconixis por isotretinoína

To the Editor:

Elkonyxis is a change in the nails characterized by marked fragility of the dorsal nail plate, irregular defects, loss of substance, or depressions that are larger than the pitting typical of psoriasis.^{1–3} The clinical appearance thus varies from an irregular roughness of the nail plate to perforation. Elkonyxis has only rarely been described in the medical literature. We present a case of elkonyxis secondary to treatment with isotretinoin.

The patient was a 17-year-old male with no past personal or family history of interest. He had moderate inflammatory acne that had recurred after several cycles of treatment with minocycline and he was therefore started on treatment with isotretinoin at a dose of 40 mg/d. The clinical course was unremarkable, with progressive improvement in his acne, minimal xerotic changes in the skin, and mild cheilitis. Laboratory tests showed no relevant alterations. During the third month of follow-up, the patient asked us to look at what he considered to be fragile nails, which he had first noticed a month after starting treatment. He denied trauma, manual labor, concurrent pathologic disorders, or other drugs. He also denied any previous nail changes or any past personal or familial history of psoriasis.

On inspection, the nail plates of all the fingernails presented various degrees of deformity, with irregular depressions, a rough surface, and brittleness (Figures 1 and 2). Some pitting, leukonychia, and oil spots were also visible. Mild desquamating periungual hyperkeratosis was observed and there was partial loss of the cuticle of the first nail of the right hand. No changes were observed in the toenails. The patient was offered the possibility of isotretinoin dose reduction or withdrawal, but he declined. Treatment was completed successfully and 4 months later the nails had recovered a normal appearance.

Elkonyxis is a rare nail disorder that has been reported in association with diseases such as peritonitis,⁴ psoriasis, syphilis, and reactive arthritis, or induced by trauma^{2,3} or by retinoids.^{1,5} The etiology and pathogenesis are unclear, but alterations of keratinization of inflammatory, traumatic, or pharmacological origin have been proposed. These changes occur in the nail matrix or in the proximal nail fold, giving

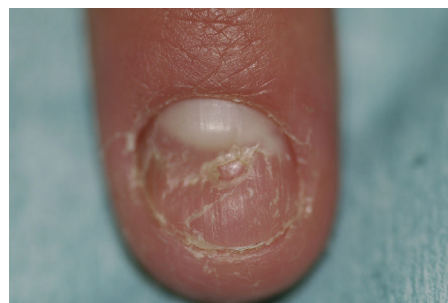


Figure 1 Brittle appearance of the nail of the left index finger, with a central depression larger than that seen in pitting.

[☆] Please cite this article as: Allegue F, González-Vilas D, Zulaica A. Elkonyxis por isotretinoína. *Actas Dermosifiliogr*. 2017;108:166–167.