

In our second case, the marked vascularization present on Doppler led us to consider a differential diagnosis with venous malformations. On ultrasound, venous malformations are seen as tubular structures, occasionally with hyperechoic structures with a posterior shadow (phleboliths), with a venous wave on pulsed Doppler. In this case, as the lesion was small and had not presented episodes of increasing size, we observed a predominance of areas with Doppler flow and a smaller anechoic central region.

In conclusion, Doppler can be a very useful tool for the diagnosis of ADF. The anechoic areas with no flow correspond histologically to the ectatic areas and the regions with Doppler flow correspond to the vascularized and cellular areas.

## Conflicts of Interest

The authors declare that they have no conflicts of interest.

## References

- Güngör Ş, Erdemir AT, Öztürk Sarı Ş, Büyükbabani N, Kocatürk E, Gürel MS. Aneurysmal dermatofibroma with dermoscopic and reflectance confocal microscopic features. *J Eur Acad Dermatol Venerol*. 2015;10:1–3.
- Santa Cruz DJ, Kyriakos M. Aneurysmal (angiomatoid) fibrous histiocytoma of the skin. *Cancer*. 1981;47:2053–61.
- Luzar B, Calonje E. Cutaneous fibrohistiocytic tumours - An update. *Histopathology*. 2010;56:148–65.
- Calonje E, Fletcher CD. Aneurysmal benign fibrous histiocytoma: Clinicopathological analysis of 40 cases of a tumour frequently misdiagnosed as a vascular neoplasm. *Histopathology*. 1995;26:323–31.
- Zaballos P, Llambrich Á, Ara M, Olazarán Z, Malveyh J, Puig S. Dermoscopic findings of haemosiderotic and aneurysmal dermatofibroma: Report of six patients. *Br J Dermatol*. 2006;154:244–50.
- Wortsman X, Wortsman J. Clinical usefulness of variable-frequency ultrasound in localized lesions of the skin. *J Am Acad Dermatol*. 2010;62:247–56.
- Crisan D, Gheuca Solovastru L, Crisan M, Badea R. Cutaneous histiocytoma - histological and imaging correlations. A case report. *Med Ultrason*. 2014;16:268–70.
- Zarchi K, Kromann CB, Wortsman X, Jemec GB. Usefulness of ultrasound for the diagnosis of dermatofibroma. *Med Ultrason*. 2016;18:131–3.
- Hata H, Natsuga K, Aoyagi S, Homma E, Shimizu H. Ultrasound B-mode and elastographic findings of angiomatoid fibrous histiocytoma. *Clin Exp Dermatol*. 2014;39:538–9.

B. Echeverría-García,<sup>a,\*</sup> C. García-Donoso,<sup>a</sup> J.C. Tardío,<sup>b</sup> J. Borbujo<sup>a</sup>

<sup>a</sup> Servicio de Dermatología, Hospital Universitario de Fuenlabrada, Fuenlabrada, Madrid, Spain

<sup>b</sup> Servicio de Anatomía Patológica, Hospital Universitario de Fuenlabrada, Fuenlabrada, Madrid, Spain

\*Corresponding author.

E-mail address: [begona.echeverria@salud.madrid.org](mailto:begona.echeverria@salud.madrid.org)

(B. Echeverría-García).

1578-2190/

© 2016 Elsevier España, S.L.U. and AEDV. All rights reserved.

## Familial Mediterranean Fever: Diagnostic Difficulties in an Atypical Case<sup>☆</sup>



## Fiebre mediterránea familiar. Dificultades diagnósticas en un caso atípico

To the Editor:

A 68-year-old woman with a history of neurosensory deafness and anemia of chronic disease consulted for more than 20 years of recurrent episodes of fever, joint and muscle pain, and skin lesions on the arms and trunk. The episodes occurred every 2 to 6 months and lasted around 2 weeks. She was asymptomatic between episodes. Large edematous erythematous plaques arose on her trunk and the root of her upper limbs (Fig. 1), associated with fever of 38 °C. Blood tests were normal. Skin biopsy showed edema and an inflammatory infiltrate of lymphocytes and neu-

trophils in the superficial dermis, without fibrinoid necrosis (Fig. 2).

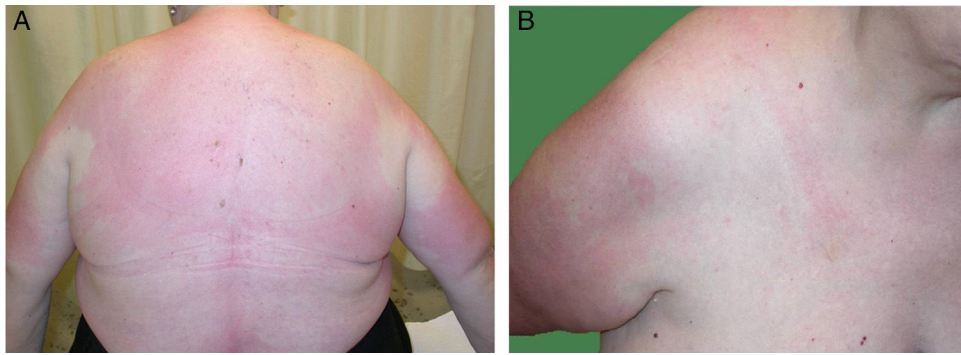
She subsequently developed fever associated with erythema and increased temperature in 1 of her legs, with blisters and an abundant exudate (Fig. 3). A gram-negative microorganism was isolated on culture, and this was interpreted as infectious cellulitis. Four months later she presented similar manifestations in her other leg.

Genetic analysis was performed of genes *MEFV*, *TNFRSF1A*, *MVK*, *NLRP3*, *NOD2*, and *PSTPIP1*. The patient was heterozygous for the c.1772T>C variant of gene *MEFV*.

As she also satisfied the Tel-Hashomer diagnostic criteria for familial Mediterranean fever (FMF) (Table 1), she was diagnosed with this entity. Treatment was started with colchicine, which led to a marked improvement in the clinical manifestations.

FMF is the most common autoinflammatory disease of adults.<sup>1</sup> It has a monogenic autosomal recessive inheritance, caused by a mutation in gene *MEFV* (16p13.3), although 20% of patients are heterozygous.<sup>2</sup> This could be because it is actually an autosomal dominant disease with variable penetrance, it was not possible to detect the second mutation due to technical limitations, or that it could be a polygenic disease. Some authors have stated that these patients

<sup>☆</sup> Please cite this article as: Pascual LL, García ML, Chávarri CL, Bayona JIY. Fiebre mediterránea familiar. Dificultades diagnósticas en un caso atípico. *Actas Dermosifiliogr*. 2017;108:161–164.



**Figure 1** A and B, Large edematous erythematous plaques with an urticarial appearance and increased local temperature. The lesions were found on the trunk and root of the upper limbs.

have a later onset of the disease, with a shorter duration of outbreaks, milder symptoms, and longer symptom-free intervals.<sup>3</sup>

Gene *MEFV* codes the protein pyrin, also known as marenstrin, which plays a role in regulation of the innate immune response. Alteration of this protein removes control from the pathway, increasing the levels of interleukin 1 $\beta$ , responsible for the inflammatory response in this disease.<sup>4</sup>

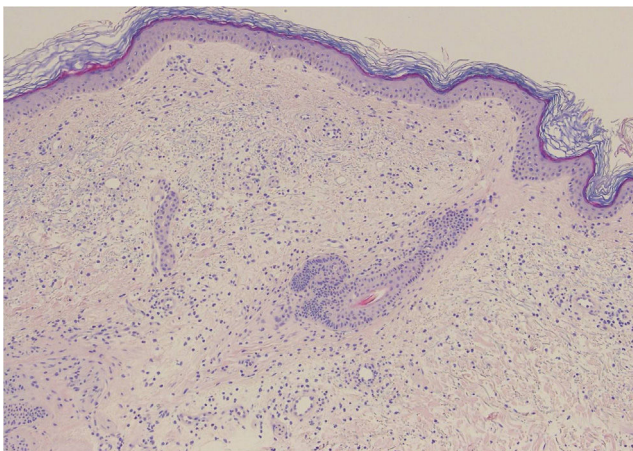
Soriano and Manna<sup>5</sup> described 4 clinical phenotypes of the disease:

- *Type 1*: Patients with recurrent episodes of short duration (12-72 h) with fever, acute abdominal pain, joint involvement, acute chest pain due to pleuritis/pericarditis, and various skin manifestations. Patients are usually asymptomatic between outbreaks, although biochemical evidence of the disease can be detected.
- *Type 2*: Patients who develop secondary amyloidosis (AA type) with proteinuria or kidney failure before they

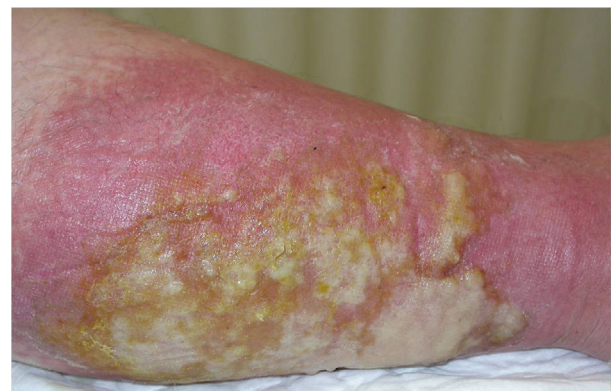develop other signs of FMF, or as the only manifestation in relatives of patients with FMF.

- *Type 3*: Carriers of a mutation of gene *MEFV* with no clinical manifestations of the disease and no amyloidosis. This occurs in endemic populations (such as Iraqi Jews and Ashkenazi Jews), with a prevalence of 1 in 25 to 1 in 300 persons. Although the majority never present clinical manifestations, some do develop amyloidosis with time (phenotype 2).
- *FMF-like*: Heterozygous patients with mild clinical manifestations of the disease. Our patient falls into this phenotype.

Cutaneous manifestations of the disease occur in 10% to 40% of affected patients.<sup>6</sup> Only erysipelas- or cellulitis-like lesions, seen in 5% to 30% of patients with FMF, are considered specific, and they arise on the anterior surface of the legs and dorsum of the feet. Histology reveals a perivascular dermal infiltrate made up mainly of mononuclear cells and neutrophils, but with no vasculitis.<sup>7</sup> The episodes that affected our patient's legs probably corresponded to this clinical presentation. Panniculitis can present as erythema nodosum or neutrophilic pan-



**Figure 2** Edema associated with a moderate inflammatory infiltrate of lymphocytes and neutrophils in the superficial dermis, with occasional images of leukocytoclasia. No extravasation of red blood cells is observed, nor the presence of hemosiderophages or lesions of fibrinoid necrosis in the vessel walls. Hematoxylin and eosin, original magnification  $\times 20$ .



**Figure 3** Hot erythematous plaque on a leg, with blister formation and an abundant exudate.

**Table 1** Tel-Hashomer Diagnostic Criteria<sup>a</sup>

Major Criteria	Minor Criteria	Data That Support the Diagnosis
Typical episodes: recurrent, <72 hours, febrile 1. Diffuse peritonitis 2. Unilateral pleuritis or pericarditis 3. Monoarthritis of the lower limbs 4. Fever as the only manifestation	<b>Atypical episodes<sup>b</sup></b> : no fever, longer duration, other manifestations different from 1-3 of the Major Criteria 4. Pain in the lower limbs on exertion 5. <b>Favorable response to colchicine</b>	1. Family history of FMF 2. Typical ethnic origin 3. Onset < 20 years Characteristics of the episodes: 4. <b>Marked alteration of the general state, requiring rest</b> 5. <b>Spontaneous remission</b> 6. <b>Symptom-free between episodes</b> 7. Elevation of at least 1 AFR: fibrinogen, white cell count, ESR 8. Episodes of proteinuria or hematuria 9. Acute abdomen with negative exploratory laparotomy 10. Consanguinity

<sup>a</sup> Diagnostic requirements: 1 mayor criterion, 2 minor criteria, 1 minor criterion + 5 findings that support the diagnosis, or 4 of the first 5 parameters that support the diagnosis.

<sup>b</sup> The criteria in our patient, who satisfied 2 minor criteria and 4 findings that supported the diagnosis, are shown in bold type. AFR indicates acute phase reactant; ESR, erythrocyte sedimentation rate.

niculitis. Urticarial manifestations are more typical of other autoinflammatory syndromes, such as TRAPS (tumor necrosis factor receptor associated periodic fever syndrome) and CAPS (cryopyrin-associated autoinflammatory syndromes).<sup>8</sup>

The differential diagnosis should include other autoinflammatory diseases.<sup>8</sup> In our case, we considered Muckle-Wells syndrome because of the urticarial lesions and neurosensorial deafness, although the genetic analysis finally confirmed the diagnosis of FMF. Some authors believe that patients with FMF may have a greater prevalence of auditory loss than the unaffected population, but there has been no evidence of this in any controlled study.<sup>9</sup>

The diagnostic criteria of FMF were established in 1997 (Table 1).<sup>10</sup> The diagnosis is clinical; genetic analysis is only used for support. In our opinion, genetic analysis may be fundamental to reaching the diagnosis in some cases. However, detection of a mutation cannot alone confirm the diagnosis, particularly in endemic populations in which prevalence of the mutation is very high.

The main objectives of treatment are the prevention of outbreaks and, in the long-term, of secondary amyloidosis. The drug of choice is colchicine, 1-3 mg/d.<sup>4</sup>

In conclusion, in patients with recurrent episodes of fever with cutaneous manifestations, we should consider the autoinflammatory syndromes, which include FMF. The diagnosis is basically clinical, although genetic analysis can be very useful. This disease is classically considered to have autosomal recessive inheritance, although a notable percentage of heterozygous patients have symptoms, meaning that aspects of the genetics of this disease still remain to be clarified.

## References

- Hernández-Rodríguez J, Ruíz-Ortiz E, Tomé A, Espinosa G, González-Roca E, Mensa-Vilaró A, et al. Clinical and genetic characterization of the autoinflammatory diseases diagnosed in an adult reference center. *Autoimmun Rev*. 2016;15:9–15.
- Shohat M, Halpern GJ. Familial Mediterranean Fever. In: Pagon RA, Adam MP, Ardinger HH, Wallace SE, Amemiya A, Bean LJ, et al., editors. *GeneReviews*<sup>®</sup> [Internet]. Seattle (WA): University of Washington, Seattle; 1993. Available at: <http://www.ncbi.nlm.nih.gov/books/NBK1227/>
- Moradian MM, Sarkisian T, Ajrapetyan H, Avanesian N. Genotype-phenotype studies in a large cohort of Armenian patients with familial Mediterranean fever suggest clinical disease with heterozygous MEFV mutations. *J Hum Genet*. 2010;55:389–93.
- Grattagliano I, Bonfrate L, Ruggiero V, Scaccianoce G, Palasciano G, Portincasa P. Novel therapeutics for the treatment of familial Mediterranean fever: From colchicine to biologics. *Clin Pharmacol Ther*. 2014;95:89–97.
- Soriano A, Manna R. Familial Mediterranean fever: New phenotypes. *Autoimmun Rev*. 2012;12:31–7.
- Leiva-Salinas M, Francés-Rodríguez L, Betlloch-Mas I. Espectro clínico de las manifestaciones cutáneas de la fiebre mediterránea familiar. *Piel (Barc)*. 2013;28:531–5.
- Kolivras A, Provost P, Thompson CT. Erysipelas-like erythema of familial Mediterranean fever syndrome: A case report with emphasis on histopathologic diagnostic clues. *J Cutan Pathol*. 2013;40:585–90.
- Nguyen TV, Cowen EW, Leslie KS. Autoinflammation from monogenic syndromes to common skin diseases. *J Am Acad Dermatol*. 2013;68:834–53.
- Polat K, Uysal IO, Senel S, Güler C, Durmuş K, Müderris S. Evaluation of hearing in patients with familial Mediterranean fever. *Eur Arch Otorhinolaryngol*. 2013;270:2871–4.



10. Livneh A, Langevitz P, Zemer D, Zaks N, Kees S, Lidar T, et al. Criteria for the diagnosis of familial Mediterranean fever. *Arthritis Rheum.* 1997;40:1879–85.

L. Loidi Pascual,<sup>a,\*</sup> M. Larrea García,<sup>a</sup> C. Llanos Chávarri,<sup>b</sup> J.I. Yanguas Bayona<sup>a</sup>

<sup>a</sup> *Servicio de Dermatología, Complejo Hospitalario de Navarra, Pamplona, Navarra, Spain*

<sup>b</sup> *Servicio de Anatomía Patológica, Complejo Hospitalario de Navarra, Pamplona, Navarra, Spain*

\* Corresponding author.

E-mail address: [leyre.loidi.pascual@cfnavarra.es](mailto:leyre.loidi.pascual@cfnavarra.es) (L. Loidi Pascual).

1578-2190/

© 2016 Elsevier España, S.L.U. and AEDV. All rights reserved.

## Retrospective Observational Epidemiologic Study of Sensitization to Gold Sodium Thiosulfate in the Allergy Clinic of a Tertiary Hospital<sup>☆</sup>



### Estudio epidemiológico, observacional y retrospectivo de la sensibilización a tiosulfato sódico de oro en la consulta de alergias de contacto de un hospital de tercer nivel

Dear Editor:

Gold sodium thiosulfate (GST) is a common sensitizer that is very prevalent in the environment. It was named allergen of the year by the North American Contact Dermatitis Society in 2001, and in 2012, it was included in the T.R.U.E. TEST allergen panel. T.R.U.E. TEST is a ready-to-use diagnostic test comprising 36 substances in 3 custom-prepared panels that provides the optimal allergen concentration in each of its patches. Consequently, since it first appeared, it has become increasingly used in dermatology departments, to the extent that it is now the standard series in many hospitals. The use of gold in patch tests is controversial. Its results are difficult to interpret, and, like many other metals, it is a common irritant. Consequently, it has been associated with late and persistent reactions (the possibility of active sensitization has even been considered). Furthermore, its relevance is difficult to identify, and the exact mechanisms by which this substance interacts with the human body remain unknown.<sup>1-8</sup>

The objective of the present study was to determine where GST ranks in the order of frequency of sensitizers causing positive results in patients seen in the contact allergy department. We also aimed to identify the demographic characteristics of patients who tested positive to GST, establish the relevance of the positive results, and define the usefulness of standardized patch testing with the allergen.

We performed an observational retrospective epidemiological study of all patients seen in the contact allergy

department of a tertiary hospital from January to June 2015. Of the 234 patients seen, 85 (36.32%) were excluded because either they had not undergone patch testing or the results of their patch tests were negative. The series used was the T.R.U.E. TEST. For all patients, the variables studied were as follows: age, sex, profession, known allergies, intolerance to metals, time since lesions first appeared, symptoms, location, patient's identification of contactant, presence of any other skin complaint, and frequency of positive results in the T.R.U.E. TEST. Data were processed and analyzed using SPSS version 11.5 for Windows (SPSS Inc). Qualitative variables were compared using the chi-square test with a Yates correction or the Fisher exact test when the conditions for applying the chi-square test could not be met.

The 5 most common allergens were nickel sulfate, GST, thiazolinones, fragrance mix, and paraphenylenediamine. A total of 35 patients (23.5%) tested positive for GST, which came second to nickel sulfate (55.7%) in the present series. Dermatitis affected the hands in 57.1% of cases. No significant differences were detected with respect to age, sex, profession, intolerance to metal, and known allergies. Of the patients who tested positive to GST, 82.9% could not identify a contactant ( $P = .012$ ). In addition, 17.1% were positive for GST only, whereas 99.1% of those who tested negative with GST were sensitized to  $\geq 2$  allergens ( $P = .001$ ). We cannot rule out differences with respect to co-occurrence with other skin complaints ( $P = .078$ ) (Table 1).

No contactant was identified in most of the GST-allergic patients. Many studies point to the ability of GST to cause irritation, persistent reaction, or even active sensitization. Although the dose used in the T.R.U.E. TEST series ( $75 \mu\text{g}/\text{cm}^2$ ) meets the criteria for the minimum concentration for a positive reaction (+ or ++), some patients were seen to react to low concentrations of GST but not to slightly higher concentrations; therefore, reactivity to GST could involve underlying factors other than the concentration (eg, interactions between local amino acids, pressure, friction, skin damage, and eczema). The North American Contact Dermatitis Group recently decided to remove gold from its standard series,<sup>1</sup> and the Spanish Contact Dermatitis and Skin Allergy Research Group does not include gold in its standard series. Therefore, we propose withdrawing GST from the widely used T.R.U.E. TEST series. Furthermore, patients who test positive to GST are sensitized to a single allergen more commonly than patients who are sensitized to allergens other than GST, and patients with a positive T.R.U.E. TEST result who test negative for GST were followed more frequently in the dermatology department for other skin complaints. This observation could be associated with the major presence of gold in many areas of our lives.

<sup>☆</sup> Please cite this article as: Arteaga-Henríquez M, Latour-Álvarez I, García-Peris E, Pérez-Robayna N. Estudio epidemiológico, observacional y retrospectivo de la sensibilización a tiosulfato sódico de oro en la consulta de alergias de contacto de un hospital de tercer nivel. *Actas Dermosifiliogr.* 2017;108:164–166.