

## Bullous Morphea: Description of a New Case and Discussion of Etiologic and Pathogenic Factors in Bulla Formation<sup>☆</sup>



### Un nuevo caso de morfea ampollosa y discusión de los factores etiopatogénicos en la formación de las ampollas

To the Editor:

Bullous morphea is a rare form of localized scleroderma. Since the description of the first case, numerous theories have been put forward on the origin of the blisters, but the actual mechanism by which they develop remains unclear.

Our patient, a 63-year-old woman, presented 2 lesions that had arisen some months earlier, localized symmetrically in the pretibial regions (Fig. 1). The lesions had an atrophic appearance, an erythematous base, and a central blister that contained a blood-stained fluid. The patient described no history of trauma.

Biopsy showed subepidermal separation with preservation of the basal layer. A mild inflammatory component and collagen fibrils were observed in the superficial dermis, but extensive sclerosis with a dense lymphocytic infiltrate was found in the reticular dermis and subcutaneous cellular tissue, though with no vasculitis or significant presence of eosinophils (Fig. 2). No lymphangiectasia was observed after staining with hematoxylin-eosin or D2-40 (Fig. 3). The findings were compatible with a diagnosis of bullous morphea. Blood tests were within normal limits and *Borrelia* serology was negative. Topical therapy with betamethasone and fusidic acid was started, leading to resolution of the blisters, but the sclerotic plaques deteriorated and systemic treatment was therefore commenced with oral methotrexate, achieving a good response.

Bullous morphea is a rare form of localized scleroderma.<sup>1</sup> The first case was described by Morrow in 1896.<sup>2</sup> Since that time, numerous theories on its origin have been proposed.<sup>3-5</sup>

The most widely accepted theory on the origin of the blisters has been lymphatic obstruction due to lymphangiectasia caused by the underlying sclerotic changes.<sup>1,3,5,6</sup> However, not all lesions of bullous morphea present lymphangiectasia on histology, nor do all cases of scleroderma with lymphangiectasia present blisters.<sup>1,4,7</sup>

Local trauma may be another etiologic and pathogenic factor, given the hemorrhagic content of some blisters and their frequent localization in areas of friction such as the legs and intertriginous areas.<sup>1,7,8</sup> No history of trauma was detected in our patient, but some findings, such as the localization of the blisters in the pretibial region, the blood-stained content, and the absence of other etiologic and pathogenic factors, could suggest that unperceived trauma may have played a role in the formation of the lesions.

Cases have been reported in which blisters developed as an isotopic or isomorphic response on residual lesions of herpes zoster or on the scars of previous surgery, trauma, injections, or radiation.<sup>1,6,8</sup> Some authors have suggested that eosinophils may play a role in this disease,<sup>5</sup> while other postulate reactive oxygen species as a possible causative factor.<sup>9</sup>

We have also found cases with 2 or more coexisting bullous diseases, such as pemphigus vulgaris, epidermolysis bullosa, and porphyria cutanea tarda; these diseases were ruled out in our patient.<sup>3,10</sup> Likewise, scleroderma-like changes are recognized in

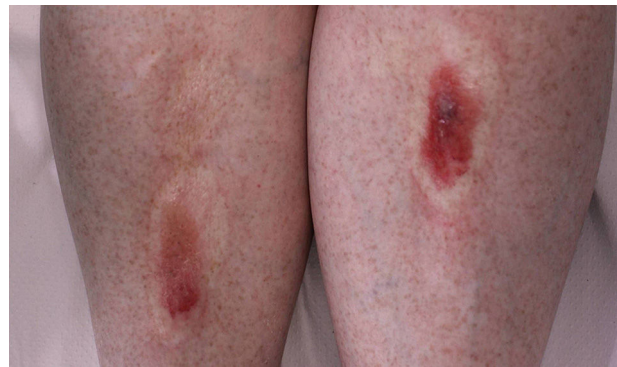

Figure 1 Bilateral atrophic plaques with overlying blisters.

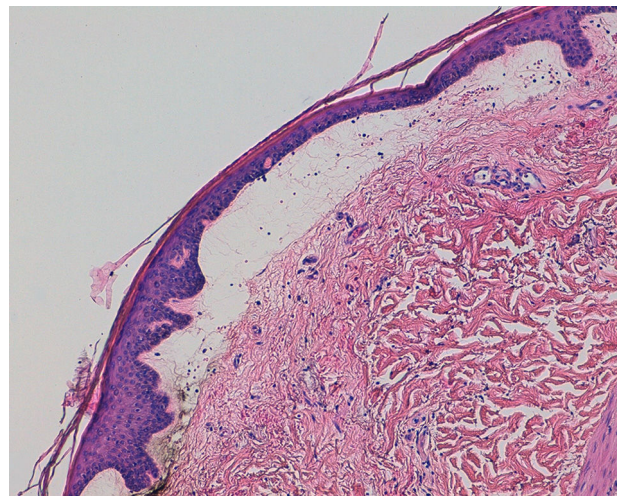


Figure 2 Subepidermal blister with preservation of the basal layer. Hematoxylin and eosin, original magnification  $\times 20$ .

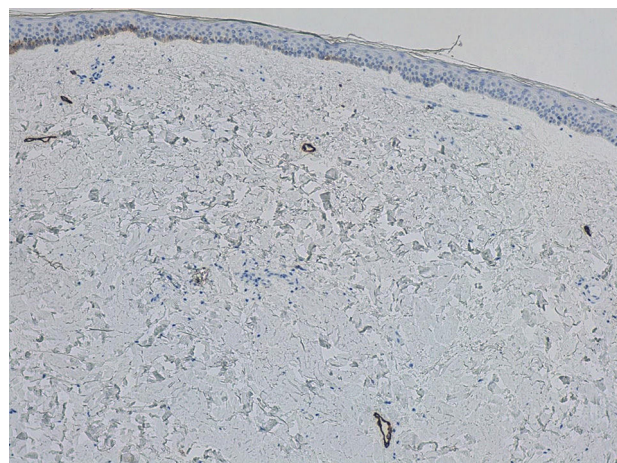


Figure 3 Lymph vessels of normal caliber. D2-40, original magnification  $\times 10$ .

patients with graft-versus-host disease, and the appearance of blisters on these lesions has also been reported.<sup>8</sup>

The diagnosis of bullous morphea requires a detailed medical history, full physical examination, skin biopsy with direct immunofluorescence, and blood tests including serology for *Borrelia* (typically negative) and autoimmunity.<sup>3-5</sup>

<sup>☆</sup> Please cite this article as: Sánchez-Pérez S, Escandell-González I, Pinazo-Canales MI, Jordá-Cuevas E. Un nuevo caso de morfea ampollosa y discusión de los factores etiopatogénicos en la formación de las ampollas. *Actas Dermosifiliogr.* 2017;108:75–76.

Histology reveals a greater or lesser degree of epidermal atrophy with flattening of the crests. The blisters are subepidermal, have a blood-stained content, and may be associated with edema of the papillary dermis.<sup>1,4,5</sup> In the reticular dermis there are prominent thick bundles of hyalinized collagen that destroy the adnexal structures.<sup>5</sup>

The main differential diagnosis of morphea is with lichen sclerosus et atrophicus, and the 2 diseases can coexist in some patients. In contrast to lichen sclerosus et atrophicus, the basal layer and the elastic fibers of the reticular dermis are unaffected in bullous morphea, which also does not show follicular plugs.<sup>4,7</sup>

Numerous therapeutic strategies have been used, including phototherapy, topical and systemic corticosteroids, topical vitamin D analogs, antimalarials, various immunosuppressant agents, systemic retinoids, certain antibiotics, colchicine, and phenytoin. Also, isolated cases have been treated with extracorporeal photophoresis, N-acetylcysteine, imiquimod, sulfasalazine, or skin grafts, with varying results.<sup>3-5,9</sup>

In conclusion, we have presented a case of bullous morphea in which lymphangiectasia was not detected on histology; this, together with the pretibial site of the lesions and their blood-stained content, leads us to speculate that unperceived trauma may have been the cause of the blisters in this case. Regarding treatment, it would appear reasonable to adopt an approach similar to that for nonbullous forms of morphea, starting with topical agents (corticosteroids, vitamin D analogs) or phototherapy, and advancing to systemic treatments such as methotrexate if no response is observed.

## Conflicts of Interest

The authors declare that they have no conflicts of interest.

## References

1. Fernández Flores A, Gatica Torres M, Tinoco Fragoso F, García Hidalgo F, García Hidalgo L, Monroy E, et al. Three cases of bullous morphea: Histopathologic findings with implications regarding pathogenesis. *J Cutan Pathol*. 2015;42:144–9.
2. Morrow PA. A case of symmetrical morphea attended with the formation of bullae and extensive ulceration. *J Cutan Genito-Urin Dis*. 1896;14:419–27.
3. Rencic A, Goyal S, Mofid M, Wigley F, Nousari HC. Bullous lesions in scleroderma. *Int J Dermatol*. 2002;41:335–9.
4. Yasar S, Mumcuoglu CT, Serdar ZA, Gunes P. A case of lichen sclerosus et atrophicus accompanying bullous morphea. *Ann Dermatol*. 2011;23:354–9.
5. Daoud MS, Su WP, Leiferman KM, Perniciaro C. Bullous morphea: Clinical, pathologic, and immunopathologic evaluation of thirteen cases. *J Am Acad Dermatol*. 1994;30:937–43.
6. Qu T, Fang K. Bullous morphea arising at the site of a healed herpes zoster. *J Dermatol*. 2014;41:553–4.
7. Kavala M, Zindaci I, Demirkesen C, Beyhan EK, Turkoglu Z. Intertriginous bullous morphea: A clue for the pathogenesis? *Indian J Dermatol Venereol Leprol*. 2007;73:262–4.
8. Grabbell D, Hsieh C, Andrew R, Martires K, Kim A, Vasquez R, et al. The role of skin trauma in the distribution of morphea lesions: A cross-sectional survey of the morphea in adults and children cohort IV. *J Am Acad Dermatol*. 2014;71:493–8.
9. Rosato E, Veneziano ML, di Mario A, Molinaro I, Pisarri S, Salsano F. Ulcers caused by bullous morphea: Successful therapy with N-acetylcysteine and topical wound care. *Int J Immunopathol Pharmacol*. 2013;26:259–62.
10. Bernstein JE, Nedenica M, Soltani K. Coexistence of localized bullous pemphigoid, morphea, and subcorneal pustulosis. *Arch Dermatol*. 1981;117:725–7.

S. Sánchez-Pérez,\* I. Escandell-González,  
M.I. Pinazo-Canales, E. Jordá-Cuevas

*Departamento de Dermatología, Hospital Clínico Universitario de Valencia, Valencia, Spain*

\* Corresponding author.

E-mail address: [ssanchez.derma@gmail.com](mailto:ssanchez.derma@gmail.com)  
(S. Sánchez-Pérez).

1578-2190/

© 2016 Elsevier España, S.L.U. and AEDV. All rights reserved.

## Amlodipine-Associated Photodistributed Telangiectasia<sup>☆</sup>



### Telangiectasias fotodistribuidas asociadas a amlodipino

To the Editor:

Telangiectasias due to drugs or iatrogenic damage are very rare. Some of the responsible drugs are lithium, interferon-alfa, and isotretinoin.<sup>1</sup> However, when telangiectasias appear in sun-exposed areas, they are usually related to the use of calcium channel blockers (CCB), although this has also been reported in association with other drugs such as venlafaxine and cefotaxime.<sup>2,3</sup>

In these cases, lesions appear in sun-exposed areas a few months after starting the treatment. The prognosis is good, as a correct

diagnosis followed by a change of treatment to a drug from another group, will lead to a rapid improvement and complete or almost complete disappearance of the lesions.

We present a patient with photodistributed telangiectasias associated with treatment with amlodipine. The lesions disappeared a few weeks after discontinuation of the treatment.

A 36-year-old woman consulted for the appearance of erythematous lesions that had arisen on the face and in the presternal region approximately 10 months earlier and for which she had received no treatment. A relevant finding in her past history was systemic hypertension on treatment with amlodipine for the previous year. She denied any history of rosacea or the use of topical corticosteroids. On examination, numerous erythematous-purpuric lesions and reticulated blood vessels were observed in the anterior thoracic region. All the lesions measured less than 1 cm in diameter and they blanched on pressure (Fig. 1). A few similar lesions were observed on the dorsum of the nose. Histology showed slight dilatation of the capillaries of the vascular plexus of the superficial dermis and a minimal lymphohistiocytic perivascular infiltrate; there were no signs of vasculitis and no increased presence of mast cells. Blood tests, including complete blood count, biochemistry, and basic autoimmune studies, were normal or negative.

<sup>☆</sup> Please cite this article as: Mora ER, Sánchez DM, Hernández-Núñez A, Martínez JB. Telangiectasias fotodistribuidas asociadas a amlodipino. *Actas Dermosifiliogr*. 2017;108:76–77.