

## Acral Peeling Skin Syndrome: A Case Report and Literature Review<sup>☆</sup>



### Síndrome de descamación de la piel acral: presentación de un caso y revisión bibliográfica

To the Editor:

Acral peeling skin syndrome (APSS) is a condition with autosomal dominant inheritance, caused by changes in gene *TG5*, responsible for the production of transglutaminase 5 (TG5).<sup>1</sup> It presents at birth or in early childhood with the formation of blisters and subsequent peeling on the palms and soles. As the disease has a low incidence and little or no clinical repercussion, it tends to be underdiagnosed or incorrectly diagnosed as epidermolysis bullosa simplex, with which it shares certain characteristics.<sup>2</sup>

We present the case of a 3-year-old boy who, since 6 months of age, presented blisters with subsequent peeling on the palms and soles and, to a lesser degree, on the dorsum of the hands and feet. The episodes were asymptomatic and occurred with a frequency of once or twice a month; humidity exacerbated the condition. On physical examination, the patient presented tense and flaccid blisters in pressure areas, associated with peeling on the palms and soles (Figs. 1 and 2) and resolving areas with residual erythema. The rest of the skin and the mucosas were normal. Skin biopsy showed slight separation between the granular and corneal layers, with no inflammation (Fig. 3). In the stratum corneum, the intermediate cell layers above the plane of cleavage presented an unstructured appearance, with large round cells. The clinical and histopathologic findings

were consistent with a diagnosis of APSS. Genetic analysis confirmed this hypothesis, as the patient presented 2 homozygous mutations of gene *TG5*: 1 pathogenic (P.G113C) and the other a polymorphism (P.T109H) frequently associated with the former.

APSS belongs to the group of peeling skin syndromes (PSS), which include a localized acral form (APSS) and a diffuse form.<sup>3-5</sup> APSS was first described as a specific entity in 1982 by Levy and Goldsmith.<sup>6</sup> Since that time, several individual case reports and case series of this syndrome have been published (Table 1). It is characterized by the formation of blisters and superficial peeling of the skin of the palms and soles, leaving a painless residual erythema that heals without scarring. The manifestations are exacerbated by humidity and by physical factors such as trauma or friction. In general, symptoms are absent or mild. In addition, APSS presents a number of histopathologic characteristics. The main finding is separation between the granular and corneal layers. Another common feature, observed in the stratum corneum above the plane of separation with the granular layer, is the presence of several layers of cells of atypical appearance: large, round, pale cells with an edematous and less compact appearance. Electron microscopy provides a better image of the separation between the corneocytes in these layers, with fragmentation of the keratin filaments.<sup>7,8</sup>

The underlying genetic mechanism was elucidated by Cassidy et al.<sup>1</sup> in 2005. Those authors identified the mutation responsible for the syndrome, localized in gene *TG5* on chromosome 15q15. This gene codes a protein, TG5, whose function is altered in the patients with this syndrome.

TG5 is expressed in the corneal layer and is responsible for the formation of crosslinks between key proteins in the cornification process (loricrin, involucrin, filaggrin, and others); it is also essential for maintenance of an intact corneal layer.<sup>1,4,8</sup> Analysis of healthy skin from individuals with APSS

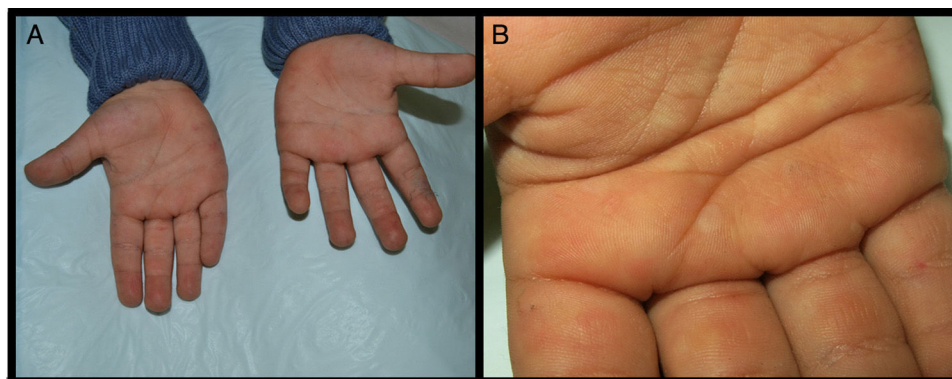
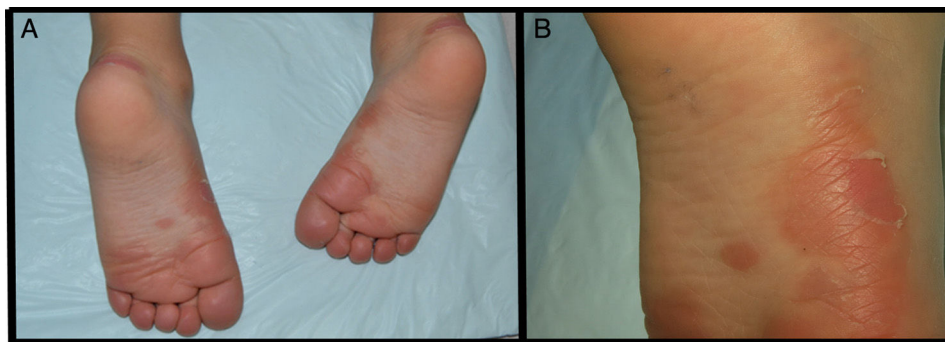
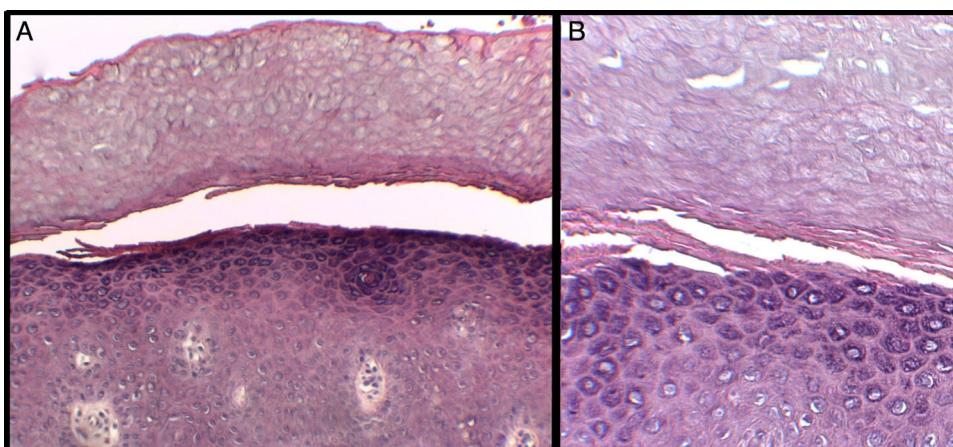


Figure 1 Blisters and areas of erythema on the palms. A, General view. B, Detail of the lesions.

<sup>☆</sup> Please cite this article as: Ruiz Rivero J, Campos Dominguez M, Parra Blanco V, Suárez Fernández R. Síndrome de descamación de la piel acral: presentación de un caso y revisión bibliográfica. *Actas Dermosifiliogr.* 2016;107:702-704.



**Figure 2** Blisters and peeling on the soles of the feet and in pressure areas. A, General view. B, Detail of the lesions.



**Figure 3** A, Separation between the corneal and granular layers of the epidermis. Hematoxylin and eosin (H&E), original magnification  $\times 10$ . B, Detail at higher magnification. Observe the appearance of the corneal layer above the plane of separation, with large round cells. H&E, original magnification  $\times 20$ .

**Table 1** Summary of the Most Relevant Findings of the Cases of APSS Published to Date.

Countries/regions reported	Germany, United Kingdom, The Netherlands, Poland, Italy, Spain, Russia, Hungary, Slovakia, Finland, Sweden, East Africa, Tunisia, Middle East, Morocco, and Jordan
Age at onset of symptoms	From birth to 11 years
Age at time of diagnosis	From 1 to 47 years
Most common signs	Blisters and peeling of palms and soles, and dorsum of hands and feet
Exacerbating factors	Humidity, sweating, heat, friction, and trauma
Mutations most frequently reported	p.[Gly113Cys];[Gly113Cys] Heterozygous p.[Gly113Cys] p.[Met1Thr];[Met1Thr] p.[Lys445Asn];[Lys445Asn] p.[Val273Met];[Val273Met] p.[Thr109His];[Thr109His]

Abbreviation: APSS, acral peeling skin syndrome.

shows that the mutation is not exclusive to the acral skin areas, but it is hypothesized that the other transglutaminases present in the skin, in different proportions depending on the site, are sufficient to complete the cornification process. The absence of TG5 action cannot be sufficiently compensated in the skin of the palms and soles, where the corneal layer is thicker and is subject to greater pressures.<sup>9</sup>

Two mutations have been described that, when homozygous, give rise to the syndrome. The first of these is mutation G113 C, which causes complete abolition of TG5 function. The other is T109M, which alone is not pathogenic, but is a polymorphism affecting the same allele, and that is frequently associated with the G113 C mutation. This combination has been described in various patients from northern

and central Europe, and it has been postulated that it is the result of a founder phenomenon in the European population. Fifty-nine cases with 15 new mutations affecting *TGM5* have recently been described,<sup>10</sup> as well as a mutation of the protein cystatin A, alterations of which also cause manifestations of APSS.

Treatment is symptomatic, with emollients and measures aimed at reducing maceration and trauma.

### Conflicts of Interest

The authors declare that they have no conflicts of interest.

### Acknowledgments

Ours thanks to Javier Cañueto Álvarez of the Dermatology Department of Universidad de Salamanca, to Rogelio González Sarmiento and Elena Bueno Martínez of the Department of Molecular Medicine of Universidad de Salamanca, and to Luis Carlos Sáez Martín of the Dermatology Department of Hospital General Universitario Gregorio Marañón, in Madrid, Spain.

### References

1. Cassidy AJ, van Steensel M, Steijlen PM, van Geel M, van der Velden J, Morley SM, et al. A homozygous missense mutation in *TGM5* abolishes epidermal transglutaminase 5 activity and causes acral peeling skin syndrome. *Am J Hum Genet.* 2005;77:909–17.
2. Kiritsi D, Cosgarea J, Franzke CW, Schumann H, Oji V, Kohlase J, et al. Acral peeling skin syndrome with *TGM5* gene mutations may resemble epidermolysis bullosa simplex in young individuals. *J Invest Dermatol.* 2010;130:1741–6.

3. Cabral RM, Kurban M, Wajid M, Shimomura Y, Petukhova L, Christiano AM. Whole-exome sequencing in a single proband reveals a mutation in the *CHST8* gene in autosomal recessive peeling skin syndrome. *Genomics.* 2012;99:202–8.
4. Bowden PE. Peeling skin syndrome: Genetic defects in late terminal differentiation of the epidermis. *J Invest Dermatol.* 2011;131:561–4.
5. Israeli S, Zamir H, Sarig O, Bergman R, Sprecher E. Inflammatory peeling skin syndrome caused by a mutation in *CDSN* encoding corneodermosin. *J Invest Dermatol.* 2011;131:779–81.
6. Levy SB, Goldsmith LA. The peeling skin syndrome. *J Am Acad Dermatol.* 1982;7:606–13.
7. Kiprono SK, Chaula BM, Naafs B, Masenga JE. Acral peeling skin syndrome in two East-African siblings: Case report. *BMC Dermatol.* 2012;12:2.
8. Pavlovic S, Krunic AL, Bulj TK, Medenica MM, Fong K, Arita K, et al. Acral peeling skin syndrome: A clinically and genetically heterogeneous disorder. *Pediatric Dermatol.* 2012;29:258–63.
9. Pigors M, Kiritsi D, Cobzaru C, Schwieger-Briel A, Suárez J, Faletra F, et al. *TGM5* mutations impact epidermal differentiation in acral peeling skin syndrome. *J Invest Dermatol.* 2012;132:2422–9.
10. Szczecinska W, Nesteruk D, Wertheim-Tysarowska K, Grrenblatt DT, Baty D, Browne F, et al. Under-recognition of acral peeling skin syndrome: 59 new cases with 15 novel mutations. *Br J Dermatol.* 2014;171:1206–10.

J. Ruiz Rivero,<sup>a,\*</sup> M. Campos Dominguez,<sup>a</sup>  
V. Parra Blanco,<sup>b</sup> R. Suárez Fernández<sup>a</sup>

<sup>a</sup> *Servicio de Dermatología Médico-Quirúrgica y Venereología, Hospital General Universitario Gregorio Marañón, Madrid, Spain*

<sup>b</sup> *Servicio de Anatomía Patológica, Hospital General Universitario Gregorio Marañón, Madrid, Spain*

\* Corresponding author.

E-mail address: [juncalrr@gmail.com](mailto:juncalrr@gmail.com) (J. Ruiz Rivero).

## Recurrent episodes of periorbital edema in an elderly woman



### Edema recidivante periorbitario en una anciana

Sra. Directora

An 81-year-old woman was referred for an edematous, erythematous plaque that had arisen 48 h earlier in the right periorbital region and on the ipsilateral side of the face. The lesions, present on both cheeks, initially had a papular-vesicular appearance, but they subsequently increased in size and became firm and tender and evolved rapidly into edematous plaques. The patient reported pruritus and fever of 38 °C. There was no history of insect bite, trauma, foreign travel, or gastrointestinal problems in the previous months. The patient was not taking any regular medication, including topical medication, at the time of onset of the lesions, nor did she use cosmetic preparations or contact lenses.

Three years earlier she had attended the infectious diseases department with a sore, pruritic erythematous plaque affecting the whole left side of the face, associated with fever. Antimicrobial therapy with intravenous amoxicillin plus clavulanic acid had been administered and the lesion

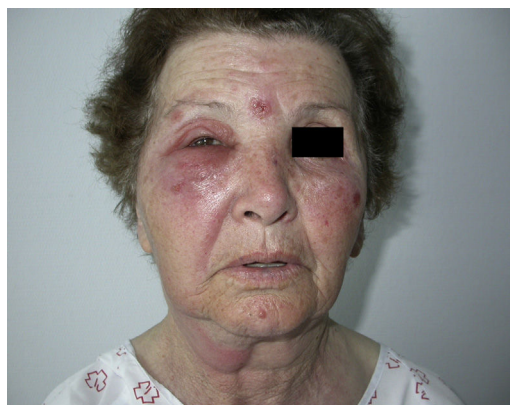

Figure 1 Edematous plaque on the right periorbital area.