

## Follicular Lichen Planus Caused by Wig Use: An Unusual Case of Koebner Phenomenon<sup>☆</sup>



### Liquen plano folicular causado por una peluca: fenómeno de Koebner inusual

To the Editor:

The scarring alopecias (SA) form a group of disorders that provoke permanent hair loss because of the substitution of hair follicles by fibrosis or hyalinized collagen.<sup>1</sup> The acquired forms can be caused by physical mechanisms, chemical trauma, skin infections, tumors, and other dermatoses such as chronic cutaneous lupus erythematosus or lichen planopilaris (LPP).<sup>2</sup>

Wigs can be used in the treatment of SA. Wigs are classified according to the type of hair and the method of fixation. Their disadvantages include hair rupture caused by the adhesives and traction by the fasteners.<sup>3,4</sup>

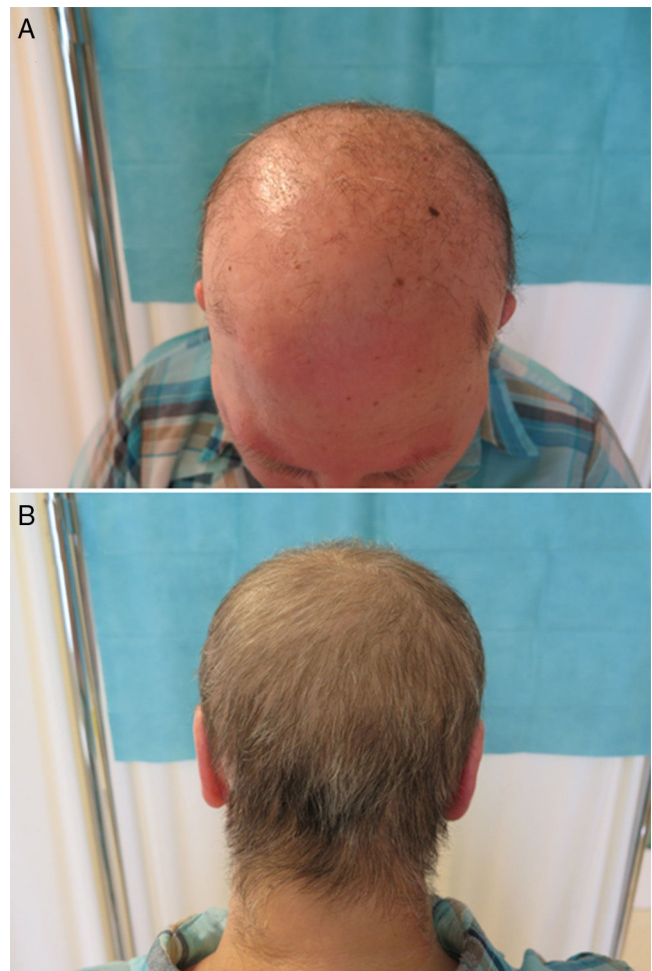
In this article we discuss the case of a 58-year-old woman with LPP of the scalp who developed plaques of SA after using a wig.

In her past history she reported hypertension and dyslipidemia and she had been followed up for years in the dermatology department for telogen effluvium, female-pattern androgenetic alopecia, and LPP (confirmed on biopsy). Nine months before the last follow-up consultation, the patient was diagnosed with infiltrating ductal carcinoma of the left breast, for which she received combined radiotherapy and chemotherapy with doxorubicin, cyclophosphamide, and fluorouracil; this produced anagen effluvium that had become repopulated by the time of consultation. The eyebrows were unaffected.

She came to the clinic wearing a wig. On removing the wig, we observed a pale skin with frontal and parietal alopecia, with persistence of a few isolated hairs and areas of follicular hyperkeratosis. Biopsy revealed areas of cicatricial fibrosis with an absence of hair follicles, and other areas with a dense perifollicular lichenoid infiltrate. The hair in the occipital region was preserved (Fig. 1).

Interestingly, there were 5 bilateral, symmetrical round plaques of alopecia in the midline frontal, temporal, and retroauricular regions. The dermoscopy image of the retroauricular area showed a loss of follicular orifices and mild erythema. Histopathology revealed preservation of isolated hair follicles with a lichenoid infiltrate and the substitution of other follicles by vertical tracts of scar tissue (Fig. 2).

The cause of these plaques of alopecia was the wig that the patient wore a minimum of 7 hours a day when working and, more specifically, the fasteners on the underside of the wig to fix it to the head (Fig. 3). As she no longer had sufficient hair to use the fasteners, she applied double-sided adhesive tape over them. When the position



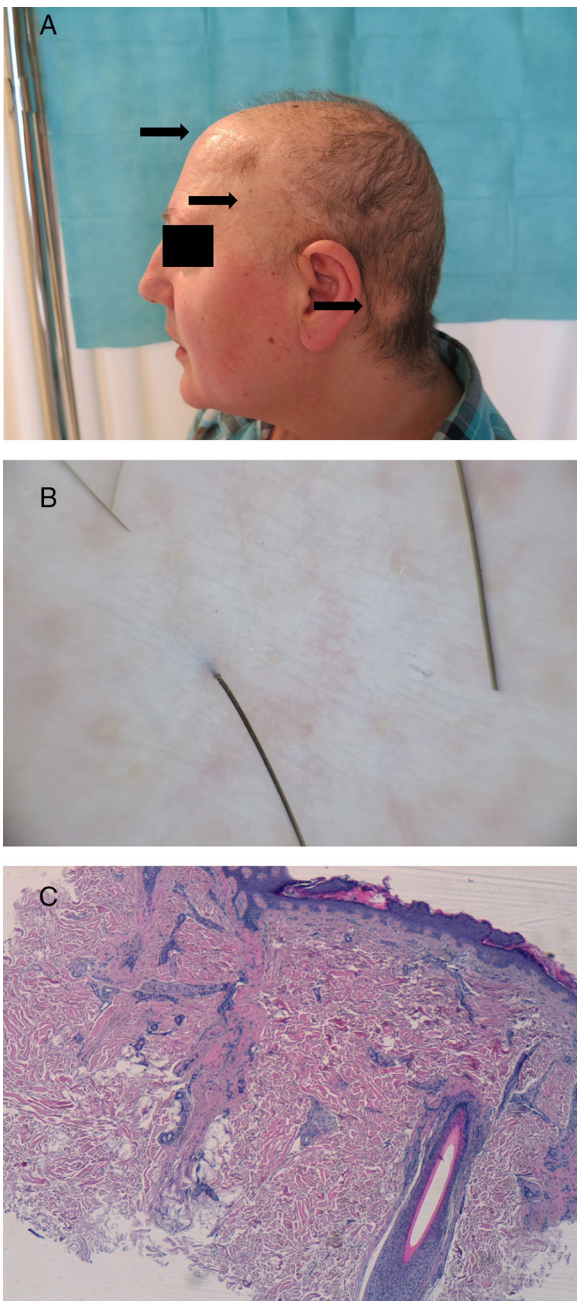
**Figure 1** A, Frontal and parietal alopecia, with isolated hairs and follicular hyperkeratosis. B, Persistence of hair in the occipital region.

of the fasteners was marked with a dermatographic pen, we found they coincided with the totally alopecic plaques in the midline frontal and right and left temporal and retroauricular regions. We made a diagnosis of acquired scarring alopecia secondary to LPP lesions (classic or its frontal fibrosing alopecia variant) that had developed as a Koebner phenomenon due to the pressure of the fasteners when the wig was being worn and due to traction when removing the adhesive tape.

The isomorphic or Koebner phenomenon consists of the appearance of typical lesions of a specific dermatosis in areas of healthy skin previously stimulated by various forms of trauma, such as friction, pressure, or traction. Only psoriasis, vitiligo, and lichen planus are included in the true Koebner phenomenon (category I).<sup>5</sup> LPP, a follicular form of lichen planus, is subdivided according to its clinical presentation into classic LPP, frontal fibrosing alopecia, and Graham-Little-Lassueur-Piccardi syndrome.<sup>1</sup> Some authors consider there to be a fourth variant whose pattern of distribution can mimic androgenetic alopecia.

The Koebner phenomenon has been described in both classic LPP and frontal fibrosing alopecia. Although LPP can occur after trauma, burns, radiotherapy, or performing break dancing, the majority of cases arise after hair

<sup>☆</sup> Please cite this article as: Monteagudo B, Vilas-Sueiro A, Cabanillas M, Durana C. Liquen plano folicular causado por una peluca: fenómeno de Koebner inusual. *Actas Dermosifiliogr*. 2016;107:438-440.



**Figure 2** A, Plaques of alopecia (arrows) in the midfrontal and left temporal and retroauricular areas. B, Dermoscopic image of retroauricular area. Loss of follicular orifices. C, Histology of a biopsy from the retroauricular area. A preserved hair follicle with a lichenoid infiltrate and vertical tract of scar-tissue left by the destruction of a follicle. Hematoxylin and eosin, original magnification  $\times 4$ ).

transplant. According to some authors, many patients who develop LPP after hair transplant in the context of androgenetic alopecia actually previously had LPP incorrectly diagnosed as seborrheic dermatitis or folliculitis. It must be noted that active LPP is a contraindication to performing hair transplant.<sup>6,7</sup>

The following differential diagnoses should be considered:



**Figure 3** The underside of the wig with 5 fasteners.

1. Pressure alopecia, a disorder that may or may not involve scarring. Several types exist, some very common, such as postoperative alopecia after long operations and antero-lateral leg alopecia caused by friction with socks and trousers, and other rarer forms, such as alopecia after resting the head for many hours watching television or annular alopecia of the newborn due to pressure against the mother's pelvis.<sup>2,8,9</sup>
2. Alopecia areata, an entity in which the rapid appearance of new plaques (in 1 to 7 days) has been reported as a result of a Koebner phenomenon caused by traction on a hairy perilesional area to obtain hairs for a trichogram.<sup>10</sup>

In conclusion, very few articles have described the Koebner phenomenon in LPP. We consider this report interesting as it describes the case of a woman with LPP who developed localized plaques of SA affecting only the areas of pressure of the fasteners used to hold her wig in place. We have found no previous reports of this association in the literature.

**Conflicts of Interest**

The authors declare that they have no conflicts of interest.

**References**

1. Bernárdez C, Molina-Ruiz AM, Requena L. Histopatología de las alopecias. Parte II: Alopecias cicatriciales. *Actas Dermosifiliogr.* 2015;106:260-70.

2. Camacho FM. Alopecias cicatriciales adquiridas. In: Camacho FM, Tosti A, editors. *Tricología. Enfermedades del folículo pilosebáceo*. Grupo Aula Médica; 2013. p. 1001–12.
  3. Banka N, Bunagan MJ, Dubrule Y, Shapiro J. Wigs and hair-pieces: Evaluating dermatologic issues. *Dermatol Ther*. 2012;25:260–6.
  4. Torchia D, Giorgini S, Gola M, Francalanci S. Allergic contact dermatitis from 2-ethylhexyl acrylate contained in a wig-fixing adhesive tape and its 'incidental' therapeutic effect on alopecia areata. *Contact Dermatitis*. 2008;58:170–1.
  5. Sagi L, Trau H. The Koebner phenomenon. *Clin Dermatol*. 2011;29:231–6.
  6. Donovan J. Lichen planopilaris after hair transplantation: Report of 17 cases. *Dermatol Surg*. 2012;38:1998–2004.
  7. Monselise A, Chan LJ, Shapiro J. Break dancing: A new risk factor for scarring hair loss. *J Cutan Med Surg*. 2011;15:177–9.
  8. Ozdemir EE, Güleç AT. Clinical evaluation of postoperative pressure-induced alopecia using a hand-held dermatoscope. *Int J Dermatol*. 2014;53:e309–10.
  9. Thiem A, Kütt S, Hamm H. 'Television alopecia': a rare cause of pressure alopecia. *J Eur Acad Dermatol Venereol*. 2014; doi: 10.1111/jdv.12893. [Epub ahead of print].
  10. D'Ovidio R. Koebner phenomenon in alopecia areata: Rapid appearance after trichogram. Implications for the pathogenesis and therapy. *G Ital Dermatol Venereol*. 2013;148:225–9.
- B. Monteagudo,<sup>a,\*</sup> A. Vilas-Sueiro,<sup>a</sup> M. Cabanillas,<sup>a</sup>  
C. Durana<sup>b</sup>
- <sup>a</sup> *Servicio de Dermatología, Complejo Hospitalario Universitario de Ferrol, Área Sanitaria de Ferrol, SERGAS, Ferrol, A Coruña, Spain*  
<sup>b</sup> *Servicio de Anatomía Patológica, Complejo Hospitalario Universitario de Ferrol, Área Sanitaria de Ferrol, SERGAS, Ferrol, A Coruña, Spain*
- \* Corresponding author.  
E-mail address: [benigno.monteagudo.sanchez@sergas.es](mailto:benigno.monteagudo.sanchez@sergas.es) (B. Monteagudo).

## Evaluation of Collision Tumors by Confocal Microscopy<sup>☆</sup>



### Tumores de colisión valorados por microscopía confocal

To the Editor:

Collision tumors are common in daily clinical practice, but diagnosis can be difficult. Dermoscopy and confocal microscopy are 2 noninvasive techniques that are very helpful in this type of lesion. We describe 2 cases in which the dermoscopic suspicion of a collision tumor was confirmed by confocal microscopy.

#### Case 1

A woman aged 51 years presented a macular lesion on her abdomen; she was uncertain how long the lesion had been present. Dermoscopy revealed a network pattern. In addition, there were several small round areas with comedo-like openings on dermoscopy (Fig. 1A).

Confocal microscopy showed a cobblestone pattern of the epidermis and a ring pattern at the dermoepidermal junction. Several areas with bright (hyperreflective) annular structures (with an onion skin appearance) and polycyclic cords were also visible (Fig. 1B). Histology revealed a collision tumor between a junctional melanocytic nevus and a seborrheic keratosis (Fig. 1C).

<sup>☆</sup> Please cite this article as: Armada LA, Villegas RG, Franco AP, Moraleda FP. Evaluation of Collision Tumors by Confocal Microscopy. *Actas Dermosifiliogr*. 2016;107:440–442.

#### Case 2

This patient was a 49-year-old man with a history of superficial spreading melanoma excised in 2011. Follow-up using digital dermoscopy revealed growth of a pigmented lesion on his back. The lesion was a pigmented macule measuring 0.6 cm in diameter. Dermoscopy revealed a homogeneous globular network pattern with asymmetric globules peripherally. An area of the lesion presented milia-like cysts and comedo-like openings (Fig. 2A).

A honeycomb pattern was observed in the epidermis and ring-like structures at the dermoepidermal junction, with occasional areas of crest fusion. In addition, a ring of bright (hyperreflective) structures (comedo-like openings on dermoscopy) and hyperreflective round intraepithelial structures with a smooth outline (milia-like cysts on dermoscopy) were observed (Fig. 2B).

Histology revealed collision between a compound melanocytic nevus with distorted architecture but no atypia, and a seborrheic keratosis (Fig. 2C).

The term collision tumor is used to refer to the presence of 2 or more different tumors in a single lesion.<sup>1</sup> Clinical diagnosis can be difficult (particularly when the collision is between a malignant and a benign tumor), and dermoscopy and confocal microscopy are very useful diagnostic tools. When the collision is between 2 benign tumors, very good concordance is achieved between dermoscopy, confocal microscopy, and histology.<sup>2</sup> However, in the cases presented, although both lesions appeared benign on confocal microscopy, they were excised for histologic confirmation of the suspected diagnosis.

The association of seborrheic keratosis with melanocytic nevus is not uncommon. In a retrospective study published