

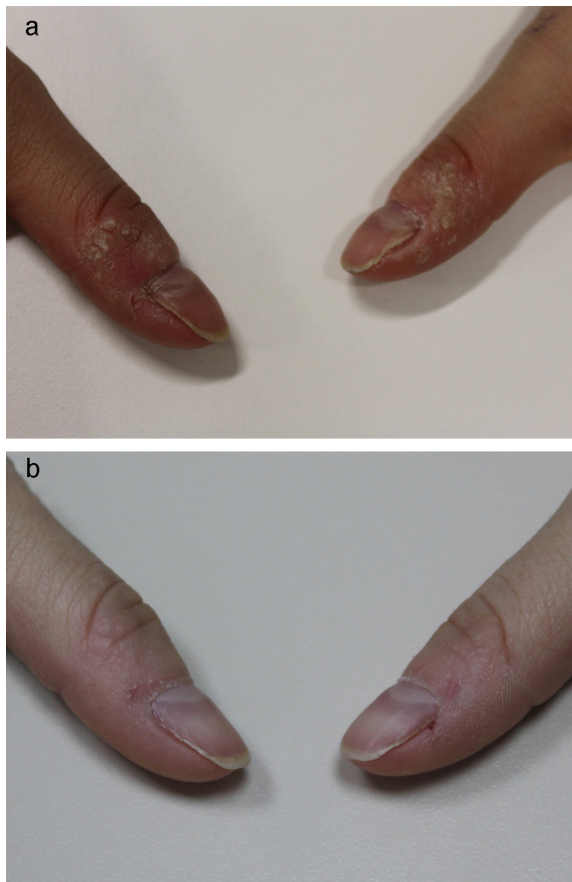Figure 2 A. Periungual warts on several fingers, before treatment. B, Resolution of lesions after treatment.

References

1. López-Giménez MT. Tratamiento eficiente de 5 casos de verrugas plantares recalcitrantes con imiquimod 5%. *Actas Dermosifiliogr.* 2013;104:640–2.
2. Housman TS, Jorizzo JL. Anecdotal reports of 3 cases illustrating a spectrum of resistant common warts treated with cryotherapy

- followed by topical imiquimod and salicylic acid. *J Am Acad Dermatol.* 2002;47:S217–20.
3. Schroeter CA, Kaas L, Waterval JJ, Bos PM, Neumann HA. Successful treatment of periungual warts using photodynamic therapy: A pilot study. *J Eur Acad Dermatol Venereol.* 2007;21:1170–4.
4. Wang YS, Tay YK, Kwok C, Tan E. Photodynamic therapy with 20% aminolevulinic acid for the treatment of recalcitrant viral warts in an Asian population. *Int J Dermatol.* 2007;46:1180–4.
5. Stockfleth E, Beti H, Orasan R, Grigorian F, Mescheder A, Tawfik H, et al. Topical polyphenon E in the treatment of external genital and perianal warts: A randomized controlled trial. *Br J Dermatol.* 2008;158:1329–38.
6. Tzellos TG, Sardeli C, Lallas A, Papazisis G, Chourdakis M, Kouvelas D. Efficacy, safety and tolerability of green tea catechins in the treatment of external anogenital warts: A systematic review and meta-analysis. *J Eur Acad Dermatol Venereol.* 2011;25:345–53.
7. Muñoz-Santos C, Pigem R, Alsina M. Nuevos tratamientos en la infección por virus del papiloma humano. *Actas Dermosifiliogr.* 2013;104:883–9.
8. Tatti S, Swinehart JM, Thielert C, Tawfik H, Mescheder A, Beutner KR. Sinocatechins, a defined green tea extract, in the treatment of external anogenital warts: A randomized controlled trial. *Obstet Gynecol.* 2008;111:1371–9.
9. Gross G, Meyer KG, Pres H, Thielert C, Tawfik H, Mescheder A. A randomized, double-blind, fourarm parallel-group, placebo-controlled phase II/III study to investigate the clinical efficacy of two galenic formulations of polyphenon E in the treatment of external genital warts. *J Eur Acad Dermatol Venereol.* 2007;21:1404–12.
10. Clouth A, Schöfer H. Treatment of recalcitrant facial verrucae vulgares with sinocatechins (green tea catechins) ointment. *J Eur Acad Dermatol Venereol.* 2013;29:178–9.

J. Alcántara González,* L. Pérez Carmona,
M. Ruano del Salado, L. Calzado Villarreal

Servicio de Dermatología, Hospital Universitario de Torrejón, Madrid, Spain

* Corresponding author.

E-mail address: jalcantarag@hotmail.es
(J. Alcántara González).

<http://dx.doi.org/10.1016/j.adengl.2014.12.005>

Effectiveness of Extracorporeal Shock Wave Lithotripsy to Treat Dystrophic Calcinosis Cutis Ulcers[☆]



Eficacia del tratamiento con ondas de choque en las úlceras por calcinosis distrófica

We report the case of a 78-year-old woman with a history of hypertension, deep vein thrombosis, valvular heart

[☆] Please cite this article as: Delgado-Márquez AM, Carmona M, Vanaclocha F, Postigo C. Eficacia del tratamiento con ondas de choque en las úlceras por calcinosis distrófica. *Actas Dermosifiliogr.* 2015;106:140–143.

disease treated with coumarin, osteoporosis, and overlap syndrome. In addition, she had diagnostic findings consistent with systemic lupus erythematosus (pleuropericarditis, lupus erythematosus panniculitis, subacute cutaneous lupus erythematosus, malar rash, oral ulcers, arthritis, leukopenia and thrombocytopenia, meningitis, and positive tests for antinuclear antibodies and antiribonucleoprotein antibodies) as well as with scleroderma (sclerodactyly, severe Raynaud syndrome, esophageal disease, interstitial pulmonary disease, and a positive test for anticentromere antibodies). The patient presented to our dermatology service in 2002 because of bouts of erythema and pain in her right leg. Biopsy findings at that time were reported as consistent with lupus erythematosus panniculitis and dermal sclerosis. In 2008 she began to develop ulcers above

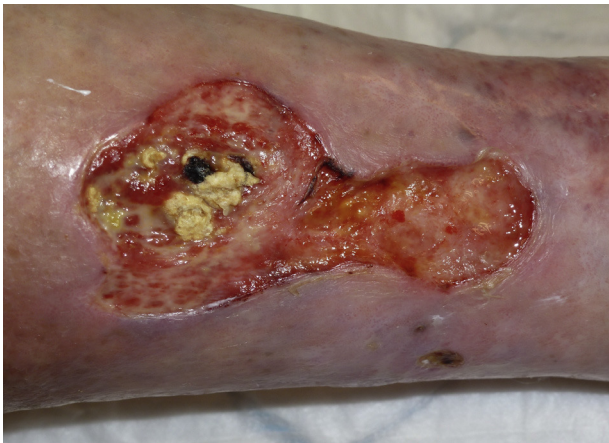

Figure 1 Right supramalleolar ulcer with extrusion of calcified material, prior to shock wave therapy. Largest diameter was 8 cm, proximal width was 4.5 cm, and distal width was 2.5 cm.

the malleoli of her right leg. The lesions were very painful and frequently infected. Results of another biopsy, performed in 2009, were consistent with calcified scleroderma. The patient's calcium-phosphorus product was normal, and a radiograph of her leg revealed subcutaneous calcification. All these findings were consistent with dystrophic calcification. We initially treated the patient with oral corticosteroids, with courses of antibiotics added whenever infection occurred.

In November 2009, we began treatment with bosentan, but discontinued treatment owing to poor tolerance. In December 2009 we began topical treatment with sodium thiosulfate and acetic acid. The patient's condition initially improved, and *Pseudomonas* infections stopped. Between January and June 2010, we added sildenafil to treat the patient for digital ulcers, which resolved. The leg ulcer secondary to dystrophic calcification remained unaltered. In June 2010, the patient's calcified deposits were excised and the defect was covered with a skin graft. The ulcer recurred 4 months later and diltiazem was prescribed. Initial improvement was considerable, but a subsequent recurrence failed to respond both to doxycycline and to several courses of corticosteroids.

Owing to this poor response, in July 2012 we decided to start treatment in our rehabilitation service using unfocused shock waves at an intensity of 0.1 mJ/mm² and a frequency of 360 pulses per minute, with 550 pulses administered to the proximal area and 400 to the distal area. Slight adjustments were made as the size of the ulcer changed. Sessions lasted approximately 5 minutes each and were conducted every 2 weeks. The patient tolerated this treatment very well and experienced no adverse effects. Her symptoms improved considerably from the first session onwards; pain was reduced and lesions became progressively smaller until they were practically epithelialized (Figs. 1 and 2).

Dystrophic calcification is the term used for the formation of insoluble calcified deposits in the skin and soft tissues (calcinosis cutis) owing to tissue damage in individuals with normal calcium and phosphorus serum levels.¹ It is frequently, but not exclusively, associated with autoimmune diseases of connective tissue, particularly dermatomyositis

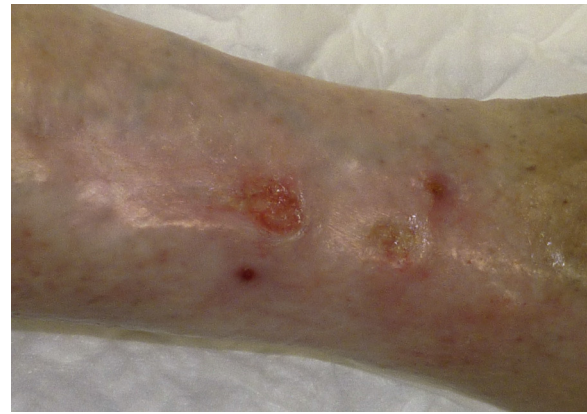

Figure 2 Leg ulcer region after 27 shock wave therapy sessions comprises a proximal ulcer measuring 1.2 × 0.9 cm and a distal ulcer measuring 0.8 × 0.8 cm.

(20%-70%) and the localized form of systemic scleroderma (25%), in which it occurs in the areas most severely affected by sclerosis and ischemia.² It is also a typical finding in biopsies for long-standing lupus erythematosus panniculitis.³

Manifestations range from radiologic findings to highly painful chronic nodules and ulcers that frequently become infected and impair quality of life. These ulcers are challenging to manage, and no treatment has yet been shown to be universally effective. Treatments attempted include antiinflammatory intralesional corticosteroids, calcium antagonists (diltiazem), colchicine, minocycline, bisphosphonates, warfarin, intravenous immunoglobulin, probenecid, aluminum hydroxide, ceftriaxone, topical sodium thiosulfate, surgery, and erbium:YAG or carbon dioxide laser therapy.⁴

Extracorporeal shock waves have been used in urology since 1980 and in trauma and orthopedics since 1988. Calcific tendinitis of the shoulder is one of the indications. Shock wave treatment consists of high-pressure acoustic pulses generated with an impulse faster than the speed at which the sound waves propagate within a given medium; this generally involves an electric discharge in a watery medium. Several types of reflector focus the waves according to the treatment objective, giving rise to either high-density focused wave fronts (for calculi) or low-density unfocused wave fronts (for soft tissue).⁵ Low-density waves act on cell-surface mechanoreceptors and activate angiogenesis as well as the migration and differentiation of cells with high regenerative potential. They also stimulate sensory nerve fibers and nociceptors, a fact that may explain their analgesic effect.⁶

Our literature searches have found 9 published cases of patients with ulcers secondary to dystrophic calcification who were treated with focused waves (for calculi)^{7,8}: 4 had chronic venous insufficiency, 4 had scleroderma, and 1 had dermatomyositis. Additionally, there was 1 patient who had dermatomyositis but no ulcers.⁹ All these patients experienced significant decreases in ulcer size and pain after 2 to 3 sessions, across all conditions.

In our patient's case we opted for unfocused low-density waves using equipment designed for soft tissue.¹⁰ This ther-

Table 1 Published Uses of Shock Waves to Heal Ulcers^a

Author	Condition	No. of Ulcers	Shock wave therapy	Complete healing (%)	Remarks	
Schaden et al., 2007	Anomalous healing	82		75.6		
	Necrosis of traumatic lesions	67		86.6		
	Venous stasis	25	Unfocused	36		
	Decubitus ulcers	14	ED: 0.1 mJ/mm ²	71.4	1/3 were acute ulcers. No long-term follow-up.	
	Other pressure ulcers	7	Pulse no.: 100/cm ²	85.7		
	Arterial insufficiency	6	Frequency: 5 Hz	66.7		
	Burns	7		100		
	Total	208		75		
Saggini et al., 2008	Venous ulcers	12	Focused	36		Only 1/10 of control group ulcers healed. Wound size was reduced in every case and pain was significantly diminished.
	Traumatic wound ulcers	16	ED: 0.037 mJ/mm ²	69		
	Diabetic ulcers	4	Pulse no.: 100/cm ²	25		
Moretti et al., 2009	Total	32	Frequency: 4 Hz	50	Healing was faster than in the control group.	
	Plantar diabetic ulcers	30	Unfocused	53.35		
Wang et al., 2009	Plantar diabetic ulcers	36	ED: 0.03 mJ/mm ² Pulse no.: 100/cm ² Frequency: NA Focused	31	22% healing rate in hyperbaric chamber.	
			ED: 0.11 mJ/mm ² Pulse no.: 100/cm ² Frequency: NA Unfocused	100		
Ottoman et al., 2010	Full-thickness skin graft donor areas	28	ED: 0.1 mJ/mm ² Pulse no.: 100/cm ² Frequency: NA	80	Healing was faster than in the control group.	
Arno et al., 2010	Burns	15	ED: 0.15 mJ/mm ² Pulse no.: 500/cm ² Frequency: NA	80	No control group.	
Larking et al., 2010	Decubitus ulcers	9	Unfocused	55.5	Crossover design. Shock wave therapy was superior.	
			ED: 0.1 mJ/mm ² Pulse no.: 200 + 100/cm ² Frequency: 5 Hz			

Abbreviations: ED, energy density; NA, not available.

^a Adapted from Mittermayr et al.⁵

apy has been used for different types of ulcers since 2007, with promising results (Table 1).⁵

To our knowledge, ours is the first case of an ulcer caused by dystrophic calcification and treated using unfocused shock waves, with excellent results. We wish to highlight the effectiveness of this treatment in terms of pain reduction and epithelialization, and underscore its ease of application, safety, and tolerability.

References

- Gutiérrez A, Wetter D. Calcinosis cutis in autoimmune connective tissue diseases. *Dermatol Ther.* 2012;25:195–206.
- Balin SJ, Wetter DA, Andersen LK, Davis MD. Calcinosis cutis occurring in association with autoimmune connective tissue disease: The Mayo Clinic experience with 78 patients, 1996–2009. *Arch Dermatol.* 2012;148:455–62.
- Requena L, Sánchez-Yus E, Part II. Panniculitis. Mostly lobular panniculitis. *J Am Acad Dermatol.* 2001;45:325–61.
- Reiter N, El-Shabrawi L, Leinweber B, Berghoid A, Aberer E. Calcinosis cutis: Part II treatment options. *J Am Acad Dermatol.* 2011;65:15–22.
- Mittermayr R, Antonic V, Hartinger J, Kaufmann H, Redl H, Téot L, et al. Extracorporeal shock wave therapy (ESWT) for wound healing: Technology, mechanisms, and clinical efficacy. *Wound Rep Reg.* 2012;20:456–65.
- Qureshi AA, Kimberly BS, Ross M, Rei BA, Orgill D. Shock wave therapy in wound healing. *Plast Reconstr Surg.* 2011;128:721–7.

7. Sparsa A, Lesaux N, Kessier E, Bonnetblanc JM, Blaise S, Lebrun-Ly V, et al. Treatment of cutaneous calcinosis in CREST syndrome by extracorporeal shock wave lithotripsy. *J Am Acad Dermatol*. 2005;53:263–5.
8. Sultan-Bichat N, Menard J, Perceau G, Staerman F, Bernard P, Reguiat Z. Treatment of calcinosis cutis by extracorporeal shock-wave lithotripsy. *J Am Acad Dermatol*. 2012;66:424–9.
9. Chan AY, Li E. Electric shock wave lithotripsy (ESWL) as a pain control measure in dermatomyositis with calcinosis cutis—old method, new discovery. *Clin Rheumatol*. 2005;24:172–3.
10. Schaden W, Thiele R, Köpl C, Pusch M, Nissan A, Attinger C, et al. Shock wave therapy for acute and chronic soft tissue wounds: A feasibility study. *J Surg Res*. 2007;143:1–12.

A.M. Delgado-Márquez,^{a,*} M. Carmona,^b F. Vanaclocha,^a C. Postigo^a

^a *Departamento de Dermatología, Hospital 12 de Octubre, Madrid, Spain*

^b *Departamento de Rehabilitación, Hospital 12 de Octubre, Madrid, Spain*

*Corresponding author.

E-mail address: anadelgadam13@gmail.com (A.M. Delgado-Márquez).

<http://dx.doi.org/10.1016/j.adengl.2014.12.004>

Small-Cell Neuroendocrine Carcinoma, Not Merkel Cell Carcinoma, in the Sinonasal Region: A Case Report[☆]



Carcinoma neuroendocrino de células pequeñas de la región nasosinusal no carcinoma de células de Merkel: presentación de un caso

Small-cell neuroendocrine carcinoma (SCNC) in the sinonasal region is a relatively rare, aggressive tumor with a high rate of recurrence and metastasis. It was first described in 1965 by Raychowdhuri¹ and approximately 50 cases have been published since that time. The majority of SCNCs affect the lungs and only around 4% are located at other sites.²

We present the case of a 32-year-old woman with no past history of interest. She consulted for progressively increasing pain and inflammation on the dorsum of the nose that

had started 2 months earlier. Physical examination revealed a solid, fixed nodule with a smooth surface on the right lateral surface of the dorsum of the nose. The nodule measured approximately 3 cm in its longest diameter (Figure 1); in addition, there was a palpable right jugulodigastric lymph node. Magnetic resonance imaging of the paranasal sinuses revealed a nodular lesion of the external nose that eroded the right nasal bones. On skin biopsy, a diffuse infiltration of neoplastic cells was observed in the deep dermis, hypodermis, and muscle layer. The cells were small and round, with scant cytoplasm and basophilic nuclei (Figure 2A and B). Immunohistochemistry (Figure 3) showed a phenotypic profile positive for neuroendocrine (chromogranin A and CD56) and epithelial (cytokeratin AE1/AE3) markers and for thyroid transcription factor 1 (TTF-1) and negative for cytokeratin 20 (CK20), cytokeratin 7 (CK7), protein S-100, glial fibrillary acidic protein (GFAP), neurofilaments, and Epstein Barr virus (EBV) antigen. The cervical lymph node was biopsied and the histologic and immunohistochemical findings were consistent with SCNC arising from the seromu-

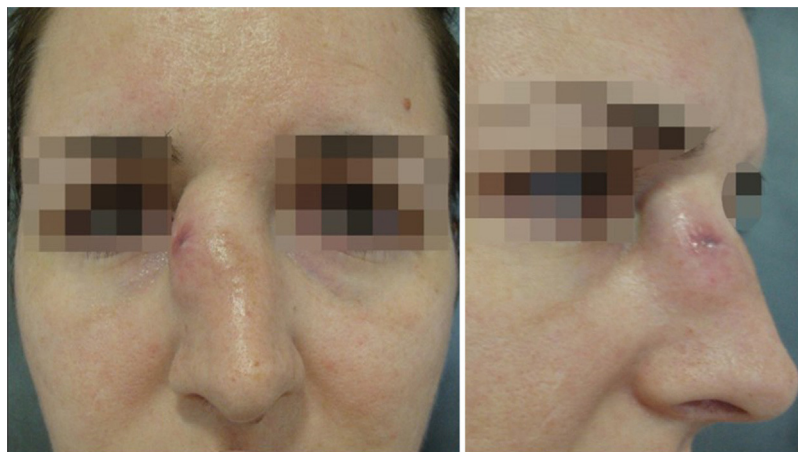


Figure 1 A solid nodule with a smooth surface and irregular outline on the right lateral surface of the dorsum of the nose.

[☆] Please cite this article as: Rivas-Tolosa N, Llombart B, Traves V, Guillén C. Carcinoma neuroendocrino de células pequeñas de la región nasosinusal no carcinoma de células de Merkel: presentación de un caso. *Actas Dermosifiliogr*. 2015;106:143–145.