


ACTAS Derma-Sifiliográficas

Full English text available at
www.actasdermo.org



CASE AND RESEARCH LETTERS

Dermatomyositis-Like Eruption Associated With Hydroxyurea Therapy: A Premalignant Condition?☆



Erupción dermatomiositis-like asociada al tratamiento con hidroxiurea: ¿una entidad premaligna?

Hydroxyurea (HU) is an anticancer agent that inhibits DNA synthesis through its action on the enzyme ribonucleotide reductase.¹ It is used in chronic myeloproliferative diseases such as polycythemia vera, chronic myeloid leukemia, and essential thrombocytosis, although it has also been prescribed to patients with refractory psoriasis.²

We present the case of a 76-year-old woman diagnosed with idiopathic myelofibrosis and on treatment with

HU since 2004. Four years after starting treatment with HU, the patient consulted for desquamating erythematous plaques over the interphalangeal joints, periorbital erythema, and erythematous papular lesions in the frontal (Fig. 1A) and retroauricular (Fig. 1B) regions. In addition, she had a painful ulcer of approximately 3 cm diameter over the medial malleolus; the ulcer had a whitish base and was surrounded by atrophic erythematous skin. She did not report muscle weakness or dysphagia. Laboratory tests including muscle enzymes, acute phase reactants, and autoantibodies were normal. A biopsy taken from the dorsum of the hand revealed an acanthotic epidermis with hyperkeratosis, dyskeratosis, and vacuolization of the basal layer, associated with a lichenoid inflammatory infiltrate at the dermoepidermal interface. Additionally, the epidermis showed keratinocyte disorganization and atypia with large nuclei (Fig. 2A). On immunohistochemistry there was intense expression of p53 in the dysplastic keratinocytes (Fig. 2B).

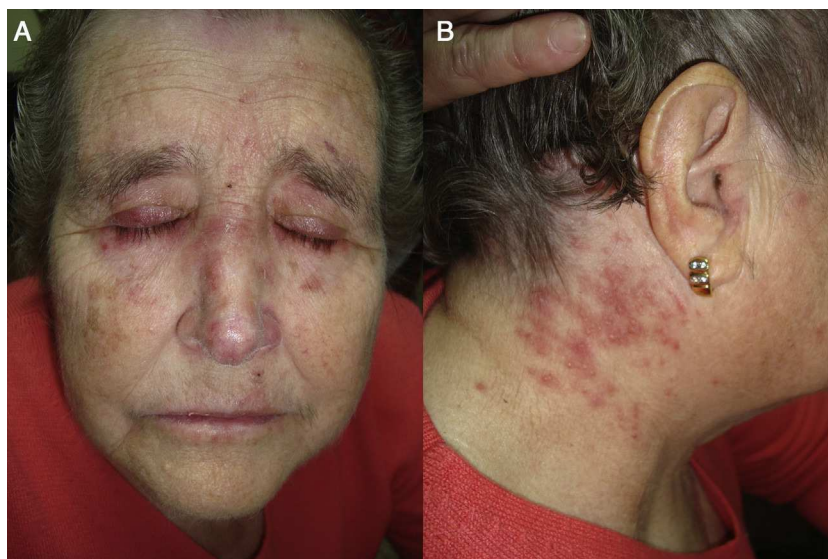

Figure 1 A, Desquamating erythematous lesions in the periorbital region. B, Erythematous papular lesions in the retroauricular region.

☆ Please cite this article as: de Unamuno-Bustos B, Ballester-Sánchez R, Sabater Marco V, Vilata-Corell JJ. Erupción dermatomiositis-like asociada al tratamiento con hidroxiurea: ¿una entidad premaligna?. Actas Dermosifiliogr. 2014;105:876–878.

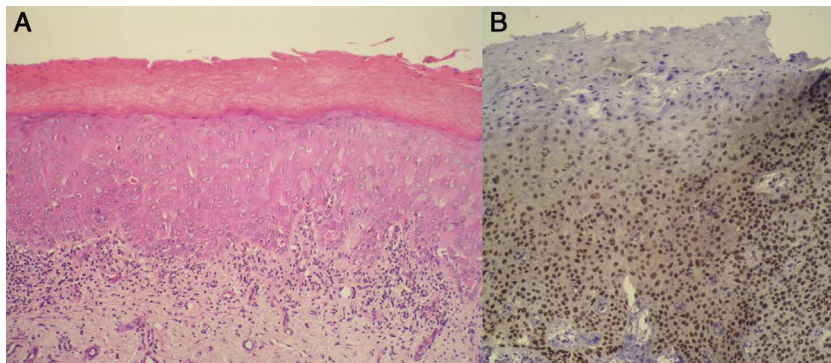


Figure 2 A, Hyperkeratosis, acanthosis, dyskeratosis, and vacuolization of the basal layer, associated with a lichenoid inflammatory infiltrate at the dermoepidermal interface. Keratinocyte disorganization and atypia are also visible. B, Intense expression of p53 in the dysplastic keratinocytes.

These clinical and pathologic findings were consistent with a dermatomyositis (DM) like rash and squamous dysplasia associated with treatment with HU. It was decided to change the treatment to anagrelide, and a clear improvement of the skin lesions was observed at 10 months (Fig. 3). The patient remains on periodic follow-up in dermatology.

Patients on long-term therapy with HU can develop various side effects, including a wide variety of mucocutaneous manifestations, which appear in 10% to 35% of patients. The most common skin changes are facial erythema, hyperpigmentation, xerosis, alopecia, skin atrophy, melanonychia, and ulcers on the lower limbs. Other less frequent adverse effects are DM-like rash and nonmelanoma skin cancer (NMSC).³ DM-like rash resembles true DM both clinically and histologically. It presents as desquamating erythematous papules or plaques on the dorsum of the hands, typically associated with facial erythema and pronounced xerosis of

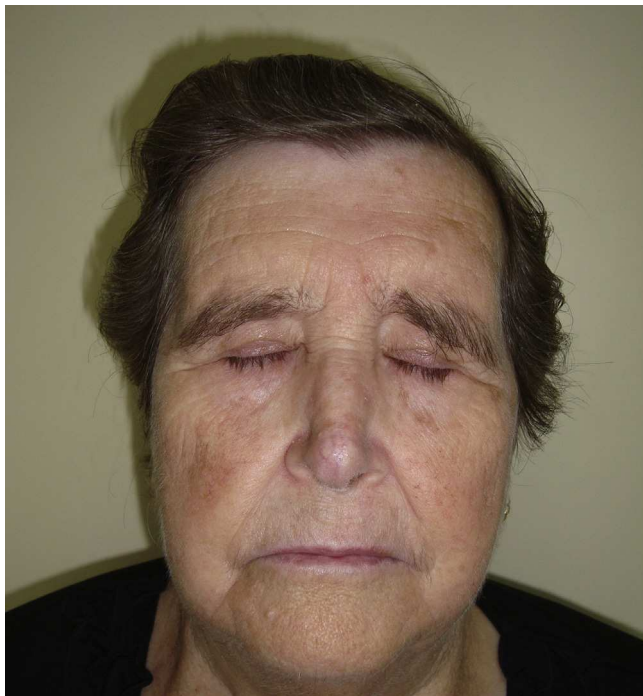

Figure 3 Resolution of the lesions after withdrawal of the hydroxyurea.

the skin. Patients rarely report other accompanying symptoms and there are usually no significant alterations of laboratory tests. Histologically, a lichenoid inflammatory infiltrate is found at the dermoepidermal interface, with vacuolization of the basal layer, dyskeratosis, and, rarely, mucin deposition.⁴ Chronic ulcerative lesions may also be present, particularly in areas susceptible to trauma, such as the malleolar region, the dorsum of the foot, and the heel. These ulcers are typically very painful and resolve spontaneously after withdrawal of the HU.⁵

It is also known that HU is associated with the appearance of squamous cell carcinoma, which arises after a latency period of 2 to 13 years. These tumors are usually aggressive, and the treatment must be withdrawn.⁶ In 2004, Sánchez-Palacios and Guitart⁷ proposed the term HU-related squamous dysplasia as a precancerous precursor condition of NMSC, and they identified the expression of p53 in the basal layer of the epidermis, demonstrating that this is a premalignant condition. Recently, Kalajian et al.³ also described a case of DM-like rash in which focal p53 expression was detected in the basal layer of the epidermis. Those authors suggested that DM-like manifestations should be considered a premalignant entity that requires periodic follow-up and the withdrawal of treatment with HU.

In our case the patient presented skin lesions clinically and histologically compatible with DM, but the biopsy revealed the presence of dysplastic keratinocytes with intense expression of p53. We therefore considered that this was an HU-induced DM-like rash presenting simultaneously with HU-induced squamous dysplasia; both of these clinical manifestations have an underlying phototoxic mechanism. It should also be noted that the lesions resolved completely after the withdrawal of treatment; this would support the implication of HU in the skin manifestations.

In conclusion, HU is a drug associated with marked skin toxicity. In patients who present lesions clinically and histologically consistent with DM-like rash, the treatment must be withdrawn and close follow-up initiated because of the risk of appearance of potentially aggressive carcinomas.

References

1. Jenerowicz D, Czarnecka-Operacz M, Stawny M, Silny W. Dermatomyositis-like eruption induced by hydroxyurea: A

- case report. *Acta Dermatovenerol Alp Panonica Adriat.* 2009;18:131–4.
2. Vassallo C, Passamonti F, Merante S, Ardighò M, Nolli G, Mangiacavalli S, et al. Muco-cutaneous changes during long-term therapy with hydroxyurea in chronic myeloid leukaemia. *Clin Exp Dermatol.* 2014;200:141–8.
 3. Kalajian AH, Cely SJ, Malone JC, Burruss JB, Callen JP. Hydroxyurea-associated dermatomyositis-like eruption demonstrating abnormal epidermal p53 expression: A potential premalignant manifestation of chronic hydroxyurea and UV radiation exposure. *Arch Dermatol.* 2010;146:305–10.
 4. Dacey MJ, Callen JP. Hydroxyurea-induced dermatomyositis-like eruption. *J Am Acad Dermatol.* 2003;48:439–41.
 5. Martorell-Calatayud A, Requena C, Nagore-Enguñados E, Guillén-Barona C. Úlceras dolorosas múltiples en la pierna resistentes al tratamiento asociadas a lesiones dermatomiositis-like en las articulaciones interfalángicas de las manos: hidroxiurea como agente causal. *Actas Dermosifiliogr.* 2009;100:804–7.
 6. Disdier P, Harle JR, Grob JJ, Weiller-Merli C, Magalon G, Weiller PJ. Rapid development of multiple squamous-cell carcinomas during chronic granulocytic leukemia. *Dermatologica.* 1991;183:47–8.
 7. Sánchez-Palacios C, Guitart J. Hydroxyurea associated squamous dysplasia. *J Am Acad Dermatol.* 2004;51:293–300.
- B. de Unamuno-Bustos,^{a,*} R. Ballester-Sánchez,^a
V. Sabater Marco,^b J.J. Vilata-Corell^a
- ^a *Servicio de Dermatología, Consorcio Hospital General Universitario de Valencia, Valencia, Spain*
^b *Servicio de Anatomía Patológica, Consorcio Hospital General Universitario de Valencia, Valencia, Spain*
- * Corresponding author.
E-mail address: blancaunamuno@yahoo.es
(B. de Unamuno-Bustos).

Primitive Polypoid Granular-Cell Tumor[☆]



Tumor primitivo polipoide de células granulares

In contrast to conventional granular cell tumor (Abrikossoff tumor), primitive polypoid granular cell tumor was first identified by LeBoit et al.¹ in 1991 and subsequently endorsed by Chaudhry and Calonje² as a dermal tumor of granular cells of non-neural origin. The tumor has a polypoid morphology and presents numerous mitoses, cytologic atypia, and a primitive immunophenotype. We present a new case and review the characteristics of this rare and poorly known tumor.

Our patient was a woman aged 44 years, with no past medical or family history of interest. She consulted for an asymptomatic lesion that had appeared 4 months earlier at the right nasolabial angle. Physical examination revealed a hard, polypoid lesion of 0.3 mm diameter, with a translucent surface. With a possible diagnosis of fibrous papule, milium cyst, or adnexal tumor (trichodiscoma), the lesion was excised. Histopathology revealed a circumscribed proliferation of cells in the superficial and mid dermis, surrounded by an epithelial collarette (Fig. 1). The cells, arranged in an interlinked fascicular pattern, had a polygonal morphology with abundant, granular eosinophilic cytoplasm and large vesicular nuclei (Fig. 2). Mitotic figures were present. No ulceration or necrosis was observed. Immunohistochemistry was positive for CD68 and negative for AE1-AE3, S-100, Melan A, CD34, desmin, actin, and smooth muscle. On the basis of these findings we made a diagnosis of primitive polypoid granular cell tumor.

Granular cells can be found in a varied group of tumors and reflect the intracytoplasmic accumulation of lysosomes and other components of the Golgi apparatus. Traditional and

conventional nomenclature makes reference to the cutaneous and mucosal granular cell tumor, known as Abrikossoff tumor, a benign neoplasm of neural origin derived from Schwann cells.³ However, other granular cell tumors of non-neural origin exist, including the congenital gingival granular cell tumor and the primitive polypoid granular cell tumor. In addition, numerous tumors can present granular cells, including myogenic tumors, melanocytic lesions, dermatofibroma, dermatofibrosarcoma protuberans, basal cell carcinoma, atypical fibroxanthoma, angiosarcoma, fibrous papule, ameloblastoma, and adnexal tumors with eccrine or apocrine differentiation.⁴

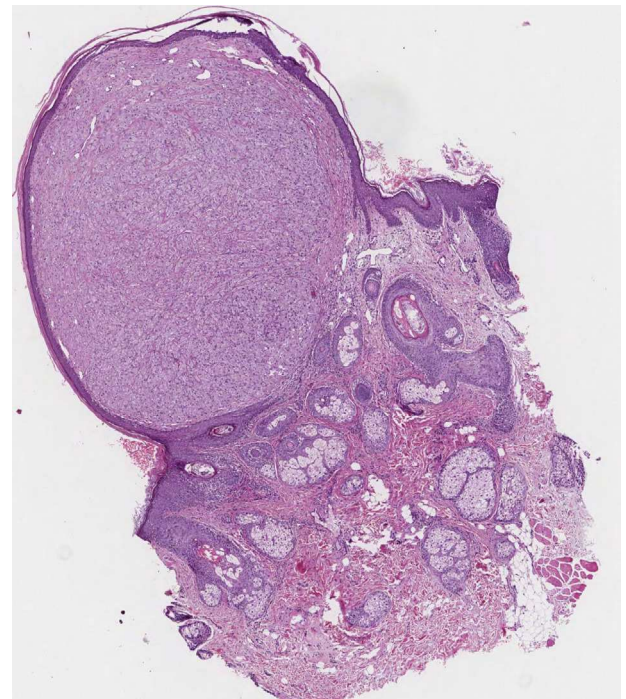


Figure 1 Tumor in the superficial and mid dermis, surrounded by an epithelial collarette. Hematoxylin-eosin, original magnification $\times 10$.

[☆] Please cite this article as: López-Villaescusa M, Rodríguez-Vázquez M, García-Arpa M, García-Angel R. Tumor primitivo polipoide de células granulares. *Actas Dermosifiliogr.* 2014;105:878–879.