

dence is slightly higher in men whereas, in the population over 50 years, these tumors are slightly more common in women; overall, the frequency is practically the same in men and women.³

The clinical differential diagnosis should include condyloma acuminatum, common warts, and squamous cell carcinoma (including the verrucous form).² In our case, in view of the recent reactivation of EBV infection, we also considered the possibility of lymphoma.⁷

Histology of verrucous xanthoma reveals a hyperkeratotic squamous epithelium with focal parakeratosis and no cellular atypia; foam cells are observed between elongated epithelial crests.^{2,6} These cells present a granular cytoplasm and the nucleus is typically eccentric. Immunohistochemistry of these cells is intensely positive for CD68 and negative for S-100.^{2,3} Three histopathological patterns have been described: verrucous, papillary, and flat. The verrucous pattern is the most common.³

The pathological differential diagnosis includes the common wart, lichen simplex chronicus, and eruptive xanthoma.⁸ There have been no previous reports of an association between this tumor and infection with EBV. However, there have been descriptions of patients in whom this lesion has arisen on previous mucosal or cutaneous lesions, such as oral lichen planus or mucosal GVHD.³ Our patient did not have GVHD affecting the mucosa or any other previous lesions of the oral mucosa.

The etiology and pathogenesis of verrucous xanthoma is not fully understood. It has been suggested that it may be an inflammatory reaction secondary to recurrent trauma, as the lesions mainly arise on areas subject to friction,⁹ or that the accumulation of foam cells in the dermis is the primary trigger, though no association with disorders of lipid metabolism has been found in the majority of the cases.⁶ No pathogenic role of the papillomavirus has been demonstrated.⁹ Given the known association between EBV and the induction of other lesions of the oral mucosa, such as oral hairy leukoplakia, in immunosuppressed patients, we considered the possibility that the appearance of this lesion could have been related to reactivation of this virus in our patient.⁷ However, no pathogenic relationship between EBV and verrucous xanthoma has been described to date, and this could therefore be an incidental finding in our case.

The treatment of choice is surgical excision of the lesion and recurrence is extremely rare.³

In summary, we have presented the case of a patient with a lingual tumor having the typical clinical and histopathological features of verrucous xanthoma. The patient presented recent reactivation of EBV infection, an association not previously described in the literature and which could therefore be a casual finding.

References

1. Shafer WG. Verruciform xanthoma. *Oral Surg Oral Med Oral Pathol.* 1971;31:784–9.
2. Oliveira PT, Jaeger RG, Cabral LA, Carvalho YR, Costa AL, Jaeger MM. Verruciform xanthoma of the oral mucosa. Report of four cases and a review of the literature. *Oral Oncol.* 2001;37:326–31.
3. Philipsen HP, Reichart PA, Takata T, Ogawa I. Verruciform xanthoma-biological profile of 282 oral lesions based on a literature survey with nine new cases from Japan. *Oral Oncol.* 2003;39:325–36.
4. Kanitakis J, Euvrard S, Butnaru AC, Claudy A. Verruciform xanthoma of the scrotum in a renal transplant patient. *Br J Dermatol.* 2004;150:161–3.
5. Fite C, Plantier F, Dupin N, Avril MF, Moyal-Barracco M. Vulvar verruciform xanthoma: ten cases associated with lichen sclerosus, lichen planus, or other conditions. *Arch Dermatol.* 2011;147:1087–92.
6. Sopena J, Gamero R, Iglesias L, Rodriguez-Peralto JL. Disseminated verruciform xanthoma. *Br J Dermatol.* 2004;151:717–9.
7. Mendoza N, Diamantis M, Arora A, Bartlett B, Gewirtzman A, Tremaine AM, et al. Mucocutaneous manifestations of Epstein-Barr virus infection. *Am J Clin Dermatol.* 2008;9:295–305.
8. Colonna TM, Fair KP, Patterson JW. A persistent lower lip lesion. Verruciform xanthoma. *Arch Dermatol.* 2000;136:665–6, 669.
9. Frankel MA, Rhodes HE, Euscher ED. Verruciform xanthoma in an adolescent: a case report. *J Low Genit Tract Dis.* 2012;16:70–4.

P. Maldonado-Cid,^{a,*} L. Noguera-Morel,^a M.J. Beato-Merino,^b R. de Lucas-Laguna^a

^a *Servicio de Dermatología, Hospital Universitario La Paz, Madrid, Spain*

^b *Servicio de Anatomía Patológica, Hospital Universitario La Paz, Madrid, Spain*

* Corresponding author.

E-mail address: pmaldonadocid@gmail.com (P. Maldonado-Cid).

Congenital Subungual and Periungual Melanocytic Nevus[☆]

Nevus melanocítico congénito subungueal y periungueal

To the Editor:

A healthy newborn infant aged 12 hours, of Ecuadorian origin and with no family history of melanoma or other tumors

[☆] Please cite this article as: Agusti-Mejias A, et al. Nevus melanocítico congénito subungueal y periungueal. *Actas Dermosifiliogr.* 2013;104:446-8.

of interest, was referred for evaluation of a congenital lesion of the nail of the third finger of the left hand. The infant had not suffered any birth or postnatal trauma to the affected finger.

Physical examination showed practically the whole nail surface to be a homogeneous erythematous-brown color (Fig. 1A). Dermoscopy revealed black globules arranged linearly on the brown background of the nail plate and a marked gray periungual pigmentation with brown globules (Fig. 2A). Correlation of the clinical and dermoscopic findings suggested melanocytic nevus of the nail matrix as the most likely diagnosis, although other melanocytic lesions or hemorrhage could not be excluded at that time. Given the apparent benign nature of the lesion,

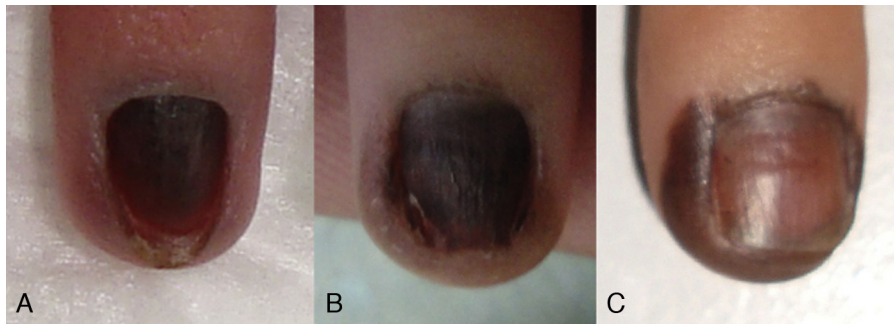


Figure 1 A, Initial clinical photograph showing homogeneous brown melanonychia. B, Two months later the periungual alterations were clearly visible. C, After 6 months of follow-up, the periungual component had become more pronounced.

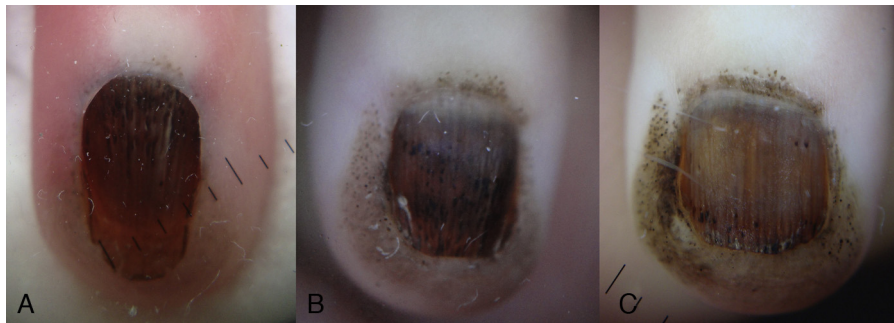


Figure 2 A, The initial dermoscopy revealed the presence of pigmented globules in the nail plate and in the proximal periungual skin. B, Two months later, pigmented globules were visible on a brown background, with narrow and regular longitudinal lines in the nail plate. C, At 6 months the dermoscopic pattern was unchanged.

it was decided to keep the infant under close observation.

Two months later the pigmented area had spread beyond the borders of the nail plate and there was clear involvement of the periungual skin (Fig. 1B). Dermoscopy of this new situation revealed pigmented globules on a light-brown background in the periungual skin, narrow and regular longitudinal lines in the nail plate, and globules of black pigment most numerous in the distal third of the plate (Fig. 2B).

Punch biopsy of the hyponychium was performed and histology revealed a junctional melanocytic proliferation of benign appearance, with melanocytes grouped in nests and as isolated cells in the epidermis (Fig. 3). Histology of a distal fragment of the nail plate showed deposits of melanin. The final diagnosis was periungual and subungual congenital melanocytic nevus (CMN). After 6 months of follow-up the periungual component of the nevus had become more evident but the size of the lesion was unchanged (Fig. 1C and Fig. 2C).

Periungual and subungual CMN is a very rare entity, with only 2 previous descriptions in the literature.^{1,2}

The lesion presents clinically as a homogeneous pigmentation of the nail plate. Usually it increases in size to affect the periungual skin, a finding that supports the diagnosis of a pigmented melanocytic lesion. Our case is the first in which the dermoscopic features of this type of lesion have been reported; the dermoscopic pattern is similar to that of CMNs at other sites, with pigmented globules of irregular size and distribution clearly visible on a background of homogeneous

pigmentation.³ The total melanonychia and the presence of globules in subungual CMNs are due to participation of the nail bed epidermis in the formation of part of the nail plate. The narrow longitudinal lines can be explained by involvement of the nail matrix.⁴

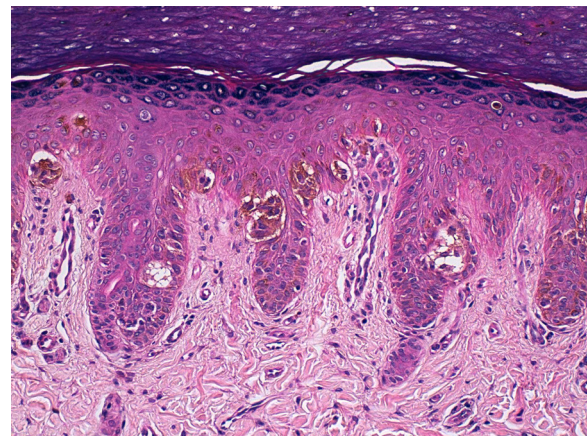


Figure 3 Epidermal hyperplasia and a proliferation of melanocytes with small nuclei and no atypia or pleomorphism; the melanocytes were arranged in nests of different sizes in the deep part of the epithelium and also as individual cells with a pagetoid distribution in the superficial layers of the epithelium (hematoxylin-eosin, original magnification x100).

In contrast to the usual histopathological features of CMNs, in which the dermal component predominates, subungual and periungual CMNs are characterized mainly by junctional melanocytic proliferations. In our case there were also isolated intraepidermal melanocytes.

The differential diagnosis must include disorders of various origins, including melanocytic lesions (ungual lentigo, nevus of the nail matrix, subungual blue nevus, ungual melanoma), racial pigmentation, drug-induced pigmentation, endocrine disorders, trauma, and hemorrhage.⁵ Histology of the nail plate is a simple and nontraumatic way to differentiate between melanic and hematic origins of the pigment deposits in the nail. In subungual CMNs, the early presence of proximal periungual pigment may be erroneously interpreted as a positive Hutchinson or pseudo-Hutchinson sign, observed respectively in acral melanomas and nail matrix nevus.⁶ However, the absence of mottled striate melanonychia and the presence of pigmented globules are features more commonly associated with a diagnosis of CMN.

It is often impossible to exclude melanoma histologically in acral and subungual melanocytic lesions, particularly in children, due either to the use of partial biopsies or the unusual characteristics of acral melanocytic nevi in children, which can present isolated nuclear atypia and even a pagetoid distribution of some of the melanocytes.⁷ In cases of melanonychia in which malignancy is suspected (a broad band of pigment, Hutchinson sign, irregular dermoscopic features, a dark-skinned patient), the lesion must therefore be completely excised.^{7,8}

The management of pigmented nail lesions will therefore depend on whether the rare but very serious childhood acral lentiginous melanoma is suspected.^{9,10} Dermoscopic and clinical follow-up should be reserved for lesions with low-risk features (narrow bands, uniform dermoscopic characteristics, no changes over time). In such cases, meticulous periodic follow-up (by dermoscopy and a photographic record) would appear to be the most suitable option, as it would avoid the potential cosmetic and functional sequelae of excision or biopsy.^{5,7,8}

In conclusion, we have presented the third case of subungual and periungual CMN to be reported in the literature. Knowledge of this entity can help to prevent aggressive treatments (wide excision, amputation) due to the overdiagnosis of childhood acral lentiginous melanoma.

Acknowledgments

Our thanks to Dr. Antonio Torrelo of Hospital Niño Jesús in Madrid, Spain.

References

1. Coskey RJ, Magnell TD, Bernacki Jr EG. Congenital subungual nevus. *J Am Acad Dermatol.* 1983;9:747–51.
2. Libow LF, Casey TJ, Varela CD. Congenital subungual nevus in a black infant. *Cutis.* 1995;56:154–6.
3. Changchien L, Dusza SW, Agero AL, Korzenko AJ, Braun RP, Sachs D, et al. Age- and site-specific variation in the dermoscopic patterns of congenital melanocytic nevi: an aid to accurate classification and assessment of melanocytic nevi. *Arch Dermatol.* 2007;143:1007–14.
4. Johnson M, Shuster S. Continuous formation of nail along the bed. *Br J Dermatol.* 1993;128:277–80.
5. Braun RP, Baran R, Le Gal FA, Dalle S, Ronger S, Pandolfi R, et al. Diagnosis and management of nail pigmentations. *J Am Acad Dermatol.* 2007;56:835–47.
6. Ronger S, Touzet S, Ligeron C, Balme B, Viallard AM, Barrut D, et al. Dermoscopic examination of nail pigmentation. *Arch Dermatol.* 2002;138:1327–33.
7. Iorizzo M, Tosti A, Di Chiacchio N, Hirata SH, Misciali C, Michalany N, et al. Nail melanoma in children: differential diagnosis and management. *Dermatol Surg.* 2008;34:974–8.
8. Gershtenson PC, Krunic A, Chen H, Konanahalli M, Worobec S. Subungual and periungual congenital blue naevus. *Australas J Dermatol.* 2009;50:144–7.
9. Hernandez A, Torrelo A. Recent data on the risk of malignancy in congenital melanocytic nevi: the continuing debate on treatment. *Actas Dermosifiliogr.* 2008;99:185–9.
10. Clemente-Ruiz de Almiron A, Almazan-Fernandez FM, Serrano-Ortega S. On the age when malignant transformation of congenital melanocytic nevi occurs. *Actas Dermosifiliogr.* 2009;100:84–5.

A. Agusti-Mejias,^a F. Messeguer,^{b,*} I. Febrer,^a V. Alegre^a

^a *Servicio de Dermatología, Hospital General Universitario de Valencia, Valencia, Spain*

^b *Servicio de Dermatología, Instituto Valenciano de Oncología, Valencia, Spain*

* Corresponding author.

E-mail address: francescmb@comv.com (F. Messeguer).

Varicella Complicated by Rhabdomyolysis[☆]

Varicela complicada con rabdomiólisis

To the Editor:

Primary varicella-zoster virus (VZV) infection usually occurs in childhood and in the majority of cases runs a self-limiting course. In infants, adults, and immunocompromised indi-

viduals, however, the infection can be serious if certain complications develop.

We report the case of an immunocompetent adult patient with VZV infection complicated by rhabdomyolysis.

The patient was a 29-year-old man, with no relevant past medical history, who presented at the emergency department with pruritic skin lesions. He said that the lesions, which were not initially filled with fluid, had erupted in successive crops over the previous 24 hours, causing intense itching. He also reported fever of 39 °C, a lack of strength and energy, and loss of appetite. He had experienced general malaise for a week and had also had low-grade fever and muscle pain. Physical examination revealed a rash, mainly

[☆] Please cite this article as: Martínez-Martínez ML, et al. Varicela complicada con rabdomiólisis. *Actas Dermosifiliogr.* 2013;104:448-9.