

TNPM presents as subcorneal or intraepidermal pustules composed mainly of neutrophils; this finding helps to differentiate TNPM from NTE, in which there is a predominance of eosinophils.<sup>1,3,7,10</sup>

In conclusion, we must be aware that TNPM is a benign condition with no systemic manifestations and it does not require treatment. This entity can be confused with serious infections, and patients with TNPM may be administered empirical antibiotic treatment or undergo invasive tests. It is essential that pediatricians and dermatologists are aware of TNPM in order to avoid unnecessary additional tests or treatments.

## References

- Ferrándiz C, Coroleu W, Ribera M, Lorenzo JC, Natal A. Sterile transient neonatal pustulosis is a precocious form of erythema toxicum neonatorum. *Dermatology*. 1992;185:18–22.
- Ramamurthy RS, Reveri M, Esterly NB, Fretzin DF, Pildes RS. Transient neonatal pustular melanosis. *J Pediatr*. 1976;88:831–5.
- Wagner A. Distinguishing vesicular and pustular disorders in the neonate. *Curr Opin Pediatr*. 1997;9:396–405.
- Merlob P, Metzker A, Reisner SH. Transient neonatal pustular melanosis. *Am J Dis Child*. 1982;136:521–2.
- Wyre Jr HW, Murphy MO. Transient neonatal pustular melanosis. *Arch Dermatol*. 1979;115:458.
- Barr RJ, Globberman LM, Werber FA. Transient neonatal pustular melanosis. *Int J Dermatol*. 1979;18:636–8.
- Mebazaa A, Khaddar Kort R, Cherif F, Mokni M, Haouet S, Ben Osman A. Transient pustular eruption in neonates. *Arch Pediatr*. 2011;18:291–3.
- Menni S, Boccardi D, Crosti C. Neonatal toxic erythema: clinico-epidemiologic characteristics and recent pathogenic hypothesis. *Pediatr Med Chir*. 2005;27:22–5.
- Van Praag MC, Van Rooij RW, Folkers E, Spritzer R, Menke HE, Oranje AP. Diagnosis and treatment of pustular disorders in the neonate. *Pediatr Dermatol*. 1997;14:131–43.
- Chia PS, Leung C, Hsu YL, Lo CY. An infant with transient neonatal pustular melanosis presenting as pustules. *Pediatr Neonatol*. 2010;51:356–8.

A. Agusti-Mejias,<sup>a,\*</sup> F. Messeguer,<sup>b</sup> I. Febrer,<sup>a</sup> V. Alegre<sup>b</sup>

<sup>a</sup> *Servicio de Dermatología, Hospital General Universitario de Valencia, Valencia, Spain*

<sup>b</sup> *Servicio de Dermatología, Instituto Valenciano de Oncología, Valencia, Spain*

\*Corresponding author.

*E-mail address:* annaagusti@comv.es (A. Agusti-Mejias).

## Multifocal Fixed Drug Eruption Probably Induced by Mefenamic Acid<sup>☆</sup>

### Exantema fijo medicamentoso múltiple probablemente inducido por ácido mefenámico

*To the Editor:*

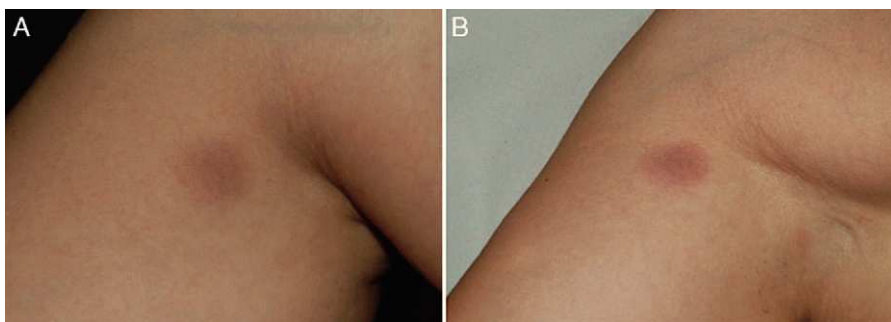
Mefenamic acid is a nonsteroidal anti-inflammatory inhibitor of cyclooxygenase 1 and 2 that is marketed in Spain under the name of Coslan (Pfizer). According to the summary of product characteristics, it is indicated for the treatment of pain, inflammation, and fever of any etiology, dysmenorrhoea, menorrhagia due to dysfunctional causes, rheumatoid arthritis, and acute or chronic gout. It can cause cardiovascular, genitourinary, gastrointestinal, hepatic, hematologic, respiratory, and cutaneous adverse effects. Fixed drug eruption (FDE), and multifocal FDE in particular, is an infrequent cutaneous adverse effect of mefenamic acid.<sup>1</sup>

A 36-year-old woman with no relevant medical history apart from occasional treatment with mefenamic acid for dysmenorrhoea (Coslan capsules, 250 mg/8 h) consulted for 4 skin lesions that had appeared some months earlier. She reported that the lesions occasionally caused a burning sensation but that there were no other associated symp-

toms. Skin examination revealed 4 round, well-demarcated, brownish-grayish macular lesions on her right shoulder, arm, and thigh, and on her left hip; the lesions measured between 1.5 and 2 cm in diameter (Fig. 1A). On suspecting FDE due to mefenamic acid, we asked the patient if she noticed any changes in the lesions when she took this drug, and she stated that while she had noticed that the lesions got worse during her period, she had not related this to the drug. We reexamined the patient after an oral challenge with the drug and confirmed worsening of the lesions (Fig. 1B). Skin biopsy showed vacuolar interface dermatitis with necrotic keratinocytes and a predominantly lymphohistiocytic inflammatory infiltrate with neutrophils and eosinophils (Fig. 2). Extravasation of red blood cells was also observed in the papillary dermis. Based on the clinical and histopathologic findings, a diagnosis of multifocal FDE due to mefenamic acid was made. Patch tests performed with the series recommended by the Spanish Contact Dermatitis and Skin Allergy Research Group (GEIDAC) and Coslan 30% in petrolatum applied directly to healthy and lesional skin were negative. The patient was advised to stop taking mefenamic acid. The lesions cleared gradually and only slight residual hyperpigmentation remained 6 months after the initial visit.

FDE is a skin reaction characterized by skin and/or mucosal lesions that appear at the same site each time the offending drug is taken. It usually manifests as 1 or more round hyperpigmented macular lesions that may exceptionally be accompanied by systemic symptoms, such as fever, anorexia, general malaise, nausea, and diarrhea.<sup>2</sup> Some patients may also develop multiple, widespread lesions.<sup>1,3,4</sup> A wide range of drugs can trigger FDE, but the most common

<sup>☆</sup> Please cite this article as: Pérez-Pérez L, et al. Exantema fijo medicamentoso múltiple probablemente inducido por ácido mefenámico. *Actas Dermosifiliogr*. 2013;104:85-7.



**Figure 1** A, Round, well-demarcated, brownish-grayish macular lesions measuring 2 cm in diameter on the anteromedial aspect of the right arm. B, The lesions worsened after an oral challenge test, acquiring a reddish-violaceous color.

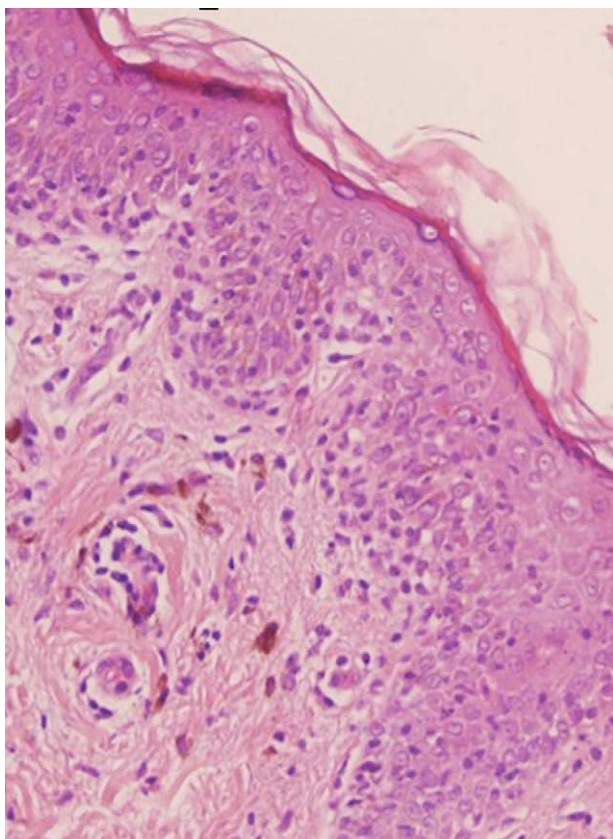
ones are antibiotics (particularly co-trimoxazole), anticonvulsants, and analgesics.<sup>5</sup>

Mefenamic acid is an anthranilic acid derivative that inhibits prostaglandin synthesis. It was recently described as an inducer of FDE and has also been implicated in bullous pemphigoid,<sup>6</sup> anaphylaxis,<sup>7</sup> Stevens-Johnson syndrome,<sup>8</sup> and linear immunoglobulin A dermatosis.<sup>9</sup>

Although mefenamic acid has been widely used in a range of medical fields, only a few cases of mefenamic

acid-induced FDE have been reported to date.<sup>1,4,10</sup> Furthermore, less common clinical manifestations have been reported in several of these cases, including multifocal dalmatian dog-like lesions,<sup>1</sup> reticulated lesions,<sup>3</sup> and lesions mimicking erythema multiforme.<sup>4</sup>

Diagnosis is based on clinical history and characteristic skin findings. An oral challenge test with the relevant drug is the gold standard for confirming clinical suspicion of FDE, as occurred in our case. Patch testing of lesional and healthy skin is a safe, noninvasive alternative, but it has variable sensitivity, with results differing according to the concentration and penetration of the test substance, the vehicle used, and the thickness of skin at the test site. A negative patch test result, therefore, does not rule out FDE.<sup>2</sup>



**Figure 2** Necrotic keratinocytes, vacuolar interface dermatitis, and a predominantly lymphohistiocytic infiltrate with isolated eosinophils and hemosiderin-laden macrophages. Hematoxylin-eosin, original magnification  $\times 200$ .

## References

1. Rallis E, Rigopoulos D, Anyfantakis V, Kalogirou O, Christophidou E, Papadakis P, Katsambas A. 'Dalmatian dog'-like skin eruption (two cases of multifocal fixed drug eruption induced by mefenamic acid). *J Eur Acad Dermatol Venereol*. 2005;19:753-5.
2. Handisurya A, Moritz KB, Riedl E, Reinisch C, Stingl G, Wöhrl S. Fixed drug eruption caused by mefenamic acid: A case series and diagnostic algorithms. *J Dtsch Dermatol Ges*. 2011;9:374-8.
3. Dar NR, Masood S, Mustafvi SA. Reticulated multifocal fixed drug eruption due to mefenamic acid - a new morphological pattern. *J Coll Physicians Surg Pak*. 2005;15:562-3.
4. Sowden JM, Smith AG. Multifocal fixed drug eruption mimicking erythema multiforme. *Clin Exp Dermatol*. 1990;15:387-8.
5. Mahboob A, Haroon TS. Drugs causing fixed eruptions: A study of 450 cases. *Int J Dermatol*. 1998;37:833-8.
6. Shepherd AN, Ferguson J, Bewick M, Bouchier IA. Mefenamic acid-induced bullous pemphigoid. *Postgrad Med J*. 1986;62:67-8.
7. Couto M, Duarte C, Geraldes L, Inês L, Malcata A. Anaphylaxis to mefenamic acid in a patient with new onset of systemic lupus erythematosus. *Allergol Immunopathol (Madr)*. 2010;38:224-6.
8. Chan JC, Lai FM, Critchley JA. A case of stevens-johnson syndrome, cholestatic hepatitis and haemolytic anaemia associated with use of mefenamic acid. *Drug Saf*. 1991;6:230-4.

9. Jin K, Nakano H, Akasaka E, Rokunohe D, Minakawa S, Minagawa S, et al. Linear immunoglobulin A bullous dermatosis possibly induced by mefenamic acid. *J Dermatol.* 2010;37: 269–71.
10. Long CC, Finlay AY, Marks R. Fixed drug eruption to mefenamic acid: A report of three cases. *Br J Dermatol.* 1992;126: 409–11.

L. Pérez-Pérez,\* J. García-Gavín, F. Allegue, A. Zulaica  
*Servicio de Dermatología, Complejo Hospitalario Universitario de Vigo, Vigo, Spain*

\*Corresponding author.

*E-mail address:* lidiacomba@yahoo.es (L. Pérez-Pérez).

## Cutaneous Vascular Calcifications Secondary to Treatment with Teriparatide<sup>☆</sup>

### Calcificaciones vasculares cutáneas secundarias al tratamiento con teriparatida

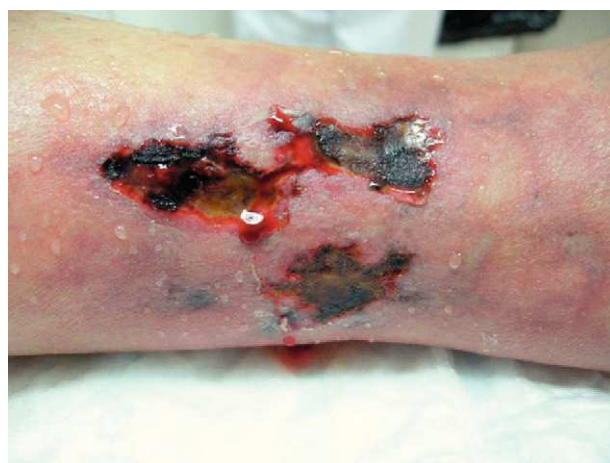#### *To the Editor:*

The term calciphylaxis has been used since the 1960s<sup>1</sup> to describe skin ulceration secondary to vascular calcifications in patients with terminal renal failure and secondary hyperparathyroidism.<sup>2</sup> However, nonuremic causes have been reported and the mechanism of cutaneous vascular calcification has now been investigated more extensively.<sup>3</sup> The condition is currently considered a complex multifactorial process and not a simple deposition. Daudén et al.<sup>4</sup> proposed a new classification of these processes, using cutaneous vascular calcification (CVC) as a general term, and we are in agreement with this terminology.

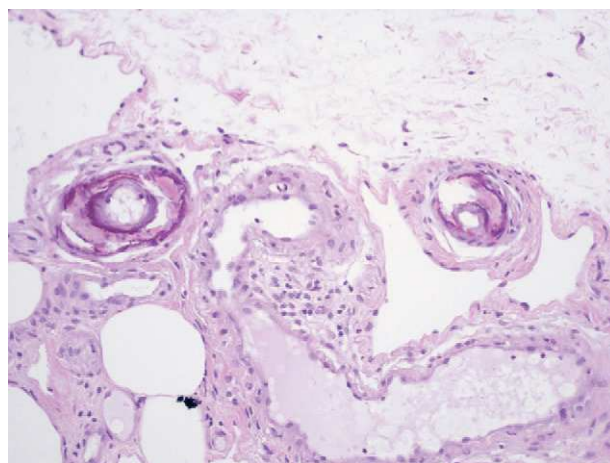
We report the case of an 80-year-old woman with a history of severe refractory osteoporosis, hypertension, obesity, atrial fibrillation, and polymyalgia rheumatica treated with corticosteroids. As her osteoporosis was resistant to the usual treatments, she was prescribed the human recombinant peptide teriparatide. The active fragment is a 34 amino-acid sequence of parathyroid hormone (rhPTH). The agent is administered subcutaneously at a dose of 20 µg every 24 hours. Two months after starting treatment, the patient developed painful necrotic ulcers on the legs on areas of skin with a livedoid appearance (Fig. 1). The echo-Doppler study, renal function tests, calcium-phosphate product, and autoimmune studies were all normal. Skin biopsy (Fig. 2) showed ulceration and necrosis of the epidermis, dilatation of the dermal vessels, and circumferential calcification in walls of small arteries at the dermal-epidermal junction. Immunofluorescence was negative. These findings were consistent with calciphylaxis, but renal failure was not present. However, on administration of teriparatide, which acts like endogenous parathyroid hormone (PTH), a pharmacological state of hyperparathyroidism had been induced. The drug was withdrawn and, at 3 weeks after discontinuation, the patient's lesions improved progressively. She died from progression of her heart failure 6 months after onset of her skin condition. At the time of death, she was free of skin lesions (Fig. 3).

<sup>☆</sup> Please cite this article as: Leis-Dosil VM, et al. Calcificaciones vasculares cutáneas secundarias al tratamiento con teriparatida. *Actas Dermosifiliogr.* 2013;104:87-8.

CVC usually occurs in patients with certain predisposing factors, such as obesity, chronic inflammation, corticosteroid treatment, and menopause, and also in individuals with abnormal calcium phosphate metabolism and PTH levels. In recent years, the pathogenic relationships between these factors have been determined. The vascular endothelial cells are seen to adopt an osteogenic phenotype in these patients. Both vascular endothelial cells and osteoblasts, osteoclasts, and vascular smooth muscle cells can express the receptor activator of nuclear factor  $\kappa$  B (RANK) and its ligand RANKL on their membranes; when RANK is activated,



**Figure 1** Necrotic ulcers on the legs on areas of skin with a livedoid appearance.



**Figure 2** Circumferential calcification on the wall of small arteries. Hematoxylin and eosin, original magnification  $\times 100$ .