

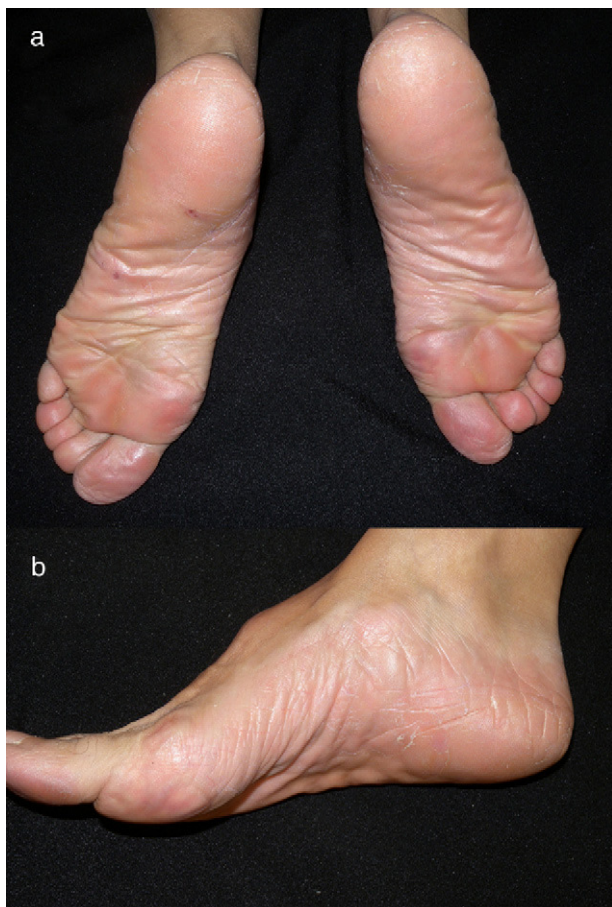

Figure 2 Complete resolution after 4 weeks of treatment with alitretinoin.

lesions occurred in up to a third of patients who initially responded to alitretinoin after 24 weeks of follow-up. A recent study reported that a second course of treatment with alitretinoin at a dosage of 30 mg/d in patients who relapsed achieved clearance in up to 80% of cases, with good tolerance⁶; this would indicate that this medication could be used for long-term management of chronic hand eczema. Alitretinoin is therefore a useful and probably cost-effective treatment for this condition.⁷

We have presented the case of a patient with chronic foot eczema that did not respond to various traditional treatments. Alitretinoin achieved complete clearance of the eczema. Alitretinoin could be a useful alternative for the management of patients with chronic foot eczema.

References

1. Worth A, Sheikh A. Food allergy and atopic eczema. *Curr Opin Allergy Clin Immunol.* 2010;10:226–30.
2. Katsambas A, Abeck D, Haneke E, van de Kerkhof P, Burzykowski T, Molenberghs G, et al. The effects of foot disease on quality of life: results of the Achilles Project. *J Eur Acad Dermatol Venereol.* 2005;19:191–5.
3. Bissonnette R, Diepgen TL, Elsner P, English J, Graham-Brown R, Homey B, et al. Redefining treatment options in chronic hand eczema (CHE). *J Eur Acad Dermatol Venereol.* 2010;24:1–20.
4. Ruzicka T, Lynde CW, Jemec GB, Diepgen T, Berth-Jones J, Coenraads PJ, et al. Efficacy and safety of oral alitretinoin (9-cis retinoic acid) in patients with severe chronic hand eczema refractory to topical corticosteroids: results of a randomized, double-blind, placebo-controlled, multicentre trial. *Br J Dermatol.* 2008;158:808–17.
5. Agüayo-Leiva IR, Urrutia S, Jaén-Olasolo P. Respuesta al tratamiento con alitretinoína oral en ECM refractario con eczema crónico de manos refractario al tratamiento con corticoides tópicos potentes: nuestra experiencia en 15 pacientes. *Actas Dermosifiliogr.* 2011;102:616–22.
6. Bissonnette R, Worm M, Gerlach B, Guenther L, Cambazard F, Ruzicka T, et al. Successful retreatment with alitretinoin in patients with relapsed chronic hand eczema. *Br J Dermatol.* 2010;162:420–6.
7. Blank PR, Blank AA, Szucs TD. Cost-effectiveness of oral alitretinoin in patients with severe chronic hand eczema—a long-term analysis from a Swiss perspective. *BMC Dermatol.* 2010;10:4.

A. Tejera-Vaquerizo,* J.S. Sánchez-Vizcaíno,
V. Haro-Gabaldón

*Servicio de Dermatología, Hospital Infanta Margarita,
Cabra-Córdoba, Spain*

* Corresponding author.

E-mail address: antoniotetej@aedv.es
(A. Tejera-Vaquerizo).

Dermatosis Neglecta or Terra Firma-Forme Dermatitis[☆]

Dermatosis neglecta o terra firma-forme dermatosis

Dermatosis neglecta, or terra firma-forme dermatosis, is a clinical entity whose etiology has still not been fully defined.

It is characterized by the presence of asymptomatic, dirt-like hyperpigmented plaques with a slightly papillomatous surface; these plaques cannot be removed with ordinary cleansing but disappear completely on swabbing with 70% ethyl or isopropyl alcohol. We report a new case of this entity.

The patient was a 10-year-old girl with no relevant past medical history. Her mother brought her to our unit for assessment of a persistent asymptomatic skin rash that had appeared several months earlier. Physical examination revealed brownish, reticulated, macular areas that were slightly papillomatous to the touch in some zones. The lesions were distributed symmetrically on the

[☆] Please cite this article as: Martín-Gorgojo A, et al. Dermatitis neglecta or terra firma-forme dermatosis. *Actas Dermosifiliogr.* 2012;103:932–4.

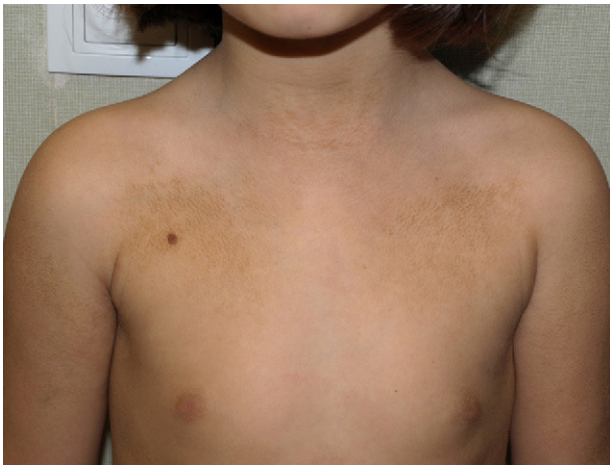

Figure 1 Clinical appearance of the lesions.

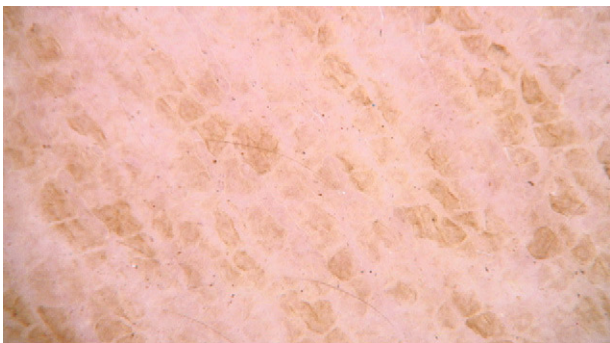


Figure 2 Dermatoscopy image obtained using a digital contact dermatoscope with immersion fluid.

anterior aspect of the trunk, shoulders, and base of the neck (Fig. 1). Dermoscopy revealed no melanocytic pattern and no vascular abnormalities, but there were polygonal areas of brownish pigmentation that followed a linear pattern in some places and spared the natural folds of the skin (Fig. 2).

Given the distribution and appearance of the lesions, swabbing with a cotton ball soaked in 70% ethyl alcohol was performed as a diagnostic test that doubles as treatment. This procedure cleared the lesions, revealing skin of a normal appearance in the treated area (Fig. 3). We established a diagnosis of dermatosis neglecta and instructed the patient to apply an exfoliant cream containing keratolytic agents (silica granules, salicylic acid, triclosan, aluminum oxide, and zinc oxide) and then wash the affected areas in order to accelerate the healing and complete resolution of the lesions.

Terra firma-forme dermatosis is much more common than the literature would lead one to believe. It was first described by Duncan et al.,¹ who reported cases from the 1970s and gave the condition its Latin name for its earthy or dirtlike appearance. The cause of terra firma-forme dermatosis is not yet fully understood. It is believed that the lesions arise as a consequence of a delay in the maturation of keratinocytes, with melanin retention, and a sustained accumulation of sebum, sweat, corneocytes, and microorganisms in regions in which hygiene measures are less rigorous (e.g. neck, trunk, navel, and flanks), leading to insufficient exfoliation and the formation of a highly adhesive, compact dirt

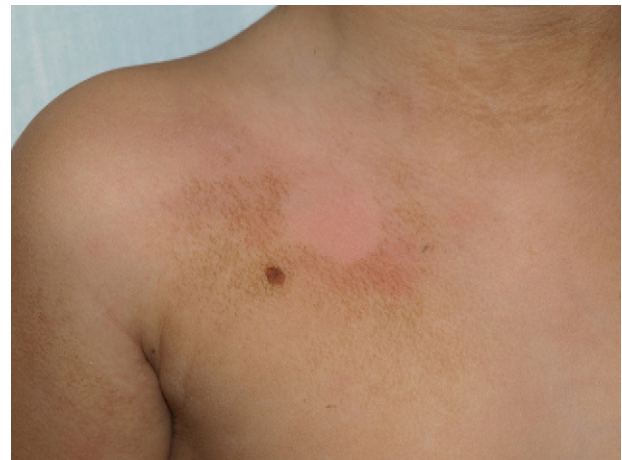

Figure 3 Clinical appearance of the lesions after swabbing with a cotton ball soaked in 70% ethyl alcohol.

crust.^{2,3} This hypothesis is supported by the fact that these lesions have also been seen in painful areas—in particular hyperesthetic ones—that many patients avoid touching during their hygiene routines (hence the name dermatosis neglecta).⁴

Terra firma-forme dermatosis and dermatosis neglecta are widely considered to be synonymous, but some authors have proposed a separation of the terms. Although isolated cases of terra firma-forme dermatosis have been reported in infants, it occurs mainly in older children and adolescents with characteristic hygiene habits and with a distinctive distribution of the lesions,⁵ whereas dermatosis neglecta affects patients of any age whose hygiene in specific areas is insufficient.⁶

The differential diagnosis of the condition, which has a varied clinical presentation, should include confluent and reticulated papillomatosis of Gougerot and Carteaud (which, in exceptional cases, may partially respond to alcohol swabbing),⁷ pityriasis versicolor, acanthosis nigricans, pseudoacanthosis nigricans, psoriasis,⁸ dermatitis artefacta, some forms of ichthyosis, and, in certain localized cases, seborrheic keratoses and epidermal nevi.^{1,9}

Most cases of dermatosis neglecta can be diagnosed without performing tests other than the alcohol swab test. If performed, histopathologic studies—reported in the literature in just 8 patients to date—generally show epidermal acanthosis and papillomatosis as well as prominent lamellar hyperkeratosis with orthokeratotic whorls. The histopathologic differential diagnosis of dermatosis neglecta must therefore include benign papillomatous entities such as confluent and reticulated papillomatosis, acrokeratosis verruciformis, and epidermal nevi.¹⁰

The condition can be treated with the diagnostic method itself (swabbing with alcohol) or with products such as salicylic-acid-based exfoliants or other keratolytic agents in order to accelerate the normalization of the skin.

We conclude that dermatosis neglecta should be taken into consideration because of its ability to mimic other skin diseases. This entity is much more common than the literature would lead one to believe. In particular, the appearance of hyperpigmented lesions with an unusual pattern should

raise suspicion of dermatosis neglecta. In such cases, the alcohol swab test can be very useful.

References

1. Duncan WC, Tschen JA, Knox JM. Terra firma-forme dermatosis. *Arch Dermatol.* 1987;123:567–9.
2. Guarneri C, Guarneri F, Cannavò SP. Terra firma-forme dermatosis. *Int J Dermatol.* 2008;47:482–4.
3. Akkash L, Badran D, Al-Omari AQ. Terra Firma forme dermatosis. Case series and review of the literature. *J Dtsch Dermatol Ges.* 2009;7:102–7.
4. Vetrichevel TP, Sandhya V, Shobana S, Anandan S. Dermatitis neglecta unmasking recurrence of carcinoma nasopharynx. *Indian J Dermatol Venereol Leprol.* 2011;77:627.
5. Berk DR, Bruckner AL. Terra firma-forme dermatosis in a 4-month-old girl. *Pediatr Dermatol.* 2011;28:79–81.
6. Lucas JL, Brodell RT, Feldman SR. Dermatitis neglecta: a series of case reports and review of other dirty-appearing dermatoses. *Dermatol Online J.* 2006;12:5.
7. Berk DR. Confluent and reticulated papillomatosis response to 70% alcohol swabbing. *Arch Dermatol.* 2011;147:247–8.
8. Park JM, Roh MR, Kwon JE, Lee KY, Yoon TY, Lee MG, et al. A case of generalized dermatitis neglecta mimicking psoriasis vulgaris. *Arch Dermatol.* 2010;146:1050–1.
9. Ruiz-Maldonado R, Durán-McKinster C, Tamayo-Sánchez L, Orozco-Covarrubias ML. Dermatitis neglecta: dirt crusts simulating verrucous nevi. *Arch Dermatol.* 1999;135:728–9.
10. Dalton SR, Pride H. The histopathology of terra firma-forme dermatosis. *J Cutan Pathol.* 2011;38:537–9.

A. Martín-Gorgojo,* V. Alonso-Usero, M. Gavrilova,
E. Jordá-Cuevas

Servicio de Dermatología, Hospital Clínico Universitario de Valencia, Spain

*Corresponding author.

E-mail address: dr.martingorgojo@gmail.com

(A. Martín-Gorgojo).

Acquired Total Leukonychia in a Patient With Human Immunodeficiency Virus Infection[☆]

Leuconiquia total adquirida en paciente infectado por el virus de la inmunodeficiencia humana

Leukonychia, also known as white nails, is a form of nail discoloration that has been known since antiquity. Baran et al.¹ classified this rare entity in three main types: true leukonychia, when the alteration of the nail plate is caused by changes in the nail matrix; apparent leukonychia, caused by a disturbance of the nail bed; and pseudoleukonychia, in which the alteration of the nail plate is caused by an external factor such as onychomycosis. The condition is classified as totalis, partialis, striata, or punctata depending on the how the nail plate is affected.

We report the case of a 58-year-old man with human immunodeficiency virus (HIV) infection since 1992 but with no other relevant past history. Since starting antiretroviral therapy in 1993, the patient had followed several different treatment regimens using various drugs—zidovudine, didanosine, stavudine, lamivudine, and others—alternating with periods during which his medication was temporarily suspended. The patient remained clinically and immunologically stable and tolerated the drugs well until November 2009, at which time his viral load rose to a detectable level; ongoing treatment with nevirapine was maintained and lamivudine and abacavir were added to the regimen. At the time of writing, the patient continued on this treatment regimen.

The patient was referred to our dermatology unit for assessment of whitening of the nails affecting the whole nail plate of all 10 fingers (Fig. 1). The patient stated that the leukonychia had first appeared when he started taking lamivudine and abacavir in November 2009. Having ruled out all known causes of true leukonychia and pseudoleukonychia, we diagnosed the patient with idiopathic acquired true leukonychia totalis that did not affect the toenails (Fig. 2).

Leukonychia is defined as a whitening of the nails. It was first described in 1919 by Mees,² who found an association between this alteration of a skin appendage and arsenic poisoning. When nail plate involvement begins at the nail matrix, the condition is considered to be true leukonychia, which can be hereditary or acquired. Hereditary true leukonychia may occasionally be seen in the context of rare, complex syndromes such as LEOPARD syndrome, Bauer syndrome, and keratoderma hypotrichosis leukonychia syndrome.^{3,4} Acquired true leukonychia can

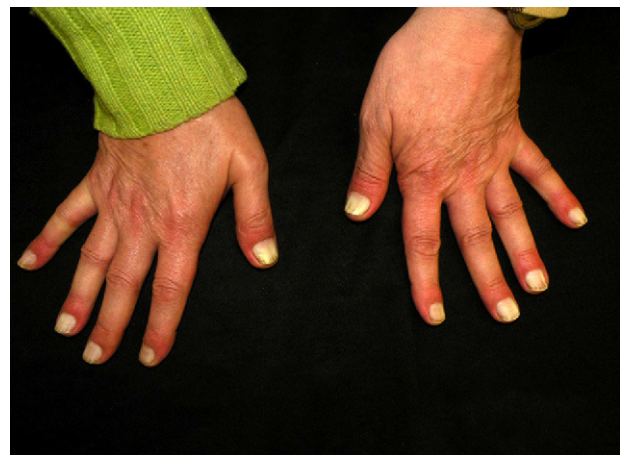

Figure 1 Complete whitening of all 10 nail plates on the hands.

[☆] Please cite this article as: Pielasinski-Rodríguez U, et al. Leuconiquia total adquirida en paciente infectado por el virus de la inmunodeficiencia humana. *Actas Dermosifiliogr.* 2012;103:934–5.