

Body-Hair Transplant for Cicatricial Alopecia[☆]

Reconstrucción de alopecia cicatricial mediante trasplante de pelo corporal

To the Editor:

Hair transplantation is a continuously evolving field. Since 1959, when Orentreich¹ described the phenomenon of donor dominance in androgenic alopecia, thus paving the way for body-hair transplants, new techniques have not ceased to appear. During the last 15 years, the perception of hair transplantation as an aggressive technique with an artificial result has finally disappeared thanks to the use of follicular units, which have made the technique minimally invasive with mostly acceptable results.²⁻⁴

We present the case of a 30-year-old man with Norwood class III alopecia who underwent hair transplantation at another center in 2008 with the strip method, by means of which he received 3800 follicular units in the frontoparietal region. The follicular units were harvested from the parieto-occipital region.

He consulted 1.5 years after the intervention for assessment of the reconstruction of the donor strip scar (3 cm × 2 cm) and reinforcement of the frontal area behind the hairline (Fig. 1A and B).

We considered the possibility of using the occipital region as the donor strip. However, the low follicular density (50 units/cm²) at this site led us to repopulate the frontal area using a combination of follicular units from the occipital region and chest. This approach provided a reasonable number of follicles.

Follicular units were obtained using a 0.8-mm punch after applying local anesthetic with 2% lidocaine with 1:100,000 epinephrine. A total of 335 follicular units were obtained from the chest (Fig. 2A) and 600 from the parieto-occipital region.

Once the recipient site had been anesthetized, the incisions were made in the scar area using a 19G needle, and the body hair follicular units were implanted at a density of 17 units/cm².

Of the 335 follicular units obtained, 100 were implanted in the scar of the parietotemporal area to evaluate the

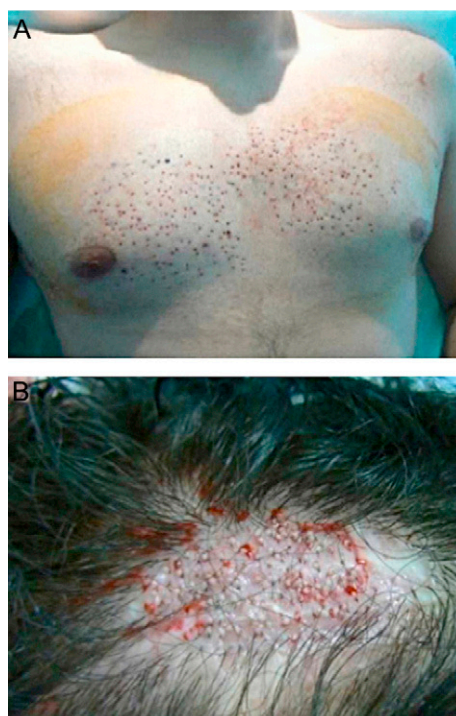

Figure 2 (A) Donor strip on the chest after follicular unit extraction. (B) Implantation of follicular units of body hair in the scar.

response (Fig. 2B), and the remaining body-hair units plus the 600 units from the parieto-occipital region were implanted in the frontal region.

Evaluation at 4 and 6 months after treatment revealed that more than 80% of the units had survived in the scar; the hair was practically indistinguishable from the scalp hair in terms of thickness and length (Fig. 3A and B). The donor area on the chest healed correctly without visible scars or keloids, thus leaving the patient with a very satisfactory cosmetic outcome.

Cicatricial alopecia resulting from burns, surgery, injury, or radiotherapy is an excellent indication for hair transplantation.⁵⁻⁷ Our patient developed an iatrogenic parietal scar after a "megasection" of follicle donation, possibly because the donor strip was larger than generally

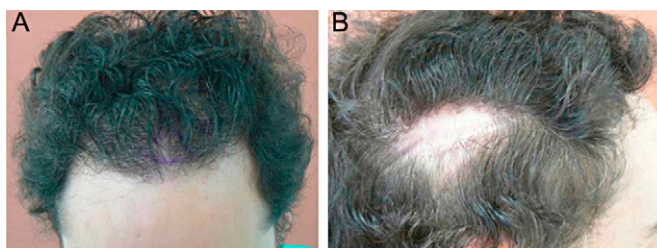


Figure 1 (A) Appearance of the frontotemporal region after the first conventional hair transplant. (B) Appearance of the donor strip in the parietotemporal region.

[☆] Please cite this article as: Meyer-González T, Bisanga C. Reconstrucción de alopecia cicatricial mediante trasplante de pelo corporal. *Actas Dermosifiliogr.* 2012;103:163-4.

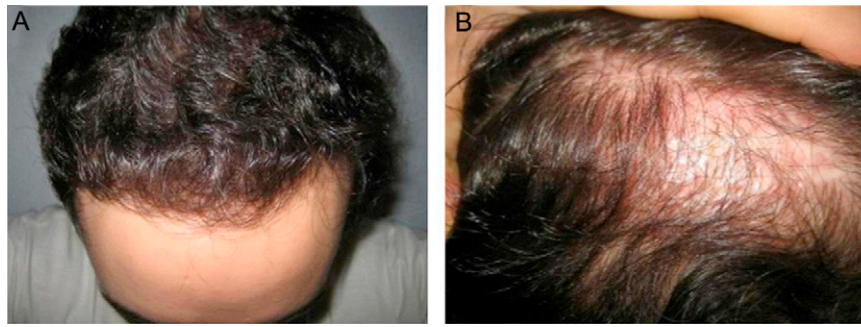


Figure 3 Six months after the procedure: (A) frontal region; (B) area of the scar.

recommended in order to harvest as many follicles as possible. The therapeutic alternatives we considered to rebuild the scar were implantation of a tissue expander and direct closure, which the patient rejected, or a follicular unit transplant on the scar.

One of the precautions to be taken into account when performing a hair transplant on a scar is that the density in units/cm² must be less than on an area of normal skin (30–40 units/cm²), because of the risk of follicles competing for the reduced blood flow through the scar tissue.

In conventional hair transplantation, the donor strip is limited to the scalp. However, the follicular unit extraction technique enables body hair to be transplanted to the scalp: instead of removing the strip, the follicular units are extracted individually using circular punches measuring 0.7–1 mm in diameter. The punch holes heal by second intention within a few days.

Transplantation of body hair follicular units has been described in the literature,^{4,5} which addresses the concept of “recipient-dominance”. In other words, the body hair that is transplanted takes on the characteristics of the hair at the receptor site^{5,8,9}; better results are achieved with follicular units from the beard and chest.

While it is true that the chest is prone to keloids and that this should be taken into account and the patient informed, there have been no reports of keloids in white patients after follicular unit extraction using a punch.

Transplantation of body hair follicles is still a controversial technique with few published case reports. Nevertheless, we present this case of cicatricial alopecia, because, although the density obtained to cover the scar is not yet sufficient, we did observe a good growth rate for the body hair. We believe that it is important for the dermatologist to be aware of the usefulness and potential of hair transplantation, since we are often faced with patients who have not been adequately informed about the technique or who have even been discouraged by the specialist.

References

- Orentreich N. Autografts in alopecias and other selected dermatological conditions. *Ann NY Acad Sci.* 1959;83:463–79.
- Rassman WR, Carson S. Micrografting in extensive quantities. The ideal hair restoration procedure. *Dermatol Surg.* 1995;21:306–11.
- Bernstein RM, Rassman WR, Szaniawski W, Halperin A. Follicular transplantation. *Int J Aest Rest Surg.* 1995;3:119–32.
- Bernstein RM, Rassman WR. Follicular transplantation: patient evaluation and surgical planning. *Dermatol Surg.* 1997;23:771–84.
- Jones R. Body hair transplant into wide donor scar. *Dermatol Surg.* 2008;34:857.
- Woods R, Woods-Campbell A. Chest hair micrografts display extended growth in scalp tissue: a case report. *Br Assoc Plastic Surg.* 2004;57:789–91.
- Jimenez-Acosta F, Ponce I. Técnica actual del trasplante de pelo de unidades foliculares. *Actas Dermosifiliogr.* 2010;101:291–306.
- Millar SE. Molecular mechanisms regulating hair follicle development. *J Investg Dermatol.* 2002;118:216–25.
- Hwang S, Kim JC, Ryu HS, Cha YC, Lee SJ, Na GY, et al. Does recipient site influence hair growth characteristics in hair transplantation? *Dermatol Surg.* 2002;28:795–9.

T. Meyer-Gonzalez,^{a,*} C. Bisanga^b

^a *Servicio de Dermatología, Hospital Virgen de la Victoria, Málaga, Spain*

^b *Unidad de Trasplante de Pelo, BHR Clinic, Bruselas, Belgium*

* Corresponding author.

E-mail address: tmeyer@aedv.es (T. Meyer-Gonzalez).

Topical Rapamycin Solution to Treat Multiple Facial Angiofibromas in a Patient With Tuberous Sclerosis[☆]

Utilización de solución de rapamicina tópica para el tratamiento de múltiples angiofibromas faciales en una paciente con esclerosis tuberosa

To the Editor:

We report the case of a 27-year-old woman with a 10-year history of tuberous sclerosis. Her first visit to the dermatologist revealed several of the cutaneous manifestations characteristic of the disease, namely, disseminated facial angiofibromas (Fig. 1), multiple periungual Koenen tumors on both feet, hypopigmented macules on the trunk, and a shagreen plaque on the back. The patient also had epilepsy and mental retardation. She had no known internal hamartomatous lesions.

A number of treatments—multiple shave excisions, pulsed-dye laser, electrodesiccation, and 0.1% topical tacrolimus ointment—had been applied in order to improve her facial appearance and reduce the number of angiofibromas. The response to treatment had been poor, with no appreciable reduction in the number of lesions and persistence of erythema. At that time, pharmacy-prepared topical rapamycin, 1 mg/mL, was applied twice daily on the affected areas of both cheeks. A clear clinical improvement was observed after 3 months' treatment, with a reduction in the number of lesions and in the underlying erythema (Fig. 2).

Tuberous sclerosis is an autosomal-dominant genodermatosis characterized by hamartomas affecting various organs, including the skin and central nervous system. Its pathogenesis is based on abnormalities of the proteins hamartin and tuberlin, which are coded on the loci 9p34 and 16p13.3, respectively.¹ Symptoms comprise the classic triad of multiple angiofibromas, epilepsy, and mental retardation, although this combination is only seen in 26% of patients.²

Despite its wide clinical variability and variable penetrance,³ facial angiofibromas are found in 83–90% of cases.^{3,4} These lesions are considered pathognomic and develop mainly on the nasolabial folds, cheeks, chin, scalp, forehead, and ears.⁴ They usually appear during the first decade of life, stabilize during adolescence, and are life-long. They are not malignant, although their appearance constitutes a very frequent presenting complaint in these patients.

Treatment can take several forms, including simple excision, cryosurgery, curettage, dermabrasion, carbon dioxide laser, and photodynamic therapy. No single treatment has proven sufficiently effective to control their onset or prevent recurrence.^{5–7}

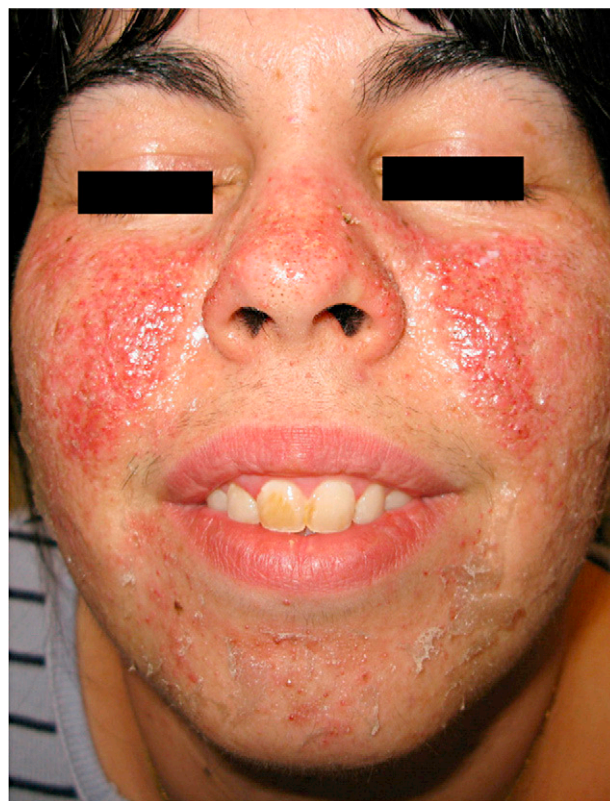

Figure 1 Clinical image of the lesions before the start of treatment. Multiple facial angiofibromas predominantly affecting the cheeks, with a prominent erythematous base.

Rapamycin (sirolimus) is an oral immunosuppressive agent used mainly in kidney transplantation. Its mechanism of action has not been clearly defined, although it is known to interfere with the mTOR protein pathway, which is responsible for cell proliferation and inhibition of apoptosis in patients with tuberous sclerosis.⁸ The proteins hamartin and tuberlin also suppress mTOR pathway activity. These proteins are modified in tuberous sclerosis in such a way that their altered function causes permanent activation of the mTOR pathway, thus leading to the onset of hamartomatous tumors in various regions.⁹ It has been suggested that the mechanisms by which rapamycin reduces the number and size of tumors in tuberous sclerosis are inhibition of angiogenesis^{9,10} and of aberrant growth factors,¹⁰ although these phenomena have only been verified in extracutaneous hamartomatous lesions (brain, kidney, and lung).

After the failure of the therapeutic approaches adopted to control the facial angiofibromas in our patient, we decided to try topical treatment with rapamycin, an alternative that has been described in 2 previous publications.^{9,10} Ours is the fourth reported case in which this therapy was administered to control facial angiofibromas. A clear improvement was observed in all 4 patients, with a marked reduction or complete disappearance of the lesions. Facial erythema also improved after only a few months' treatment. Of the 3 cases reported previously, 2 were treated with rapamycin solution (1 mg/mL) and the remaining patient with 0.1% rapamycin ointment. Treatment was adminis-

[☆] Please cite this article as: Valerón-Almazán P, et al. Utilización de solución de rapamicina tópica para el tratamiento de múltiples angiofibromas faciales en una paciente con esclerosis tuberosa. *Actas Dermosifiliogr.* 2012;103:165–6.