

CLINICAL SCIENCE LETTERS

Perforating Lichen Nitidus on an Atypical Site

I. Arrue,^a M.A. Arregui,^a N. Saracibar,^b and R. Soloeta^a

^aServicio de Dermatología and ^bServicio de Anatomía Patológica, Hospital Santiago Apóstol, Vitoria, Spain .

To the Editor:

Lichen nitidus is a rare disorder characterized by multiple, skin-colored, micropapular lesions with a smooth, shiny surface, located preferentially on the flexor surface of the arms and wrists and on the abdomen and genitalia, though they can become generalized. Histological study shows a lymphohistiocytic infiltrate that broadens the dermal papillae and that is limited laterally by elongated rete ridges. The variants described include vesicular, hemorrhagic, linear, keratodermic, generalized, actinic, and perforating forms. There are only 5 case reports of perforating lichen nitidus.¹⁻⁴

We report a case of perforating lichen nitidus that affected the lateral borders of the fingers.

The patient was a 35-year-old man who was seen for evaluation of asymptomatic lesions on the fingers and toes; the lesions had been present more than 20 years. The patient had received treatment with topical corticosteroids with virtually no response. On examination, skin-colored, shiny, firm, monomorphic papules of 1 mm in diameter were observed on the palms, the dorsum of the feet, and lateral borders of the fingers (Figure 1).

Two biopsies were taken from these lesions, with similar findings in both samples. There was a lymphohistiocytic infiltrate in a broadened dermal papilla, with descending growth of the rete ridges surrounding the dermal inflammatory infiltrate like a hook (Figure 2).

The patient had been seen for the same disorder 9 years earlier in another center; biopsy had been performed and, apart from the findings described above, the histology showed transepidermal elimination of collagen and keratin (Figure 3). The condition was therefore lichen nitidus that, during its course, had developed perforating lesions.

In view of the resistance to previous treatment with topical corticosteroids, topical tacrolimus was prescribed, with a minimal response of the lesions.

Lichen nitidus is a rare condition and the appearance of perforating lesions is exceptional. We have only found 5 cases of perforating lichen nitidus reported in the literature (Table), all in young patients. In addition, our patient presented involvement of the lateral borders of the fingers, an unusual site.⁵

The primary perforating dermatoses include elastosis perforans serpiginosa, reactive perforating collagenosis, and acquired perforating dermatosis. The secondary forms, in

which the transepidermal elimination is a consequence of another, underlying disorder, include perforating variants of calcinosis cutis, annular granuloma, chondrodermatitis nodularis helioides, lichen planus, and lichen striatus.⁴

Elastosis perforans serpiginosa and reactive perforating collagenosis are diseases of unknown origin, although there may be a hereditary factor. Elastosis perforans serpiginosa may be associated with Down syndrome and connective tissue diseases; it is characterized by keratotic papules of 2 to 5 mm that tend to be organized in a serpiginous or

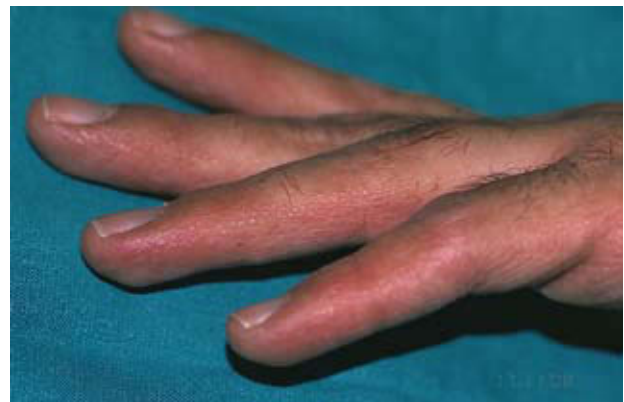

Figure 1. Papular lesions on the lateral borders of the fingers

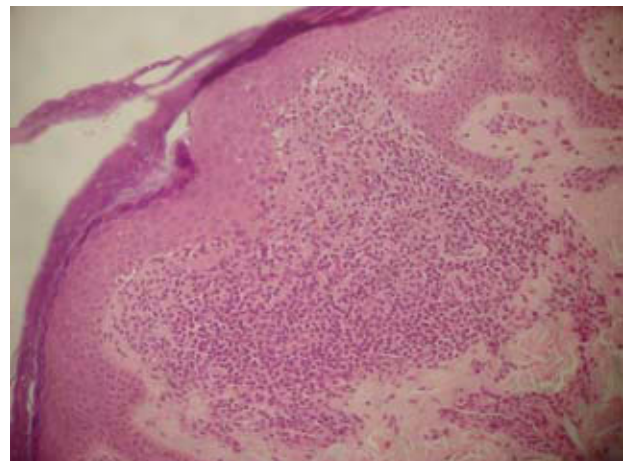


Figure 2. Subepidermal lymphohistiocytic infiltrate limited to the underlying dermal papilla. There is descending growth of the rete ridges, which surround the dermal inflammatory infiltrate (hematoxylin-eosin, $\times 40$).

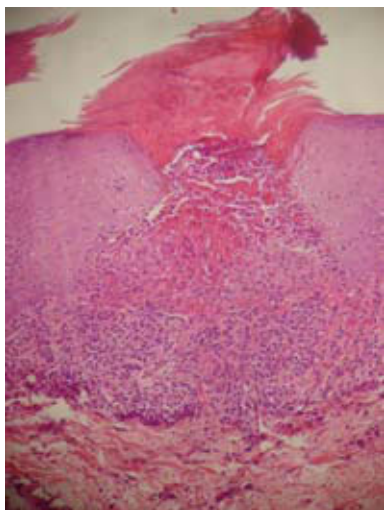


Figure 3. Dermal papilla occupied by lymphohistiocytic infiltrate with transepidermal elimination of collagen and keratin (hematoxylin-eosin, x40).

annular pattern, and are located on the neck, face, arms, and skin folds. The papules in reactive perforating collagenosis appear on the upper limbs, are larger (between 5 and 8 mm), and present a linear distribution due to the Koebner phenomenon, which is more common in this condition than in other perforating disorders. Acquired perforating dermatosis, on the other hand, affects adults and is frequently related to diabetes mellitus or renal failure; the lesions appear on the lower limbs.

The pathogenesis of the phenomenon of elimination of dermal material and keratin through the epidermis is unknown. A number of mechanisms to explain this finding have been proposed, such as abnormal epidermal proliferation and differentiation, connective tissue disorder, mechanical factor, and an immune mechanism.³ Bardach¹ and Banse-Kupin et al² suggested that the lichenoid infiltrate and abnormal fibrovascular structure in the dermis in lichen nitidus could lead to a proliferation of the adjacent rete ridges together with epidermal atrophy, surrounding and later eliminating the abnormal dermal material through the epidermal surface.

No differences have been found between the reported cases of perforating lichen nitidus and common lichen nitidus with regard to age at onset, distribution of the lesions or associated diseases. The perforating lesions of lichen nitidus occur most commonly on the forearms and hands, and may be secondary to an irritant mechanism, as proposed by Itami et al.³

Our patient presented lesions on the lateral borders of the fingers, a site not reported in the 5 published cases of perforating lichen nitidus; this gave rise to a differential diagnosis with acrokeratoelastoidosis and dyshidrosis.

Of the 2 cases of perforating lichen nitidus published by Yoon et al,⁴ one was treated with topical corticosteroids, with resolution of the majority of the lesions after a year of treatment, and there was spontaneous resolution of almost all the lesions in the other case. Our patient received topical therapy—corticosteroids and tacrolimus—with a very slight improvement.

We would like to draw attention to the rare distribution of the lesions of lichen nitidus in the present case and to the appearance of perforating lesions during the course of the disorder, a finding rarely commented in the literature.

Correspondence:
Itziar Arrue Michelena
Servicio de Dermatología
Hospital Santiago Apóstol
C/ Olaguibel, 29
01004 Vitoria, Spain
itziar.arruemichelena@osakidetza.net

Conflicts of Interest

The authors declare no conflicts of interest

Table 1. Summary of the Cases of Perforating Lichen Nitidus

References	Sex	Age at Onset	Site	Associations
Bardach ¹	M	8	Arms, forearms, trunk, legs	None
Banse-Kupin et al ²	M	22	Forearms, trunk, thighs, penis	Lichen planus
Itami et al ³	M	32	Fingers, left hand	None
Yoon et al ⁴	F	19	Wrists, elbows, knees, dorsum of the feet	None
Yoon et al ⁴	F	16	Hands, wrists, forearms, elbows, knees	None
Present Case	M	15	Fingers and toes	None

Abbreviations: F, female; M, male..

References

1. Bardach H. Perforating lichen nitidus. *J Cutan Pathol.* 1981;8:111-6. 232-6.
2. Banse-Kupin L, Morales A, Kleinsmith DA. Perforating lichen nitidus. *J Am Acad Dermatol.* 1983;9:452-6.
3. Itami A, Ando I, Kukita A. Perforating lichen nitidus. *Int J Dermatol.* 1994;33:382-4.
4. Yoon TY, Kim JW, Kim MK. Two cases of perforating lichen nitidus. *J Dermatol.* 2006;33:278-80.
5. Rudd ME, Ha T, Schofield OMV. An unusual variant of lichen nitidus. *Clin Exp Dermatol.* 2003;28:92-102.
6. Rodríguez-Martín M, Rodríguez-García F, Sáez M, Cabera R, Pérez-Robayna N, Sidro M, et al. Pápulas pruriginosas en axilas. *Actas Dermosifiliogr.* 2006;97:281-3.
7. Smoller BR, Flynn TC. Immunohistochemical examination of lichen nitidus suggests that it is not a localised popular variant of lichen planus. *J Am Acad Dermatol.* 1992;27:232-6.
8. Kint A, Meysman L, Bugingo G, Verdonk G, Hublé F. Lichen nitidus and Crohn's disease. *Dermatologica.* 1982;164:272-7.
9. Patrizi A, Lernia D, Paulazzi P. Lichen nitidus generalise, trisomie 21 et mégacolon congenital. *Ann Dermatol Vénéreol.* 1991;118:725.
10. Kim YC, Shim SD. Two cases of generalized lichen nitidus treated successfully with narrow-band UV-B phototherapy. *Int J Dermatol.* 2006;45:615.

Eczema Herpeticum in Cutaneous T-Cell Lymphomas

V. Monsálvez, I. Polo, L. Fuertes, C. Zarco, and F. Vanaclocha

Servicio de Dermatología, Hospital 12 de Octubre, Madrid, Spain.

To the Editor:

Disseminated skin infection due to herpes simplex virus, also known as eczema herpeticum or Kaposi varicelliform eruption (cutaneous dissemination of herpes simplex infection in patients with generalized skin disease), has been reported in numerous dermatoses, the most frequent being atopic dermatitis, followed by other dermatoses such as Darier disease, ichthyosis, and bullous diseases. Few cases of disseminated herpes have been reported in cutaneous T-cell lymphomas (CTCL).

We present the case of a 61-year-old man diagnosed with stage IVB mycosis-fungoides-type CTCL (T4N3M1B2) in 2006, with erythroderma, widespread lymph node involvement, and a count of circulating cells with abnormal CD3⁺ CD4⁺ CD7⁺ phenotype of 702/ μ L (78% of the total count); the absolute lymphocyte count was 800/ μ L, of which 720 were CD4⁺. During his illness, the patient was treated with phototherapy, methotrexate, prednisone, bexarotene, interferon, and a histone deacetylase inhibitor.¹ In January, 2008, whilst on treatment with monthly liposomal doxorubicin, he presented an exacerbation of the lesions, with more marked skin infiltration and pruritus, and developed superficial crusted lesions on the dorsum of the nose that spread to the rest of the skin (Figures 1-3); there were associated vesicles and pustules, and he had a fever of 39°C. A diagnosis of disseminated eczema herpeticum was made, with a positive culture for herpes simplex virus type 1 from a pustule and positive blood cultures for *Staphylococcus aureus* sensitive to cloxacillin. Treatment was started with intravenous acyclovir 10 mg/kg/d, vancomycin 1 g/12 h, and meropenem 1 g/8 h, and washing with 1:1000 zinc sulfate solution 3 times a day.

The lesions disappeared practically completely from the face within 10 days; at discharge, a few lesions remained on the palms of the hands. There was a parallel improvement in the general state and in the fever.

In 1978, Segal and Watson² described a patient with mycosis fungoides who developed a vesicular rash during treatment with psoralen-ultraviolet (UV) A; the rash extended to cover the whole skin and was associated with fever. A further 2 cases were published by Brion et al³ in 1981; these patients also developed the infection during an advanced stage of the lymphoma while receiving treatment with corticosteroids and cyclophosphamide and, in another case, with leukapheresis. Later, Hayashi

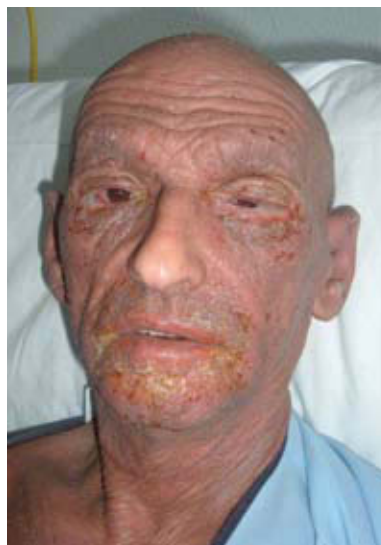

Figure 1. Crusted, erosive lesions affecting the whole face.