

LETTERS TO THE EDITOR

Photoaggravated Eczema Due to Promethazine Cream

I Arrue, B Rosales, FJ Ortiz de Frutos, and F Vanaclocha

Servicio de Dermatología, Hospital Universitario 12 de Octubre, Madrid, Spain

To the Editor:

Promethazine, a member of the phenothiazine group, is the active ingredient of Phenergan cream, a topical antihistamine.

We describe the case of a 24-year-old man with no relevant history who developed pruriginous lesions in the antecubital crease of the left forearm. Following application of emollients (Nivea cream, Lactovit body milk, and Johnson oil), lesions also appeared on the contralateral forearm. One week later, the patient used Phenergan cream and the lesions then spread to both arms. After 5 days, he discontinued the product and resumed treatment with emollients, with new lesions appearing on the face, abdomen, and legs. After starting treatment with topical corticosteroids (diflucortolone valerate) and oral corticosteroids (prednisone) at a dose of 0.5 mg/kg, the lesions disappeared within 10 days.

Because photosensitive eczema due to Phenergan cream was suspected, patch tests were performed using the standard series of the Spanish Research Group for Contact Dermatitis and Skin Allergies (Grupo Español de Investigación en Dermatitis de Contacto y Alergia Cutánea) and photopatch tests were done using the photoallergens of the Spanish Photobiology Group (Grupo Español de Fotobiología) and the products used by the patient (Figure 1). The standard allergen series was from the True Test (Alk Abelló, Hillerod, Denmark), supplemented with others from Chemotechnique (Malmo, Sweden). The photoallergen series was from Marti Tor (Barcelona, Spain). The photopatch test was done twice on the back and read at 48 and 96 hours, with 1 of the 2 series irradiated with UV-A at 10 J/cm². Positive results were

obtained to Phenergan cream and promethazine at 96 hours on the irradiated area, but only to Phenergan cream in the nonirradiated area (Figure 2). Positive results were also obtained with wool alcohols, gum rosin, quaternium 15, and formaldehyde in the standard series at 96 hours. The result obtained with Phenergan cream and promethazine in the photopatch was relevant in this case, as were the wool alcohols, because these were also excipients in Phenergan cream and Nivea cream. We found no relevance for gum rosin, quaternium 15, or formaldehyde. The diagnosis was photosensitive eczema due to promethazine and allergic contact eczema caused by the excipient ingredients of Phenergan cream.

Previously, the topical use of antihistamines was extremely common. This is the apparent cause of many cases of sensitization to these products. Sidi et al¹ and Suurmond² found 68 cases of positive reactions to Phenergan cream in patch tests. Only 17 of these reacted to promethazine. However, these studies are old, the methodology is unclear, and we have no information about the relevance.

At present, not many cases of allergic contact eczema due to promethazine are found. Between 1980 and 1987, de la Cuadra Oyanguren et al³ performed patch tests in 95 patients, obtaining 1 positive case for promethazine.

In a study done in Belgium by Goossens et al⁴ in 1998, 14 cases were positive for promethazine among 12 460 patch tests carried out.

There is little information in the literature on the development of photosensitive eczema because of this topical antihistamine. Articles from the 1950s and 1960s mentioned that

promethazine was capable of photosensitization, with eczematous lesions in areas exposed to light; however, the studies were not rigorous and no photopatch tests were done. In Scandinavia, a multicenter study was conducted between 1980 and 1981, collecting the results from 745 photopatch tests.⁵ Of these, 24 were positive for promethazine, most of them due to phototoxicity. In the study by Goossens et al,⁴ in 2 of the 14 patients with a positive reaction to promethazine photosensitization to this drug was also observed. The Spanish Photobiology Group recently published the results of photopatch tests at 7 Spanish hospitals

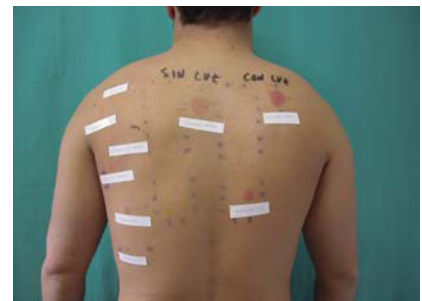

Figure 1. Results of patch and photopatch testing.

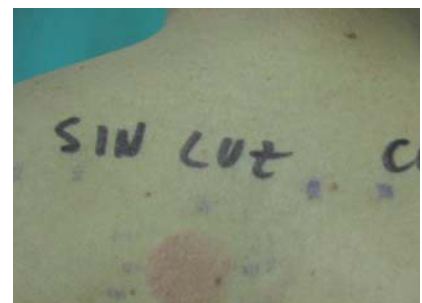


Figure 2. Positive reaction to Phenergan cream can be seen at a higher magnification. The irradiated area shows a more severe reaction than the nonirradiated section.

in 2004 and 2005.⁶ The highest number of positive reactions was seen with ketoprofen (45 cases). Promethazine occupied sixth place with 7 cases, although in none of them were the reactions considered relevant. In our experience, of the 48 photopatch tests done in the Dermatology Department of Hospital 12 de Octubre in Madrid between 1999 and 2005, 5 cases were positive for promethazine, 4 of them of unknown relevance and considered to be the result of phototoxicity.

In addition to photosensitization to promethazine, our patient developed allergic contact eczema to wool alcohols, an excipient ingredient in Phenergan cream. We found only 1 article on sensitization to an excipient of Phenergan cream, specifically to triethanolamine.⁷ Among 22 patients with positive patch test results for Phenergan cream, 4 reacted to

triethanolamine. However, we found no cases of photosensitive eczema due to an excipient of Phenergan cream reported in the literature.

In summary, in terms of delayed reactions to Phenergan cream, cases of photosensitive eczema due to promethazine considered to have current relevance are uncommon, and no cases have been found in which this diagnosis was associated with allergic contact eczema caused by the excipient ingredients of Phenergan cream.

References

1. Sidi E, Hincky M, Gervais A. Allergic sensitization and photosensitization to Phenergan cream. *J Invest Derm.* 1953; 24:345-52.
2. Suurmond D. Skin reactions to Phenergan cream. *Dermatologica.* 1964;128: 87-9.
3. De la Cuadra Oyanguren J, Marquina Vila A, Martorell Aragonés A, Sanz Ortega J, Aliaga Boniche A. Dermatitis alérgica de contacto en la infancia: 1972-1987. *An Esp Pediatr.* 1989;30: 363-6.
4. Goossens A, Linsen G. Contact allergy to antihistamines is not common. *Contact Dermatitis.* 1998;39:38.
5. Wennersten G, Thune P, Brodthagen H, Jansen C, Rystedt I. The Scandinavian multicenter photopatch study. Preliminary results. *Contact Dermatitis.* 1984;10:305-9.
6. De la Cuadra-Oyanguren J, Pérez-Ferriols A, Lecha-Carretero M, Giménez-Arnau AM, Fernández-Redondo V, Ortiz de Frutos FJ, et al. Resultados y evaluación del fotoparche en España: hacia una nueva batería estándar de fotoalérgenos. *Actas Dermosifiliogr.* 2007;98:96-101.
7. Suurmond D. Patch test reactions to Phenergan cream, promethazine and tri-ethanolamine. *Dermatologica.* 1966; 133:503-6.

Unilateral Contact Dermatitis Caused by Footwear

C Laguna-Argente, E Roche, J Vilata, and J de la Cuadra

Servicio de Dermatología, Hospital General Universitario de Valencia, Spain

To the Editor:

Contact dermatitis caused by footwear is usually bilateral. It generally starts on the dorsum of the fifth toe and gradually extends to the dorsum of the foot, sparing the interdigital folds. Potassium dichromate is the most frequent

allergen. We report the case of a patient diagnosed with dermatitis caused by contact with shoe dye on 1 foot who was initially wrongly diagnosed with dermatitis artefacta.

The patient was a 64-year-old woman who consulted with an outbreak of blisters that had begun 1 month earlier and that was evenly distributed along the lateral aspects of her right foot (Figure 1). Examination revealed 2 flaccid blisters on the side of the foot resting on an erythematous base and a linear erythema on the dorsum of the foot. Residual lesions were also present. The other foot was not affected and the rest of the skin was spared. A first possible diagnosis was thought to be contact eczema, although it was strange that this did not affect both feet. The patient was taking cinitapride, domperidone, and diazepam; her basic medication was suspended but the

blisters remained. Dermatitis artefacta was also considered in the differential diagnosis. The patient had been receiving psychiatric treatment for anxiety-depression syndrome for many years. We insisted that it was strange that the lesions only affected the right foot and, during the following visit, she presented with erythema and vesiculation on the left foot that had begun a few hours earlier, and with distant lesions on her chest; furthermore, the right foot was now free of lesions for the first time. A biopsy was performed and histopathology revealed characteristics typical of acute eczema.

The patient eventually noticed that the lesions were related to the use of shoes that had been dyed 2 months previously. The dye had stained the internal sides of the right shoe (Figure 2), exactly where the blisters had

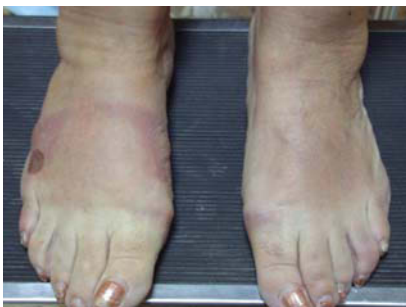

Figure 1. Blisters on the lateral aspects of the right foot with linear erythema on the dorsum of the foot. Residual lesions were also observed. No lesions were apparent on the other foot.