

CASE REPORTS

Atypical Pachydermatous Cutaneous Course of Mastocytosis

MP Sánchez-Salas, AC Lázaro, J Martín, MP Grasa, and FJ Carapeto

Departamento de Dermatología, Hospital Clínico Universitario Lozano Blesa, Zaragoza, Spain

Abstract. We describe the case of a 75-year-old man first seen in our department 32 years ago for generalized yellowish erythematous papular lesions along with an attack of pruritus, tachycardia, and flushing. A diagnosis of urticaria pigmentosa was proposed on the basis of these symptoms and the results of skin biopsy. Periodic follow-up in the intervening years included serial laboratory analyses, skin biopsy, radiological studies, bone scintigraphy, and ultrasound of the liver and spleen, with no remarkable findings. The symptoms caused by release of mediators decreased progressively. In one of the most recent visits, bone marrow aspirate and biopsy were performed, revealing multifocal infiltrates of typical CD117⁺ mast cells. Consequently, the hematology department diagnosed indolent systemic mastocytosis. A number of marked cutaneous changes were observed during the follow-up period: the skin currently appears thickened, indurated, redundant, and grayish, with a pachydermatous appearance. This represents an extremely rare form of cutaneous involvement in mastocytosis and only 1 case has been described in the literature.

Key words: mastocytosis, pachydermatous skin, urticaria pigmentosa.

EVOLUCIÓN CUTÁNEA ATÍPICA (TIPO PAQUIDÉRMICO) DE UNA MASTOCITOSIS

Resumen. Presentamos el caso de un varón de 75 años que fue estudiado por primera vez en nuestro Servicio hace 32 años, por presentar unas lesiones papulosas eritemato-amarillentas generalizadas, junto con crisis de prurito, taquicardia y *flushing*. El diagnóstico propuesto a partir de este cuadro clínico y de la biopsia cutánea fue de urticaria pigmentosa. A lo largo de estos años el paciente ha sido revisado periódicamente, realizándose pruebas analíticas seriadas, biopsias cutáneas, estudios radiológicos y gammagráficos óseos y ultrasonografías hepáticas y esplénicas, sin hallazgos significativos. Los síntomas derivados de la liberación de mediadores han decrecido progresivamente. En una de sus últimas revisiones se le realizó un aspirado y biopsia de médula, apareciendo infiltrados multifocales de mastocitos típicos, CD117⁺, por lo que fue catalogado por el Servicio de Hematología en fase de mastocitosis sistémica indolente. Desde el punto de vista cutáneo queremos destacar los prominentes cambios que se han producido a lo largo de la evolución: la piel actualmente aparece engrosada, infiltrada, redundante y de color grisáceo, mostrando aspecto paquidérmico. Este es un tipo extremadamente raro de afectación cutánea en las mastocitosis, habiéndose descrito solamente un caso en la literatura.

Palabras clave: mastocitosis, piel paquidérmica, urticaria pigmentosa.

Introduction

In 1869, Nettleship and Tay¹ described a skin disorder called urticaria pigmentosa that consisted of pigmented

maculopapular lesions that produced an urticarial pruritic response to certain stimuli, such as scratching or rubbing the skin. The discovery of mast cells by Paul Erlich² in 1879 showed that the lesions were formed by accumulations of those cells.

Mastocytosis comprises a group of diseases characterized by an abnormal proliferation and accumulation of mast cells in 1 or more organs, with the skin being the most commonly affected site. Symptoms develop following infiltration of the organs by mast cells and release of mast-cell mediators.

Correspondence:
María Pilar Sánchez-Salas
Barrio Mato, 38
22314 Salas Altas, Huesca, Spain
psanchezsalas@gmail.com

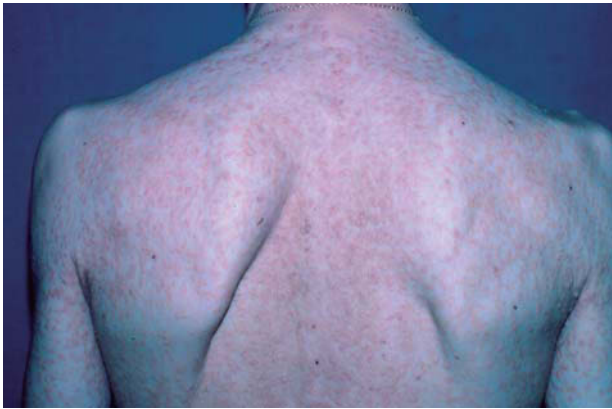

Figure 1. Skin lesions of our patient 32 years ago.

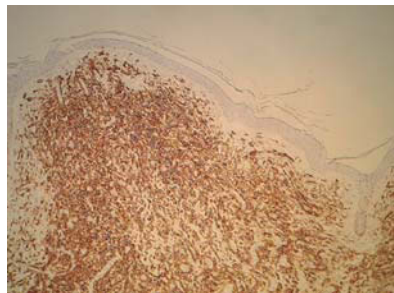


Figure 2. Mast-cell infiltrate in the dermis (immunohistochemistry with anti-CD117; original magnification, $\times 100$).

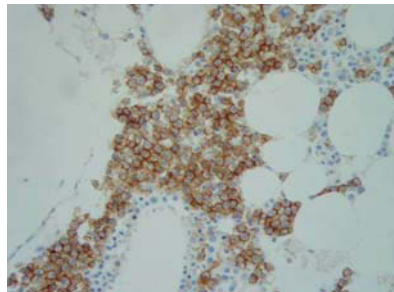


Figure 3. Bone-marrow biopsy (immunohistochemistry with anti-CD117; original magnification, $\times 100$).

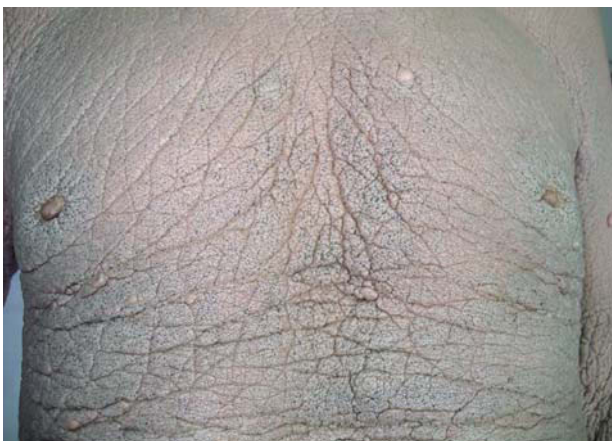


Figure 4. The patient currently presents grayish, indurated skin with numerous comedones.

We present the case of a patient diagnosed with systemic mastocytosis who had been followed up over a long period in our department. The patient's skin had undergone marked, atypical clinical changes during the course of the disease.

Case Description

The patient was a 75-year-old man who had first visited the dermatology department 32 years earlier with yellowish papulonodular lesions, predominately on the torso (Figure 1). The lesions had appeared gradually over the previous 5 years and were accompanied by occasional episodes of itching, tachycardia, and flushing. The patient had no personal or family history of dermatological disease. The results of laboratory tests and a systemic examination were normal. A skin biopsy and staining with hematoxylin-eosin showed dermal aggregates of round or oval monomorphic cells with eosinophilic cytoplasm, and staining with toluidine blue confirmed that the infiltrate contained mast cells. These findings led to a diagnosis of urticaria pigmentosa.

The patient was subjected to follow-up with a complete periodic study that included radiography and bone scintigraphy, laboratory tests, ultrasound of the liver and spleen, and skin biopsies. The results of all studies were similar to those of the initial study, with positive results for staining with toluidine blue and an anti-CD117 antibody (Figure 2). No significant abnormalities were found until the final follow-up visit, in which we detected a monoclonal immunoglobulin G band in serum. We therefore performed a bone-marrow aspiration and biopsy. The aspirate showed a normal cell count but the biopsy revealed dense, well-defined, multifocal infiltrates of typical round CD117⁺ mast cells; this constitutes the most common histological pattern of bone involvement in systemic mastocytosis³ (Figure 3). Serum tryptase levels were normal (7.69 ng/mL; normal range, 3-11 ng/mL).

The patient was also evaluated by the hematology department and diagnosed with indolent systemic mastocytosis.

Over the years, the patient's skin has undergone marked clinical changes and currently presents none of the papular lesions present at the onset of the disease; the skin has taken on an infiltrated, thickened, and generalized pachydermatous appearance that is accentuated in the skin folds, which appear loose and redundant. The patient has also developed numerous comedones and pedunculated fibromas on the back, abdomen, axillae, and groin areas (Figures 4, 5, and 6). Symptoms caused by the release of mast-cell mediators have decreased as a result of treatment with H1 antihistamines (hydroxyzine) and avoidance of precipitating factors.

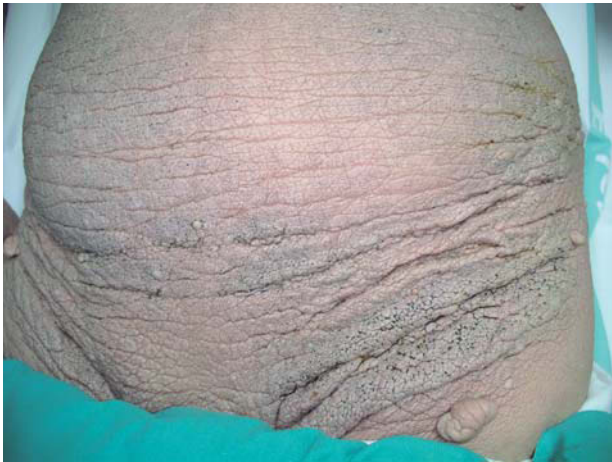

Figure 5. Similar appearance of the skin of the abdomen and groin areas.

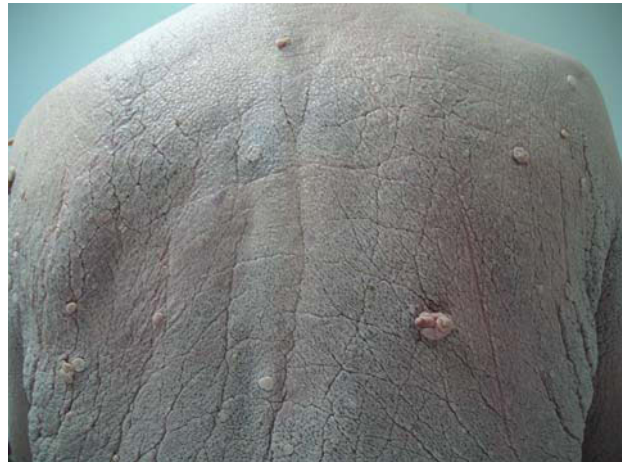

Figura 6. Pedunculated fibromas on the patient's back.

Discussion

Systemic mastocytosis is most commonly diagnosed in adults and is defined by multifocal mast-cell infiltrates in 1 or more organs, not including the skin. Bone-marrow involvement is almost always present in these cases.

In light of recent advances in research into mastocytosis, the World Health Organization proposed a new classification for this group of diseases in 2001.⁴ In general terms, systemic mastocytosis is described as aggressive or malignant when there is an uncontrolled proliferation of immature mast cells in the organs or peripheral circulation that causes functional disorders, whereas indolent is used to describe forms where the disease remains stable and does not cause organ damage.

In many pediatric cases and in practically all adult cases of indolent systemic mastocytosis, skin lesions are the only clinical findings^{5,6} and other signs due to infiltration of the organs by mast cells are not found. Indeed, the morphology of these cells tends to be similar to that of normal mature cells. Determination of serum tryptase levels is the first assay that should be performed in patients with suspected systemic mastocytosis. In many cases of systemic mastocytosis, serum tryptase levels are above 20 ng/mL.^{7,8} High serum tryptase levels alone, however, are not sufficient for a definitive diagnosis of systemic mastocytosis, as these values may also be elevated in patients suffering from non-mast-cell myeloid cancer or severe allergic reaction.⁹

Study of disease extension in adults, including those in whom the disease began prior to puberty, must include bone-marrow aspiration and biopsy.^{10,11} In pediatric patients, however, examination of the bone marrow should only be undertaken if enlarged organs, osteolysis, or abnormalities on examination of peripheral blood are detected.

Patients with indolent systemic mastocytosis tend overwhelmingly to present urticaria pigmentosa lesions. An extremely rare, multinodular, nonpigmented form of the disease, called pseudoxanthomatous mastocytosis, has been described in which the lesions are reminiscent of elastic pseudoxanthoma.¹²

In the initial stages of the disease, our patient presented urticaria pigmentosa skin lesions but the skin underwent marked clinical changes over time while histological findings remained similar. We have only found 1 similar case in the literature, published in 1980 by Meneghini and Angelini.¹³ In that case, the patient was suffering from systemic mastocytosis and developed a pachydermatous skin that the authors compared to crocodile skin in appearance, together with comedones and fibromas. Paradoxically, and as occurred with our patient, worsening of the skin condition was accompanied by improvement of the symptoms and a benign course of the systemic condition. We present this case, which we have called “pachydermatous mastocytosis,” due to the rare nature of the lesions and the atypical course of the skin condition. Only 1 similar case has been described in the literature and we believe that the pachydermatous skin may be secondary to the presence over a number of years of cutaneous mast-cell infiltrates with release of mediators in skin that initially presented urticaria pigmentosa.

References

1. Nettleship E, Tay W. Rare forms of urticaria. *Br Med J.* 1869; 2:323-30.
2. Erlich P. Beiträge zur Kenntnis ders granulierten Bindegewebszellen und der eosino-philen. Leucozyten. *Arch Anat Physiol.* 1879;3:166-9.

3. Horny H-P, Ruck P, Krober S, Kairseling E. Systemic mast cell disease (mastocytosis). General aspects and histopathological diagnosis. *Histol Histopathol.* 1997;12:1081-9.
4. Valent P, Horny H-P, Li CY, Longley JB, Metcalfe DD, Parwaresch RM, et al. Mastocytosis (mast cell disease). World Health Organization (WHO) classification of tumours. Pathology and genetics. In: Jaffe ES, Harris NL, Stein H, Vardiman JW, editors. *Tumours of haematopoietic and lymphoid tissues. Vol 1.* World Health Organization. Lyon, France: IARC Press; 2001. p. 291-302.
5. Angulo J, Ruiz A, González-Guerra E, Vargas I, Fariña MC, Martín L, et al. Mastocytosis del adulto. Descripción de 9 casos clínico-patológicos. *Actas Dermosifiliogr.* 2005;96: 231-6.
6. Wolff K, Komar M, Petzelbauer P. Clinical and histopathological aspects of cutaneous mastocytosis. *Leuk Res.* 2001;25: 519-28.
7. Sperr WR, Jordan JH, Fiegl M, Escribano L, Dimhofer S, Semper H, et al. Serum tryptase levels in patients with mastocytosis: correlation with mast cell burden and implication for defining the category of disease. *Int Arch Allergy Immunol.* 2002;128:136-41.
8. Schwartz LB. Clinical utility of tryptase levels in systemic mastocytosis and associated hematologic disorders. *Leuk Res.* 2001;25:553-62.
9. Schwartz LB, Metcalfe DD, Miller JS, Earl H, Sullivan T. Tryptase levels as an indicator of mast-cell activation in systemic anaphylaxis and mastocytosis. *N Engl J Med.* 1987; 316:1622-6.
10. Escribano L, Bravo P, Cantalapiedra A, Vázquez R, Gárate MT, Díaz B, et al. Aspectos prácticos sobre el diagnóstico y tratamiento de las mastocitosis del adulto. *Actas Dermosifiliogr.* 1999;90:211-23.
11. Horny H-P, Valent P. Diagnosis of mastocytosis: general histopathological aspects, morphological criteria, and immunohistochemical findings. *Leuk Res.* 2001;25:543-51.
12. Jain R, Dogra S, Verma S, Mohanty SK, Handa S. Diffuse cutaneous mastocytosis: pseudoxanthomatous variant. *J Dermatol.* 2002;29:354-6.
13. Meneghini CL, Angelini G. Systemic mastocytosis with diffuse crocodile-like pachydermic skin, pedunculated pseudofibromas and comedones. *Br J Dermatol.* 1980;102: 329-34.