

CASE REPORT

Multiple Eruptive Dermatofibromas in 2 Patients Infected With the Human Immunodeficiency Virus

C García-Millán,^a I Aldanondo,^a M Fernández-Lorente,^a R Carrillo,^b and P Jaén^a

^aServicio de Dermatología and ^bServicio de Anatomía Patológica, Hospital Universitario Ramón y Cajal, Madrid, Spain

Abstract. Multiple eruptive dermatofibromas are an uncommon clinical entity in which several lesions appear in a short period of time. Baraf and Shapiro defined them in 1970 as the appearance of at least 15 dermatofibromas in a few months. Given that incipient cases might be omitted, appearance of 5 to 8 dermatofibromas in 4 months has been proposed as sufficient to establish diagnosis. Although this entity has been reported in healthy subjects, it usually appears with underlying autoimmune diseases (lupus erythematosus), human immunodeficiency virus (HIV) infection, or treatment with certain drugs. We report 2 cases of multiple eruptive dermatofibromas associated with HIV infection. One of these patients was unaware of being infected with HIV, and so we believe that the appearance of these skin lesions could help early diagnosis of autoimmune diseases or patients with immunodepression.

Key words: multiple dermatofibromas, HIV infection, immunodepression

DERMATOFIBROMAS ERUPTIVOS MÚLTIPLES ASOCIADOS AL VIRUS DE LA INMUNODEFICIENCIA HUMANA. PRESENTACIÓN DE DOS CASOS

Resumen. Los dermatofibromas eruptivos múltiples (DFEM) constituyen una entidad clínica infrecuente que consiste en la aparición de varias lesiones en un corto espacio de tiempo. Baraf y Shapiro los definen en 1970 como la aparición de al menos 15 dermatofibromas en pocos meses. Dado que esta cifra podría pasar por alto casos incipientes, se ha propuesto que el hallazgo de 5 a 8 dermatofibromas en 4 meses sea suficiente. Este hallazgo clínico suele aparecer en el contexto de enfermedades autoinmunes (lupus eritematoso) así como en enfermos positivos para el virus de la inmunodeficiencia humana (VIH) o en tratamiento con ciertos fármacos, pero también se han descrito DFEM en pacientes sanos. Presentamos dos casos de dermatofibromas eruptivos múltiples asociados a infección por el VIH, siendo esta condición desconocida previamente en uno de los pacientes, por lo que creemos que la aparición de estas lesiones cutáneas podría ayudar al diagnóstico precoz de enfermedades autoinmunes o situaciones de inmunosupresión.

Palabras clave: dermatofibromas múltiples, infección VIH, inmunosupresión.

Introduction

Dermatofibromas are benign dermal tumors that usually appear on the legs of young women. The expression “multiple eruptive dermatofibromas” has traditionally been used to define the

appearance of at least 15 lesions in the space of a few months.¹ It has recently been accepted that 5 to 8 in less than 4 months is more suitable, as this includes incipient cases.²

Multiple eruptive dermatofibromas are uncommon and have been reported in association with autoimmune conditions, immunosuppressive therapy, neoplasms, organ transplants, and immunodeficiency (HIV).³

We describe 2 patients aged 35 and 45 with multiple eruptive dermatofibroma associated with HIV infection and immunosuppressive therapy. This association is uncommon—in fact, our search of the literature revealed only 10 cases. Exceptionally, in 1 of our patients, the lesions appeared before the underlying disease was diagnosed.

Correspondence:
Cristina García-Millán
Servicio de Dermatología
Hospital Universitario Ramón y Cajal
Carretera de Colmenar km. 9,100
28034 Madrid, Spain
cgmillan@gmail.com

Manuscript accepted for publication November 15, 2006.

Case Descriptions

Case 1

The patient was a 35-year-old woman from Santo Domingo with no clinical history of interest who consulted with a 3-month history of several asymptomatic and hyperpigmented cutaneous lesions on the internal aspect of the left thigh and a solitary lesion on the right thigh. These lesions appeared progressively (Figure 1).

Examination of the left thigh revealed 7 erythematous violaceous nodules measuring between 2 mm and 7 mm in diameter that had an arcuate distribution and were firm on palpation. There was a smaller lesion in the posterior-internal region of the right leg. Dermatoscopy revealed a whitish central structure with irregular borders surrounded by a light brown striated reticulum.

Complete blood count and biochemistry did not reveal abnormalities, except for peripheral thrombocytopenia with 100 000 platelets/mm³ that was not observed in previous checkups (the most recent was 2 years previously). Given that the patient neither presented a systemic condition nor was taking drugs that might have explained the fall in her platelet count, she was screened for HIV infection, as this is one of the most frequent causes of asymptomatic thrombocytopenia between the ages of 20 and 50 years. Two positive enzyme-linked immunosorbent assays were confirmed by Western blot. The patient had a total CD4 lymphocyte count of 500 cells/mm³ and her antinuclear antibodies test result was negative.

Histology of a lesion from the left thigh revealed a poorly delimited dermal nodule containing histiocytes and abundant fibroblasts between thick bundles of collagen. The overlying epidermis was acanthotic and papillomatous with signs of pigmented basaloid cell growth. Immunohistochemistry was positive for factor XIIIa—thus confirming the existence of fibroblasts—and negative for S-100, desmin, and actin.

Case 2

The patient was a 45-year-old man with known HIV infection in stage B2 who had been taking antiretroviral treatment for 1 year. On admission, his total CD4 lymphocyte count was 250 cells/mm³. He was being treated in the gastroenterology department due to upper digestive tract bleeding caused by esophageal varices. The patient was referred to the dermatology department because of multiple cutaneous lesions on the legs suggestive of possible Kaposi sarcoma. The patient was also suffering from cirrhosis of the liver caused by hepatitis C virus and hepatocellular carcinoma that had been diagnosed 6 months before the

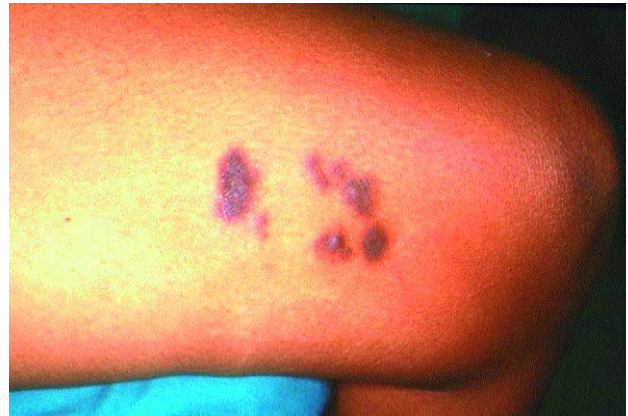

Figure 1. Violaceous erythematous nodules on the internal aspect of the left thigh measuring 2 mm to 7 mm in diameter. They exhibited an arcuate distribution and were firm on palpation.

onset of the cutaneous lesions. This was treated with capecitabine (prodrug of 5-fluorouracil) 2 months before the consultation.

The patient reported the sudden appearance of cutaneous lesions on both legs that had begun progressively after chemotherapy.

The physical examination revealed 10 reddish-brown tumors measuring between 2 mm and 5 mm in diameter on both sides of the legs (Figure 2). Two lesions were observed on the abdomen. Some showed a characteristic depression of the overlying skin on lateral compression.

Additional tests involving a complete blood count, biochemistry, and urinalysis did not provide additional data.

Histology and immunochemistry following biopsy 1 of the lesions revealed similar findings to those of the first patient, thus confirming the fibrohistiocytic origin of the lesions.

Discussion

Dermatofibromas are common benign dermal tumors that usually appear on the legs of young women. The expression “multiple eruptive dermatofibromas” was coined by Baraf and Shapiro¹ in 1970, and has been traditionally used to define the appearance of at least 15 dermatofibromas. More recently, Ammirati et al² stated that the appearance of 5 to 8 dermatofibromas in under 4 months is more suitable, since it includes incipient cases.

Multiple eruptive dermatofibromas are usually more prominent on the legs, as was the case with our patients, although they can appear at other, less common sites, such as the arms³ and between the shoulder blades.⁴

Multiple eruptive dermatofibromas are more prevalent in patients with underlying conditions (56%).⁵ Most cases

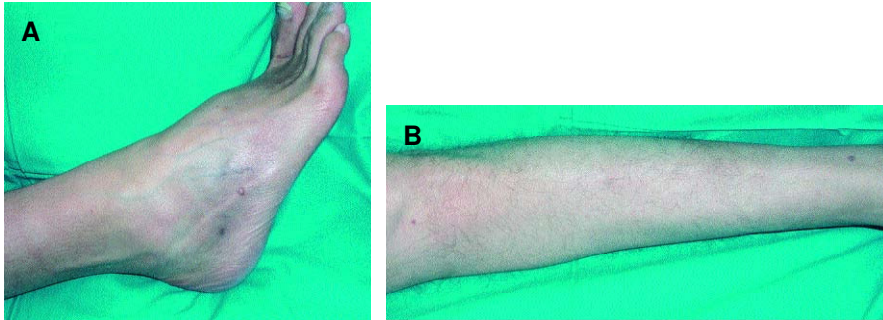


Figure 2. Firm brown disseminated papules measuring 2 mm to 5 mm in diameter on the ankles (A) and pretibial area (B).

are associated with autoimmune diseases treated with immunosuppressants (especially systemic lupus erythematosus, where they have been observed in up to 46% of cases). They are also associated with HIV infection (32%), as occurred in the 2 cases we present, 1 of whose immunosuppression was diagnosed after the appearance of the cutaneous symptoms. This is uncommon, since in the vast majority of cases immunosuppression is known.⁴ We found 10 published cases of multiple eruptive dermatofibroma associated with HIV,^{2,6-12} and 6 of these presented other severe underlying conditions that may have affected the immune response. This may also be affected by treatment with immunosuppressants and antiretroviral therapy, which may precipitate the cutaneous symptoms, as was the case with 1 of our patients. Our literature search did not reveal cases of HIV that began with the appearance of eruptive dermatofibromas (Table).

Other reported associations are obesity, dyslipidemia, pregnancy, and atopic dermatitis, but the high prevalence of some of these conditions leads us to believe that this association is of limited value.

There are familial and congenital cases, and reports of cases associated with ulcerative colitis, acute myeloid leukemia, chronic myeloid leukemia, and transplants.

Recently, the first case of multiple eruptive dermatofibroma associated with Down syndrome was published.¹³

In comparison with classic dermatofibromas, multiple eruptive dermatofibromas present specific clinical, although not histologic, characteristics.⁶ Thus, they generally predominate in men, are grouped together in clusters, and extend to the trunk more often than common dermatofibromas.

Their pathogenesis is still unknown. Traditionally, onset has been attributed to possible injury or insect bite, making them essentially a reactive process. Nevertheless, given their persistent nature, they are currently considered a benign neoplastic process. This theory is supported by the work of Yamamoto et al,^{14,15} who detected alterations in the expression of some fibroblast growth factors. The existence

of familial cases reinforces the idea that there may be an associated genetic component.¹⁶

Mast cells have been considered to play an important role in the pathogenesis of dermatofibromas,¹⁷ given that they are a source of cytokines that interfere with epidermal growth and fibroblast proliferation, as well as with lymphocyte migration. A greater number of mast cells have been detected in multiple eruptive dermatofibromas than in solitary dermatofibromas. It has also been postulated that dermatofibromas are an immunoreactive process mediated by dendritic and other dermal cells.¹⁸ Hence, the development of multiple eruptive dermatofibromas in immunodeficiency could be promoted by the fall in the number of T lymphocytes. Some authors suggest that HIV-associated dermatofibromas could be atypical forms of mycobacteriosis,¹² although this has not been proven. Karkov et al¹⁹ reported the presence of human herpesvirus-8 in the multiple eruptive dermatofibromas of an HIV-infected patient using the polymerase chain reaction, although this finding has been attributed to the presence of the virus in the blood of these patients, since viral replication has not been demonstrated in the lesions.

Differential diagnosis should mainly be with dermatofibrosarcoma protuberans, with which there are clinical, histologic, and immunohistochemical differences. It should also be differentiated from other tumors such as leiomyomas, xanthogranulomas, and Kaposi sarcoma.

These skin alterations may help in the early diagnosis of several diseases involving the immune system, or to identify more severe immunosuppression.

Conflicts of Interest

The authors declare no conflicts of interest.

References

- Baraf CS, Shapiro L. Multiple histiocytomas. Report of a case. *Arch Dermatol.* 1970;101:588-90.

Table. Multiple Eruptive Dermatofibromas Associated With the Human Immunodeficiency Virus

Reference	Sex/Age	Location of Dermatofibromas	No. of Dermatofibromas	HIV-Associated Conditions	Concomitant Treatment	CD4 Count
Ammirati et al ²	M/36	Limbs	7	No	Antiretroviral drugs	94
	M/40	Back	8	No		650
	M/38	Limbs	5	No		600
Kanitakis et al ⁶	M/45	Trunk Legs	>15	Lung cancer	Antiretroviral drugs Radiotherapy	257
Bachmeyer et al ⁷	M/52	Legs	7	Genital herpes	Antiretroviral drugs	600
Murphy et al ⁸	M/24	Trunk, legs	8	HBV	Antiretroviral drugs IFN α	300
Armstrong et al ⁹	M/26	Trunk, legs	8	Psoriasis	Antiretroviral drugs Prednisone UV-B	6
Lu et al ¹⁰	W/33	Trunk, legs	11	Systemic lupus erythematosus	Antiretroviral drugs Steroids	–
Pechere et al ¹¹	M/37	Trunk, legs	7	Disseminated mycobacteriosis	Antiretroviral drugs	5
Silvestre et al ¹²	M/38	Trunk, legs	>15	No	Antiretroviral drugs	–
Current cases	W/35	Limbs	7	No	No	500
	M/45	Limbs	10	HCV Cirrhosis of the liver Hepatocarcinoma	Antiretroviral drugs Capecitabine	250

Abbreviations: HBV, hepatitis B virus; HCV, hepatitis C virus; HIV, human immunodeficiency virus; M, ma; W, woman.

- Amirati CT, Mann C, Homstra IK. Multiple eruptive dermatofibromas in three men with HIV infection. *Dermatology*. 1997;195:344-8.
- Massone C, Pa rodi A, Virno G, Rebora A. Multiple eruptive dermatofibromas in patients with systemic lupus erythematosus treated with prednisone. *Int J Dermatol*. 2002;41:279-81.
- Moreno de Vega MJ, Córdoba S, Sánchez J, Fraga J, García-Díez A. Dermatofibromas múltiples agrupados en región interescapular. *Actas Dermosifilogr*. 1999;90:318-22.
- Niyama S, Katsuoka K, Happle R, Hoffmann R. Multiple eruptive dermatofibromas: a review of the literature. *Acta Derm Venereol*. 2002;82:241-4.
- Kanitakis J, Carbonnel E, Delmonte S, Livrozet JM, Faure M, Claudy A. Multiple eruptive dermatofibromas in a patient with HIV infection: case report and literature review. *J Cutan Pathol*. 2000;27:54-6.
- Bachmeyer C, Cordier F, Blum L, Cazier A, Verola O, Aractingi S. Multiple eruptive dermatofibromas after highly active antiretroviral therapy. *Br J Dermatol*. 2000;143(6):1336-7.
- Murphy S, Lowitt M, Kao G. Multiple eruptive dermatofibroma in an HIV-positive man. *Dermatology*. 1995;190:309.
- Armstrong D, Irvine A, Walsh M, Mayne EE, Burrows D. Multiple dermatofibromas in a patient with HIV infection. *Clin Exp Dermatol*. 1995;20:474.
- Lu I, Cohen P, Grossman M. Multiple dermatofibromas in a woman with HIV infection and systemic lupus erythematosus. *J Am Acad Dermatol*. 1995;32:901.
- Pechere M, Chavaz P, Saurat JH. Multiple eruptive dermatofibromas in an AIDS patient: a new differential diagnosis of Kaposi's sarcoma. *Dermatology*. 1995;190:319.
- Sikestre JF, Bettloch I, Jiménez M. Eruptive dermatofibromas in AIDS patients: a form of mycobacteriosis? *Dermatology*. 1997;194:197.
- Monteagudo B, Álvarez-Fernández JC, Iglesias B, de las Heras C, Cacharrón JM. Multiple eruptive dermatofibromas in a patient with Down's syndrome. *Actas Dermosifilogr*. 2005;96:199.
- Yamamoto T, Katayama I, Nishioka K. Impaired expression of stem cell factor in dermatofibroma fibroblasts. *Acta Derm Venereol*. 1996;76:257-9.
- Yamamoto T, Katayama I, Nishioka K. Possible involvement of interleukin-1 in the pathogenesis of dermatofibroma. *Acta Derm Venereol*. 1998;78:99-102.
- Samlaska C, Bennion S. Eruptive dermatofibromas in a kindred. *Cutis*. 2002;69:187-8.
- Yamamoto T, Katayama I, Nishioka K. Role of mast cells in dermatofibroma: recent viewpoints into the pathogenesis. *Eur J Dermatol*. 2003;13:419-23.

18. Nestle FO, Nickoloff BJ, Burg G. Dermatofibroma: an abortive immunoreactive process mediated by dermal dendritic cells? *Dermatology*. 1995;190:265-8.
19. Kazakov DV, Schmid M, Adams V, Cathomas G, Muller B, Burg G, et al. HHV-8 DNA sequences in the peripheral blood and skin lesions of an HIV-negative patient with multiple eruptive dermatofibromas: implications for the detection of HHV-8 as a diagnostic marker for Kaposi's sarcoma. *Dermatology*. 2003;206:217-21.