



ACADEMIA ESPAÑOLA  
DE DERMATOLOGÍA  
Y VENEREOLOGÍA

# ACTAS Dermo-Sifiliográficas

Full English text available at  
[www.actasdermo.org](http://www.actasdermo.org)



## ORIGINAL ARTICLE

# [Translated article] Outbreak of Dermatophyte Infections on the Head and Neck Related to Shave Haircuts: Description of a Multicenter Case Series

L. Bascón<sup>a</sup>, J.I. Galvañ<sup>b</sup>, I. López-Riquelme<sup>c</sup>, P.J. Navarro-Guillamón<sup>d</sup>, J.M. Morón<sup>e</sup>, J.A. Llamas<sup>c</sup>, M. Ballesteros<sup>f</sup>, A. Tejera-Vaquero<sup>g</sup>, A.G. Angulo<sup>h</sup>, A. Guilabert<sup>a</sup>, J. Romani<sup>a,\*</sup>, on behalf of the study group TCP (Tinea Capitis in Hairdressing)<sup>◇</sup>

<sup>a</sup> Hospital General de Granollers, Granollers, Barcelona, Spain

<sup>b</sup> Práctica Privada, Málaga, Spain

<sup>c</sup> Hospital Regional Universitario de Málaga, Málaga, Spain

<sup>d</sup> Hospital Universitario Virgen de la Victoria, Málaga, Spain

<sup>e</sup> Hospital Nuestra Señora de Valme, Sevilla, Spain

<sup>f</sup> Hospital Clínico Universitario de Valencia, Valencia, España

<sup>g</sup> Instituto Dermatológico Globalderma, Palma del Río, Córdoba, España

<sup>h</sup> Serveis Mèdics Penedès, Barcelona, España

Received 17 January 2023; accepted 2 February 2023

Available online 15 April 2023

### KEYWORDS

*Tinea capitis*;  
*Trichophyton tonsurans*;  
Outbreak;  
Hairdresser;  
Shaving

### Abstract

**Introduction:** Since 2021, an increase in cases of *tinea capitis* has been detected in adolescents who shave their hair with fade haircut.

**Patients and methods:** Multicenter retrospective observational study of cases of cephalic pole dermatophytosis with a history of having been acquired after frequent shaving in hairdressing. A call was made to dermatologists from the Spanish Academy of Dermatology and Venereology (AEDV) to provide cases observed between January 2021 and December 2022. Patients with microbiological confirmation by culture or direct examination with KOH were included.

**Results:** 107 cases were collected, 106 of which were male. 78 non-inflammatory forms were observed, compared to 29 inflammatory. The most frequently isolated fungus was *Trichophyton tonsurans* (75.7% of cases). The lesions appeared predominantly on the nape of the neck and temporal area.

DOI of original article: <https://doi.org/10.1016/j.ad.2023.02.001>

\* Corresponding author.

E-mail address: [xurxoromani@gmail.com](mailto:xurxoromani@gmail.com) (J. Romani).

◇ Members of the TCP (Tinea Capitis in Hairdressing) study group present themselves at the [Annex 1](#).

<https://doi.org/10.1016/j.ad.2023.04.014>

0001-7310/© 2023 AEDV. Published by Elsevier España, S.L.U. This is an open access article under the CC BY-NC-ND license (<http://creativecommons.org/licenses/by-nc-nd/4.0/>).

**PALABRAS CLAVE**

*Tinea capitis*;  
*Trichophyton tonsurans*;  
 Brote;  
 Peluquerías;  
 Rasurado

**Conclusions:** The distribution by sex, age and lesional location seems to indicate that a new social trend, in which male adolescents regularly go to hairdressers to shave the occipital and temporal areas, would be the cause of this grouping of cases of ringworm of the scalp. The most frequent microorganism in our study (*T. tonsurans*) coincides with the most prevalent in our environment. This study shows an accumulation of cases that can be taken into account by competent Public Health agencies, which are responsible for ensuring compliance with the rules of disinfection of the material used for shaving.

© 2023 AEDV. Published by Elsevier España, S.L.U. This is an open access article under the CC BY-NC-ND license (<http://creativecommons.org/licenses/by-nc-nd/4.0/>).

### Brote de dermatofitosis en región de cabeza y cuello asociadas al rasurado en peluquerías: estudio descriptivo multicéntrico de una serie de casos

**Resumen**

**Introducción:** Desde 2021 se ha detectado un aumento de casos de tiñas del cuero cabelludo en adolescentes que se cortan el pelo mediante rasurado o degradado.

**Pacientes y métodos:** Estudio observacional retrospectivo multicéntrico de casos de dermatofitosis del polo cefálico con el antecedente de haber sido contraídas tras el rasurado frecuente en peluquería. Se realizó una llamada a dermatólogos de la Academia Española de Dermatología y Venereología (AEDV) para que aportaran casos observados entre enero de 2021 y diciembre de 2022. Se incluyeron pacientes con confirmación microbiológica mediante cultivo o examen directo con KOH.

**Resultados:** Se recogieron 107 casos, siendo 106 pacientes varones. Se observaron 78 formas no inflamatorias frente a 29 inflamatorias. El hongo aislado con mayor frecuencia fue *Trichophyton tonsurans* (75,7% de los casos). Las lesiones aparecieron predominantemente en la nuca y en el área temporal.

**Conclusiones:** La distribución por sexo, edad y localización lesional parece apuntar a que una nueva tendencia social, en la que adolescentes varones acuden asiduamente a peluquerías para el afeitado de las zonas occipital y temporal, sería la causante de esta agrupación de casos de tiña del cuero cabelludo. El microorganismo más frecuente en nuestro estudio (*T. tonsurans*) coincide con el más prevalente en nuestro medio. Con el presente estudio se evidencia un acúmulo de casos susceptible de ser tenido en cuenta por organismos competentes de salud pública, a los cuales corresponde velar por el cumplimiento de las normas de desinfección del material empleado para el rasurado.

© 2023 AEDV. Publicado por Elsevier España, S.L.U. Este es un artículo Open Access bajo la licencia CC BY-NC-ND (<http://creativecommons.org/licenses/by-nc-nd/4.0/>).

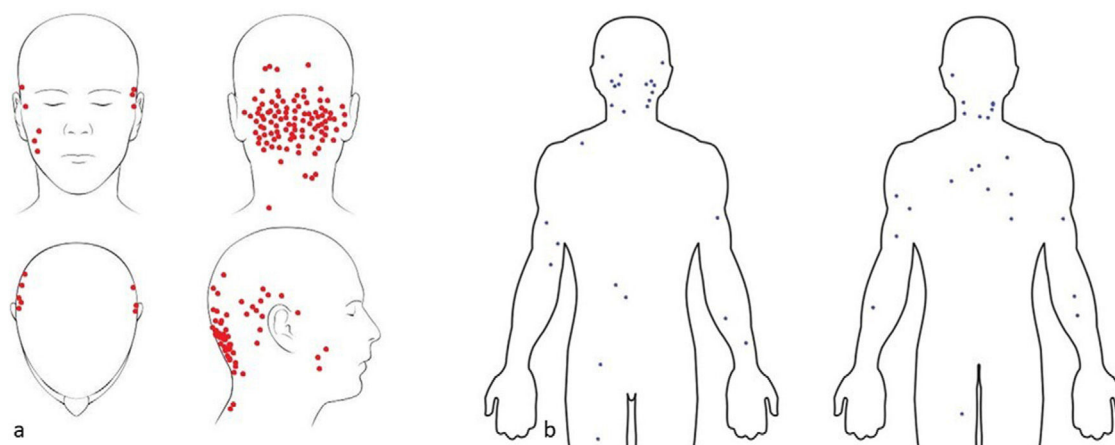
**Introduction**

Ringworm of the scalp, or tinea capitis, is a highly infectious disease that mainly affects children between 6 months and 12 years of age,<sup>1</sup> with a slight predominance in boys.<sup>2</sup> Depending on the route of transmission of the causative fungus of tinea capitis, we can distinguish 3 types of dermatophyte<sup>3</sup>: anthropophilic (including *Trichophyton tonsurans*, *Trichophyton rubrum*, *Trichophyton interdigitale*, *Trichophyton violaceum*, and *Microsporum audouinii*), which generally cause noninflammatory clinical forms; zoophilic (mainly *Trichophyton mentagrophytes*, *Trichophyton verrucosum*, and *Microsporum canis*), which usually cause inflammatory forms, and geophilic (*Microsporum gypseum*), causing moderate inflammation.

The pathogens responsible for tinea capitis vary over time and by geographic region studied. During 19th century and through to the middle of the 20th century, the dominant pathogen in Europe and the United States was the anthropophilic *Microsporum audouinii*,<sup>4</sup> endemic in Africa,<sup>5</sup> followed by the zoophilic *M. canis*.<sup>6</sup> The use of griseofulvin,

along with campaigns to identify and treat infection led to an increase in the prevalence of anthropophilic fungi from the middle of the 20th century, with less infections showing fewer clinical symptoms. Such fungi include *T. tonsurans*, which was endemic originally in Southeast Asia and Australia, before spreading to Central and South America, and from there to Europe and the United States.<sup>7</sup> Currently, in the United States, this fungus is responsible for more than 90% of cases of tinea capitis, with a predilection for people of African origin, with *M. canis* being the second most common causative agent.<sup>3</sup>

In urban areas in Europe, the most common causative agents of tinea capitis are the anthropophilic species (in countries such as Spain, Belgium, or Poland), whereas other areas still have a predominance of zoophilic species, particularly *M. canis* (in countries such as Greece or Germany).<sup>8</sup> Other studies, such as the one conducted in 2016 in Würzburg, Germany,<sup>9</sup> showed that although *M. canis* remained the most frequent causative agent of ringworm of the scalp in that region, other anthropophilic fungi were gaining ground, most notably *T. interdigitale*.



**Figure 1** (A) Initial site of lesions of tinea capitis recorded in the present study, marked with red dots. Note the predominance of areas that are shaved (back of the head and temporal area). (B) Spread to other sites in the present series, marked with blue dots.

Among the studies that report a high current prevalence of *T. tonsurans* in European countries and the Mediterranean basin, there are some conducted in Israel,<sup>4</sup> and one published by Müller et al.,<sup>7</sup> in which 18 young males had tinea capitis or tinea barbae caused by this dermatophyte up to 2 weeks after having had their haircut. We have also observed an increase in cases of ringworm caused by *T. tonsurans* in different parts of Spain in adolescent patients in our clinical practice since 2001. This apparent grouping of cases in time coincides with a new fashion among young Spaniards of shaving their head in the occipital and temporal area every week or twice a month. In light of this clinical observation, we decided to perform a study at the national level to analyze a series of cases of ringworm of the scalp associated with this new social trend.

## Patients and methods

This was an observational, retrospective, multicenter study of cases of dermatophyte infections of the head after a shave haircut at the hairdressers. The study was approved by the Ethics Committee for Drug Research of the Hospital General in Granollers (Barcelona, Spain) (number 2022.042). The cases were reported by dermatologists belonging to the Spanish Academy for Dermatology and Venereology during December 2022, after a call for participation via Dermachat.<sup>10</sup>

The inclusion criteria were microbiological confirmation by direct examination with KOH and/or culture, performed by obtaining sample by skin scraping in the dermatology clinic, and receipt of a shave haircut in a public hairdresser in the 2 weeks prior to the first visit to the clinic. Cases were identified from January 1, 2021, through December 31, 2022.

The variables collected were age, sex, site of initial lesion (back of the head/occipital, temporal/retroauricular, preauricular, facial, and others), spread to other areas, inflammatory versus noninflammatory ringworm, availability of direct examination and/or culture and corresponding result, accompanying clinical symptoms (swollen lymph nodes, fever, pain, others), prior treatments, treatments prescribed, and presence of subsequent indirect contagion.

## Results

Of the 883 dermatologists contacted, 44 responded and provided data on cases. In total, 107 patients were included, 106 of whom were male. The mean age of the patients was 19 years (range 5–40 years). The initial site, with more than one possible at the same time, was back of the head/occipital in 90 cases (84%), temporal/retroauricular in 17 cases (15.8%), facial in 4 (3.7%), periauricular in 2 (1.8%), back in 1 (1%), and not specified in 2 (1.8%) (Fig. 1a). In the majority of cases (65 [60.7%]), infection had not spread to other areas; when it had, the most affected areas are those shown in Fig. 1b.

Inflammatory forms were reported in 29 patients (21.1%) compared with 78 (72.9%) that were not inflammatory. The most frequently reported causative agent in the series was *T. tonsurans*, with 81 confirmed cases (75.7%), followed by *T. rubrum*, *T. mentagrophytes* and *T. verrucosum*, *M. canis*, and *M. audouinii* (Table 1). Of the total 81 cases of ringworm caused by *T. tonsurans*, 22 (27.1%) were inflammatory. Of the total 29 cases of inflammatory ringworm, 21 (72.4%) were caused by *T. tonsurans*.

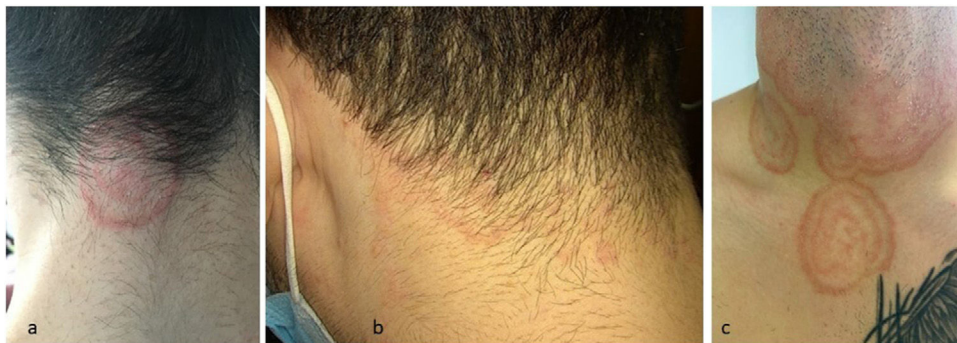Culture was not done in 8 cases (7.4%), while 5 (47%) yielded a negative result. The most common accompanying clinical symptoms were swollen lymph nodes in 25 cases (23.3%), fever in 5 (4.6%), and pain 2 (1.8%). In 16 cases (15%), subsequent indirect contagion to family members or partners of the index cases was reported.

Figs. 2 and 3 show different images of the inflammatory and noninflammatory forms reported in the present study. Fig. 4 shows typical trichoscopic findings of black dots and corkscrew hair, indicative of noninflammatory forms. Fig. 5a shows typical trichophytic patterns on direct examination with KOH, and Fig. 5b an image of an isolate of *T. tonsurans*.

The most widely used treatment was oral terbinafine (250 mg/d) in 92 cases (86%), with a median duration of 2 months (range 1–3 months). Griseofulvin was used in 8 patients (7.4%) and 23 patients (21.4%) also received topical treatment in addition to systemic treatment. Response to treatment was favorable, with complete cure in all cases without any reports of relapse.

**Table 1** Results.

Sex	Male 106 (99.06%) Female 1 (0.9%)
Age	19.7 ± 7.93 years
Site of initial lesion	Back of the head/occipital 90 (84%) Temporal-retroauricular 17 (15.8%) Facial 4 (3.7%) Back 3 (2.8%) Preauricular 2 (1.8%)
Spread to other areas	No 65 (60.7%) Yes 42 (39.3%)
Inflammatory/noninflammatory ringworm	Noninflammatory 78 (72.9%) Inflammatory 29 (27.1%)
Direct vision	Positive 57 (53.2%) No done 46 (42.9%) Negative 4 (3.7%)
Culture	<i>T. tonsurans</i> 81 (75.7%) <i>T. rubrum</i> 2 (1.9%) <i>T. mentagrophytes</i> 2 (1.8%) <i>T. verrucosum</i> 2 (1.9%) <i>M. canis</i> 1 (0.9%) <i>M. audouinii</i> 1 (0.9%) Not done 8 (7.4%) Negative 5 (4.7%)
Accompanying symptoms	None 75 (77.3%) Swollen lymph nodes 25 (23.3%) Fever 5 (4.6%) Pain 2 (1.8%)
Prior treatments (yes/no)	No 52 (48.5%) Not reported 38 (35.5%) Yes 17 (15.8%)
Treatment prescribed	Terbinafine 92 (86%) Griseofulvin 8 (7.4%) Not reported 7 (6.5%)
Subsequent indirect infection (yes/no)	No 91 (85%) Yes 16 (15%)

**Figure 2** (A, B) Noninflammatory forms. (C) Spread to areas away from the initial site.

Fifty-two patients had not received any prior treatment; 17 (15.8%) had applied topical corticosteroids, either on their own initiative or following prescription by the primary care physician, 16 (15%) applied topical antifungal agents, and 5 (5.6%) took systemic antibiotics. There was a relationship between inflammatory forms and previous corticosteroids use.

## Discussion

The present study is the most extensive one of cases of ringworm of the scalp associated with a visit to the hairdressers published to date. The design was retrospective and with a limited number of participating dermatologists. Its objective was not to obtain an estimate of the total number of

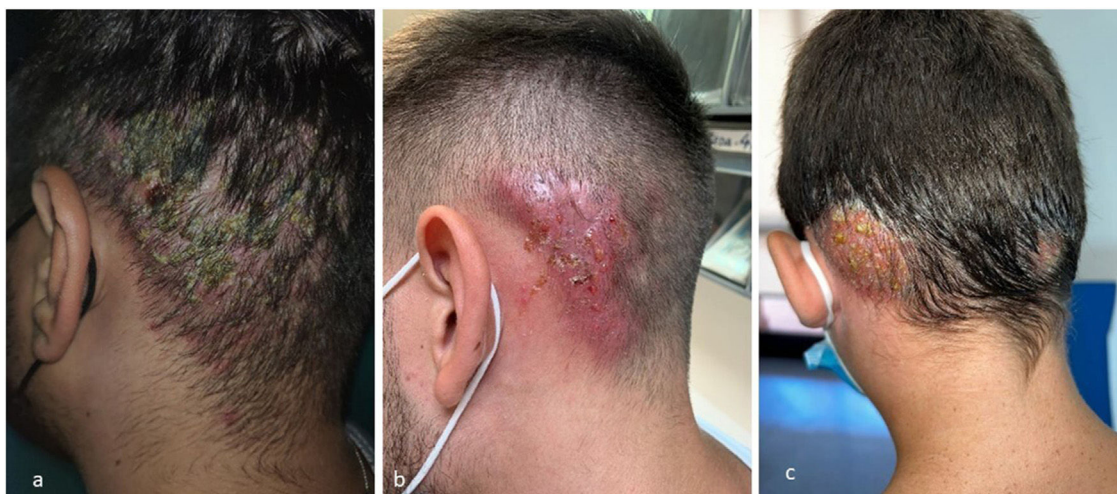

Figure 3 Inflammatory forms.

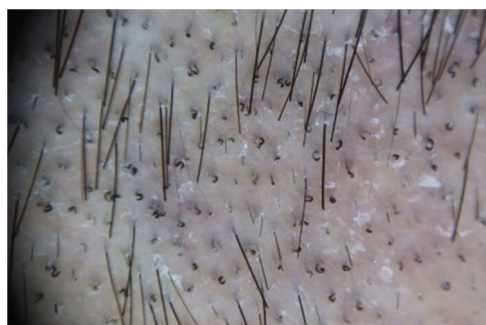

Figure 4 Trichoscopic image of corkscrew hairs, typical of black dot ringworm caused by *T. tonsurans*.

cases in Spain nor the geographic distribution but rather provide a sufficiently representative sample of cases to define the clinical pattern, etiology, and response to treatment. The outbreak affects almost exclusively young males who frequently shave the back of the head and temporal area in

hairdressers, often every week or twice a month, generally on Fridays, to prepare for going out on the weekend. This fashion seems to be a response to the haircuts of certain footballers, Tiktokers, or DJs.<sup>11</sup>

The observation that supports this practice as the cause of the outbreak is the area of the body where the initial lesion appears, which coincides with the most closely shaved hair, and therefore, the greatest contact between the razor and skin. We observed a frequent delay in diagnosis, as well as application of ineffective treatments, including topical corticosteroids, which may lead to rapid dissemination of fungal infection to other areas.

The most frequently isolated agent was *T. tonsurans*, in line with the increasing incidence of this dermatophyte infection in Europe.<sup>7</sup> The cause of the increase in prevalence of ringworm of the scalp due to *T. tonsurans* has not yet been determined. One reason could be that griseofulvin, the only systemic antimycotic agent approved in children, is not as effective as terbinafine in the treatment of trichophyton infection, such as that caused by *T. tonsurans*. As a result, inappropriate therapy could lead

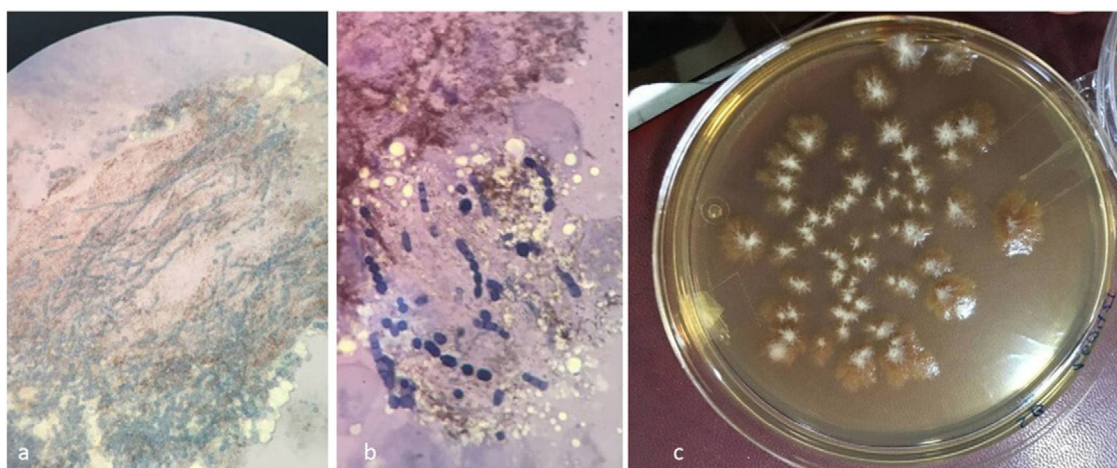


Figure 5 (A) Parasitization in the KOH examination. (B) Septate hyphae and arthroconidia in the KOH examination. (C) Isolate of *T. tonsurans* in glycosylated Sabouraud agar with actidione.

to spread of infection. Only around half of all mycoses caused by *T. tonsurans* have been successfully treated by applying griseofulvin, as terbinafine would be the treatment of choice. In those caused by *T. tonsurans* and *T. schoenleinii*, much longer courses of treatment may be needed and, at times, with full doses (20 mg/kg/d) of griseofulvin.<sup>1</sup>

Although noninflammatory ringworm predominates, as expected when *T. tonsurans* is the causative agent, more than one fourth of ringworm infections caused by *T. tonsurans* in our series were inflammatory, a significant number and in line with that reported for the German outbreak.<sup>7</sup> One possible explanation would that microtraumas during shaving could be associated with more extensive invasion, and therefore, a greater host immune response.

Detailed medical history usually provides important information on the possible origin of the disease in those outbreaks transmitted by contaminated hairdressing utensils. To interrupt the chain of infection, mycological study is urgently indicated for contacts of the index case, as well as antimycotic therapy for asymptomatic carriers of the fungus, who would need to be identified by microbiological tests. In addition, appropriate and constant hygiene measures should be taken with the hairdressing utensils of common use in accordance with the current guidelines that indicate that parts in contact with the skin should be disposable or sterilized in an autoclave.<sup>12</sup> Spores from dermatophytes can persist on inanimate objects (including brushes, towels, cushions, and electric razors). There have even been reports of asymptomatic carriers who have spores in the scalp and who do not develop the disease, but they can transmit the pathogen. In fact, *T. tonsurans* is the dermatophyte species associated with asymptomatic carriers.<sup>13</sup>

In conclusion, the present study describes an emerging epidemiologic situation for which a deeper understanding is necessary with future studies that include information on patients and their contacts, hairdressers, and their hygiene habits, as well as field studies with mycological cultures of material from shaving, and other pertinent actions, in particular, public health education. The high number of cases supposedly transmitted by hairdressing utensils should be taken into account by the corresponding public health bodies, who need to ensure compliance with the established guidelines for disinfection.

## Conflicts of interest

The authors declare that they have no conflicts of interest.

## Annex. Remaining members of the TPC (*Tinea capitis* in hairdressers)

Vicent Alonso, Salomé Álvarez, Asunción Arregui, Belén Civico, Víctor Dios, Patricia Eguino, Andrea Estébanez, Vicente Expósito, Santiago Fernández de Piérola, Patricia Garbayo, Elisabeth Gómez, M. Rosario González-Hermosa, José Herrerías, Helena Izcardo, Ane Jaka, Mar Llamas, Irene López, Miren Marquina, Júlia Mercader, Joan F. Mir, Juan A. Moreno, Juan M. Morón, Carolina Ortuño, Nasser Porras,

Liliana Randazzo, Amparo Sánchez, Júlia Sánchez-Schmidt, Jesús Tercedor, Tomás Toledo, Anna Tuneu, Pedro Vilas, Susana Vildósola, Jorge Adsuar.

## References

- Hay RJ. *Tinea capitis*: current status. *Mycopathologia*. 2017;182:87–93, <http://dx.doi.org/10.1007/s11046-016-0058-8>.
- Mirmirani P, Tucker LY. Epidemiologic trends in pediatric *Tinea capitis*: a population-based study from Kaiser Permanente Northern California. *J Am Acad Dermatol*. 2013;69:916–21, <http://dx.doi.org/10.1016/j.jaad.2013.08.031>.
- Bolognia JL, Schaffer JV, Cerroni L. *Dermatología*. 4th ed. Philadelphia: Elsevier; 2018.
- Friedland R, Reiss-Huss S, Sabbah F, Ben Amitai D. Clinical clues and trends in epidemiology and pathogens in paediatric *Tinea capitis*: a retrospective cohort study. *Clin Exp Dermatol*. 2022;47:50–6, <http://dx.doi.org/10.1111/ced.14831>.
- Lozano-Masdemont B, Carrasco-Fernández B, Polimón-Olabarrieta I, Durán-Valle MT. *Microsporum audouinii*: re-emergence of ringworm due to the dermatophyte [*Microsporum audouinii*: un dermatofito causante de una tiña reemergente]. *Actas Dermosifiliogr (Engl Ed)*. 2019;110:785–7, <http://dx.doi.org/10.1016/j.ad.2018.11.008>.
- Grigoryan KV, Tollefson MM, Olson MA, Newman CC. Pediatric *Tinea capitis* caused by *Trichophyton violaceum* and *Trichophyton soudanense* in Rochester, Minnesota, United States. *Int J Dermatol*. 2019;58:912–5, <http://dx.doi.org/10.1111/ijd.14352>.
- Müller VL, Kappa-Markovi K, Hyun J, Georgas D, Silberfarb G, Paasch U, et al. *Tinea capitis* et barbae caused by *Trichophyton tonsurans*: a retrospective cohort study of an infection chain after shavings in barber shops. *Mycoses*. 2021;64:428–36, <http://dx.doi.org/10.1111/myc.13231>.
- Powell J, Porter E, Field S, O'Connell NH, Carty K, Dunne CP. Epidemiology of dermatomycoses and onychomycoses in Ireland (2001–2020): a single-institution review. *Mycoses*. 2022;65:770–9, <http://dx.doi.org/10.1111/myc.13473>.
- Ziegler W, Lempert S, Goebeler M, Kolb-Mäurer A. *Tinea capitis*: temporal shift in pathogens and epidemiology. *J Dtsch Dermatol Ges*. 2016;14:818–25, <http://dx.doi.org/10.1111/ddg.12885>.
- Martín-Gorgojo A, Bernabeu-Wittel J, Linares-Barrios M, Russo-de la Torre F, García-Doval I, Del Río-de la Torre E. Congreso virtual de dermatología realizado a través de Telegram® durante el confinamiento de la COVID-19: organización y evaluación. *Actas Dermosifiliogr*. 2020;111:852–60, <http://dx.doi.org/10.1016/j.ad.2020.08.009>.
- La nueva costumbre masculina: retoque cada viernes por la tarde en la barbería. *El País*, edición nacional, 2022. Available from: <https://elpais.com/espana/madrid/2022-09-04/viernes-tarde-hora-punta-en-la-barberia.html> [consulted 11.1.23].
- Ordenanza Reguladora de las Condiciones Higiénico Sanitarias y Técnicas de Peluquerías, Institutos de Belleza y otros Servicios de Estética. BO Comunidad de Madrid, 2000. Available from: <https://sede.madrid.es/portal/site/tramites/menuitem.5dd4485239c96e10f7a72106a8a409a0/?vgnnextoid=c2e49d2e3fd-4f010VgnVCM1000009b25680aRCRD&vgnnextchannel=b49ca38813180210VgnVCM100000c90da8c0RCRD&vgnnextfmt=pda> [consulted 11.1.23].
- Ilkit M, Ali Saracli M, Kurdak H, Turac-Bicer A, Yuksel T, Karakas M, et al. Clonal outbreak of *Trichophyton tonsurans* tinea capitis gladiatorum among wrestlers in Adana, Turkey. *Med Mycol*. 2010;48:480–5, <http://dx.doi.org/10.3109/13693780903278051>.