

CASE AND RESEARCH LETTER

[Translated article] Acral Lesions With a Nodular Appearance: A Case Report Illustrating a Complex Differential Diagnosis



Lesiones acrales de aspecto nodular. Un caso que muestra la complejidad del diagnóstico diferencial

To the Editor,

Keratotic nodular and/or papular lesions affecting the hands may correspond to different entities that share clinical and histopathologic findings. The lesions include degenerative collagenous and elastotic plaques of the hands, nodular amyloidosis, colloid milium, acrokeratoelastoidosis, focal-acral hyperkeratosis, and punctate palmoplantar keratoderma. The last 3 conditions differ from the others in that no frank deposits are seen in histopathology.

A 70-year-old Mexican man (resident in Mexico) was assessed for lesions affecting the upper limbs. His history was remarkable for a nonspecified degenerative joint disease and untreated prostatic hyperplasia. He also reported occasionally taking ibuprofen and omeprazole.

Examination revealed a symmetrical rash affecting the dorsum and the edge of the palm of both hands. The lesion comprised yellowish nodules measuring 2–12 mm in diameter. These were well demarcated, yellowish in color, and of firm consistency. The patient reported them to be asymptomatic (Fig. 1). He had used topical sunscreen and taken topical retinoic acid 0.05% for 2 years, albeit with no response.

The initial diagnosis was colloid milium or acrokeratoelastoidosis. The histology workup of a punch biopsy specimen taken from one of the lesions revealed an epidermis with irregular acanthosis of the interpapillary ridges and a hyperkeratotic stratum compactum. The papillary and superficial dermis were characterized by deposition of abundant eosinophilic material. This was smooth with

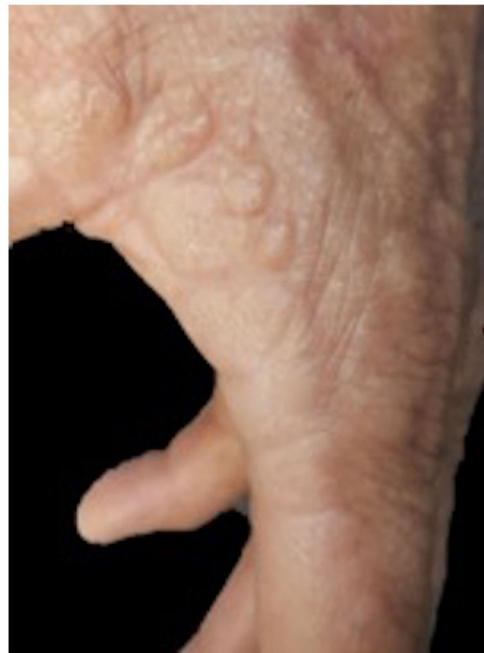

Figure 1 Clinical image. Note the lesions with a nodular appearance at the juncture of the palmar and dorsal skin of the left hand.

clefts, surrounded some blood vessels, and was separated from the epidermis by a Grenz zone. A moderate perivascular inflammatory infiltrate composed mainly of lymphocytes was visible in the superficial and mid dermis (Fig. 2). No sweat gland abnormalities were observed.

The deposit was stained with periodic acid–Schiff and Verhoeff–van Gieson and Grocott, which stain elastic fibers (Fig. 3). Crystal violet staining was focally positive. Immunohistostaining for the κ and λ chains was negative.

The patient received 3 cryotherapy sessions, which partially improved the lesion.

Nodular and papular lesions of the hands pose a diagnostic challenge owing to the multiple clinical conditions the dermatologist and histopathologist must address. The differential diagnosis includes degenerative collagenous and

DOI of original article:

<https://doi.org/10.1016/j.ad.2021.08.018>

<https://doi.org/10.1016/j.ad.2023.04.011>

0001-7310/© 2022 AEDV. Published by Elsevier España, S.L.U. This is an open access article under the CC BY-NC-ND license (<http://creativecommons.org/licenses/by-nc-nd/4.0/>).

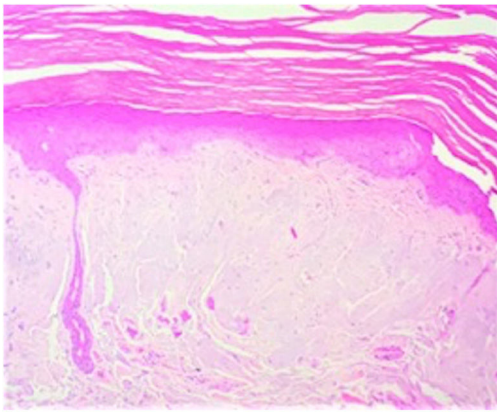


Figure 2 Histopathology. Note the deposition of material in the superficial dermis. Hematoxylin–eosin, $\times 20$.

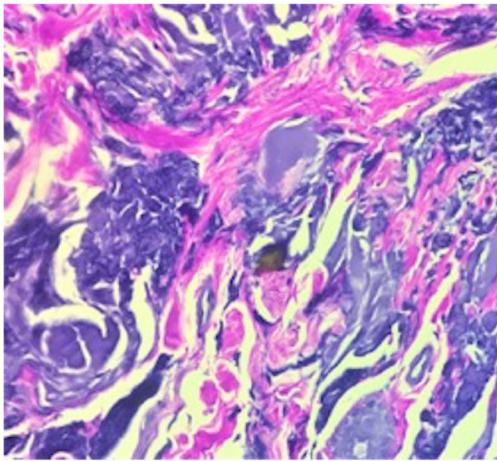


Figure 3 Staining of elastic fibers with Verhoeff–van Gieson, $\times 60$.

elastotic plaques of the hands, an uncommon condition first described in 1960 by Burks et al.¹ and that is characterized by the presence of keratotic translucent papules at the juncture of the palmar and dorsal skin.² It has been associated with UV radiation and repetitive injury.¹ The very few cases that have been reported are referred to by different names and histopathologic presentations. The lesions are found mainly on the internal margin of the thumb, from where they extend to the edge of the interdigital space and the radial aspect of the index finger.³ Histologically, they are characterized by the presence of numerous thickened collagen bundles interlaced with elastic fibers and an amorphous basophilic material in the reticular dermis.⁴

The differential diagnosis also includes colloid milium, a rare cutaneous deposition disorder that was first described in 1866 by Wagner.⁵ While the exact etiology remains unknown, it is thought to result from degeneration of collagen and elastic fibers after prolonged sun exposure, leading to the formation of protein residue clusters.⁶ The 4 subtypes of colloid milium comprise adult, juvenile, nodular, and pigmented. The adult type is the most common and is characterized clinically by multiple papules that differ in size and are yellowish-pink in color. They are symmetrical and slow-growing and generally affect sun-exposed areas, such as the face, neck, and hands.⁷ Considered essential for diagnosis, histopathology reveals pale, homogeneous, amorphous cleaved eosinophilic material located in the papillary dermis with a background of solar elastosis.⁶ Adult colloid milium stains positive for periodic acid–Schiff and Congo red, although the reaction for the latter is weaker.⁸

Nodular amyloidosis is an uncommon form of primary cutaneous amyloidosis, in which amyloid material comes from immunoglobulin light chains produced by plasma cells. It is a differential diagnosis for nodular lesions affecting the hands. Clinically, it is characterized by yellowish-brown plaques, papules, or nodules that appear on the head, trunk, arms, legs, and genitals.⁹ Histopathology reveals large amyloid deposits in the dermis and subcutaneous cellular tissue accompanied by a perivascular lymphoplasmacytic infiltrate. The amyloid material stands out in light chain immunohistochemistry.¹⁰ Special stains are generally necessary to distinguish between colloid milium and nodular amyloidosis. Van Gieson staining can prove helpful, since it stains the colloid material yellow and the amyloid material red. Electron microscopy is the definitive test for distinguishing between both conditions.⁹

Table 1 summarizes the clinical, histopathologic, and therapeutic differences between all 3 entities.

In the case we present, the diagnosis was confirmed by the correlation between clinical and histopathologic findings, which is supported to a large extent by immunohistochemistry. The clinical distribution of the lesions, which was similar to that described previously, enabled us to distinguish the condition from colloid milium.³ Nodular amyloidosis was ruled out through the absence of amyloid deposit, which in the present case was confirmed by inconclusive crystal violet staining and negative immunohistochemistry findings.

The diagnosis of degenerative collagenous and elastotic plaques of the hands is supported by its limitation to the hands and elastic fiber abnormalities in histopathology. However, as elastic fiber abnormalities are also reported in colloid milium, we might consider whether the latter is a clinical type of the former.

Table 1 Clinical, Histopathologic, and Treatment-Related Differences in Acral Dermatoses.

	Nodular amyloidosis	Colloid milium	Degenerative collagenous and elastotic plaques of the hands
Etiology	Deposits of immunoglobulin light chains produced by local plasma cells Associated with trauma, sarcoidosis, and autoimmune disease	Results from degeneration of collagen and elastic fibers that leads to accumulation of protein residues Associated with hydroquinone (pigmented type), ochronosis, trauma, long-term exposure to fertilizer and oil derivatives	Possible causes: repetitive injury and actinic damage
Symptoms	Sixth and seventh decades. No predilection for sex. Red-yellowish plaques, papules, or nodules on the legs, head, trunk, arms, and genitals	Children and adults Translucent yellowish-pink nodules of various sizes. Sun-exposed areas (cheeks, dorsum of the hand, neck, and pinna). Progresses slowly and symmetrically	Peak incidence at 50 y Often affects the hands, symmetrical and linear distribution on the interdigital folds, lesions characterized by waxy, yellowish nodules/plaques
Clinical forms	Macular Lichenoid Nodular	Classic (adult) Juvenile Pigmented Nodular	
Histopathology	Amyloid deposit throughout the thickness of the dermis and subcutaneous cellular tissue, vessels with lymphoplasmacytic infiltrate. Immunohistochemistry for immunoglobulin light chains (λ subtype is most frequent) β_2 microglobulin also reported	Amorphous, homogeneous, cleaved eosinophilic material in the superficial and mid dermis and a background of solar elastosis. Positive for Congo red, crystal violet, and PAS. Negative for Alcian blue. Negative under polarized microscopy Van Gieson staining helps to distinguish amyloid material (red) from colloid material (yellow)	Homogeneous, disorganized, amorphous basophilic material interlaced with fibrillar elastotic material in the superficial and mid reticular dermis Hypocellularity can be observed Positive staining for elastic fibers Acrokeratoelastoidosis (rare variant of palmoplantar keratoderma that may occur sporadically or as autosomal dominant genodermatosis) Actinic elastosis
Differential diagnoses	Gouty tophi, lipid proteinosis, colloid milium, erythropoietic protoporphyria Iodine 123 scintigraphy for amyloid P can prove useful	Sarcoidosis Favre-Racouchot syndrome Trichoepithelioma Syringoma Sebaceous hyperplasia	
Treatment	Electrodesiccation Curettage Cryotherapy Intralesional corticosteroids Dermabrasion CO ₂ and YAG laser	Topical retinoids Systemic ascorbic acid Dermabrasion Chemical peeling Cryotherapy Phototherapy CO ₂ and YAG laser	

Abbreviations: PAS, periodic acid–Schiff; YAG, yttrium aluminum garnet.

Funding

The authors declare that no funding was received for this publication.

Conflicts of Interest

The authors declare that they have no conflicts of interest.

References

- Burks JW, Wise LJ Jr, Clark WH Jr. Degenerative collagenous plaques of the hands. *Arch Dermatol*. 1960;82:362–6.
- Sánchez-Mateos D, Jo-Velasco M, Alegría-Landa V, Fariña-Sabaris MC, Requena L. Acrolocalized variant of lichen sclerosus initially manifesting as degenerative collagenous plaques of the hands. *J Cutan Pathol*. 2019;47:269–74.
- Awad RP, Wolf AA, Sazunic YI. ¿Cuál es su diagnóstico? *Rev Chilena Dermatol*. 2012;28:471–3.
- Sehgal VN, Singh M, Korrane RV, Nayyar M, Chandra M. Degenerative collagenous plaque of the hand (linear keratoelastoidosis of the hands). A variant of acrokeratoelastosis. *Dermatologica*. 1980;161:200–4.
- Navarrete Franco G, Morales Barrera M, Peralta Cordero G. Miliun coloide del adulto. *Dermatología Rev Mex*. 2008;52:192–4.
- Dávila-Rodríguez J, Aguilar K, García L. Colloid milium, an expression of excessive sun exposure in Ecuadorian patients. *Int J Dermatol*. 2019;58:E80–2.
- Liu H, Lin Y, Chen X, Wang N, Shan X, Tian H, et al. Evaluation of colloid milium by in vivo reflectance confocal microscopy. *J Eur Acad Dermatol Venereol*. 2013;27:262–3.
- Ghanadan A, Kamyab K, Daneshpajouh M, et al. Nodular colloid degeneration of the skin: report of three cases with review and update. *Int Dermatol J*. 2014;5:36.
- Cornejo K, Lagana F, Deng A. Nodular amyloidosis derived from keratinocytes. *Am J Dermatopathol*. 2015;37:e129–33.
- Souza Junior J, Schettini RA, Tupinamba WL, et al. Localized primary cutaneous nodular amyloidosis: case report. *An Bras Dermatol*. 2011;86:987–90 [in English, Portuguese].

I.Y. Osorio-Aragón^a, J.J. Salazar del Valle^b,
G.I. Quintero Valle^b, R. Arenas^c, M.E. Vega-Memije^{a,*}

^a *Departamento de Dermatopatología, Hospital General Dr. Manuel Gea González, Ciudad de México, Mexico*

^b *Servicio de Dermatología, Hospital San Javier, Guadalajara Jalisco, Mexico*

^c *Sección de Micología, Hospital General Dr. Manuel Gea González, Ciudad de México, Mexico*

* Corresponding author.

E-mail address: elisavega50@gmail.com

(M.E. Vega-Memije).