

CASE AND RESEARCH LETTER

[Translated article] Digital Clubbing: Ultrasound Findings



Ecografía de acropaquia digital

To the Editor,

Digital clubbing refers to focal enlargement of connective tissue at the distal phalanges of fingers or toes. It is particularly prominent on dorsal surfaces and is often bilateral. Clinically, it is characterized by an increased Lovibond angle, which is the angle made by the proximal nail fold and the nail plate and normally measures 160° or less (Fig. 1a). In clubbing, it is larger than 180° , forming what is known as the Schamroth sign. The most common causes of digital clubbing are pulmonary (75%–80% of cases), cardiac (10%–15%), gastrointestinal (5%–10%), and thyroid (among others).

Ultrasound is a useful tool for evaluating the anatomy and structures of the nail unit as these show different degrees of echogenicity. In addition, Doppler measurements are helpful for assessing the vascularization of the nail matrix and nail bed. Ultrasound imaging has been used to characterize abnormalities observed in nail psoriasis and tumors of the nail and surrounding tissues, as well as nail changes in patients with autoimmune, infectious, and inflammatory diseases.^{1–4}

In this report, we describe ultrasound findings observed in a patient with digital clubbing.

Case report

A 46-year-old male smoker presented with hand eczema of 2 weeks' duration and paronychia secondary to onychophagia. The physical examination revealed clubbing (Fig. 1b), which the patient said had been present since childhood; he denied a family history of nail abnormalities and reported no pain or mechanical symptoms.

We studied the nail unit using high-frequency ultrasound with a 10–22 MHz linear probe connected to an Esaote MyLab Class C system. The longitudinal view revealed an enlarged nail bed, with a diameter of 3 mm (normal measurements are ≤ 2 mm [Fig. 2a]), and increased vascularization through the full thickness of the bed. No alterations were observed in the bone surface of the distal phalanx (Fig. 2b).

Comment

The most widely accepted pathophysiologic hypothesis to explain clubbing is proliferation of vascular connective tissue due to platelets and platelet-derived growth factors (PDGFs). In the case of pulmonary diseases, it is assumed that circulating megakaryocytes cross from venous blood

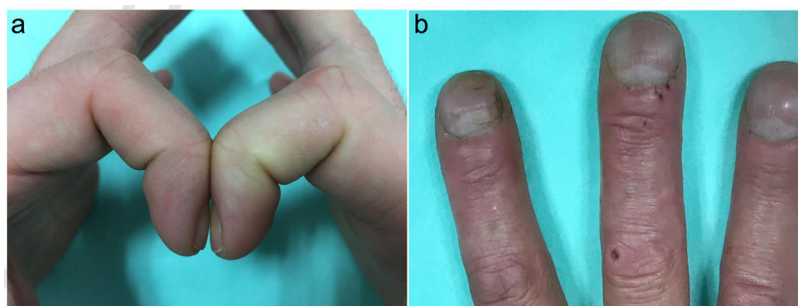


Figure 1 (a) Normal nail, Lovibond angle $<160^\circ$. (b) Digital clubbing.

DOI of original article:

<https://doi.org/10.1016/j.ad.2020.05.018>

<https://doi.org/10.1016/j.ad.2020.05.026>

0001-7310/© 2021 AEDV. Published by Elsevier España, S.L.U. This is an open access article under the CC BY-NC-ND license (<http://creativecommons.org/licenses/by-nc-nd/4.0/>).

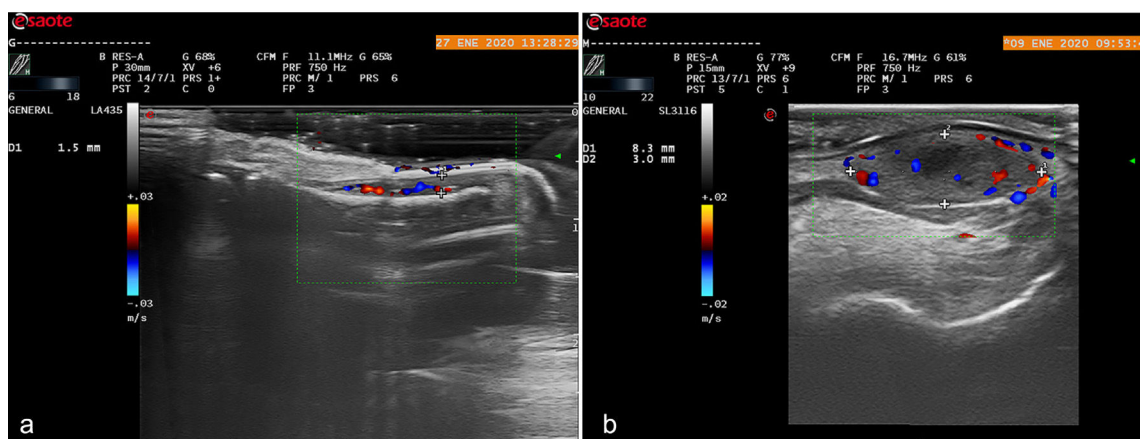


Figure 2 (a) High-frequency ultrasound showing a normal nail in the longitudinal plane. (b) Similar image of the distal phalanx. Note the thickened nail bed and increased vascularization.

to arterial blood and are delivered to the extremities, where they release growth factors such as PDGFs. Normally, megakaryocytes do not fragment until they are trapped in the pulmonary capillaries, which is why clubbing is mainly associated with pulmonary diseases.^{5–7}

Clubbing must be distinguished from pachyperiostitis, which is clinically characterized by subperiosteal bone neoformation associated with pain (hypertrophic osteoarthropathy), polyarthritits, cutis verticis gyrata, pachydermia, seborrhea, and hyperhidrosis.^{8,9} None of these features were observed in our patient. Ultrasound findings in pachyperiostitis include echogenic tissue surrounding the long bones, reflecting the presence of edema and inflammation. Doppler imaging shows increased vascularization on the surface of some superficial bony structures.^{10,11}

Cutaneous ultrasound is an inexpensive, rapidly accessible, noninvasive tool for exploring the anatomy of the nail unit. In addition, it is useful for distinguishing between clubbing and pachyperiostitis without the need for ionizing radiation. Underlying disease must always be ruled out in such cases.

This is the first case in the literature to describe ultrasound findings in a patient with digital clubbing.

Conflicts of interest

The authors declare that they have no conflicts of interest.

References

1. Wortsman X, Jemec GB. Ultrasound imaging of nails. *Dermatol Clin.* 2006;24:323–8.
2. Alfageme F. *Manual de ecografía cutánea*. 1.^a ed. Charleston: Create Space Independent Platform Publisher; 2014.
3. Wortsman X, Wortsman J, Soto R, Saavedra T, Honeyman J, Sazunic I, et al. Benign tumors and pseudotumors of the nail:

a novel application of sonography. *J Ultrasound Med.* 2010;29:803–16.

4. Gómez-Sánchez M, Alfageme-Roldán F, Roustán-Gullón M, Segurado-Rodríguez M. Tumores glómicos digitales y extradigitales. Utilidad de la ecografía cutánea. *Actas Dermosifiliogr.* 2014;105:e45–9.
5. Myers KA, Farquhar DR. The rational clinical examination. Does this patient have clubbing? *JAMA.* 2001;286:341–7.
6. Spicknall KE, Zirwas MJ, English JC 3rd. Clubbing: An update on diagnosis, differential diagnosis, pathophysiology, and clinical relevance. *J Am Acad Dermatol.* 2005;52:1020–8.
7. Currie AE, Gallagher PJ. The pathology of clubbing: vascular changes in the nail bed. *Br J Dis Chest.* 1988;82:382–5.
8. Silveira LH, Martínez-Lavin M, Pineda C. Vascular endothelial growth factor and hypertrophic osteoarthropathy. *Clin Exp Rheumatol.* 2000;18:57–62.
9. Rimoin DL. Pachydermoperiostosis (idiopathic clubbing and periostosis). Genetic and physiologic considerations. *N Engl J Med.* 1965;272:923–31.
10. Uribe-Valencia MA, Ocampo JM, Parra-Camarillo M. Digital clubbing: knowing its causes. Case report. *Rev Fac Med.* 2019;67:355–8.
11. Adams B, Amin T, Leone V, Wood M, Kraft JK. Primary hypertrophic osteoarthropathy: ultrasound and MRI findings. *Pediatr Radiol.* 2016;46:727–30.

C. Fernández-Quiroga^{a,*}, F. Alfageme-Roldán^b,
G. Roustán-Gullón^b

^a *Unidad de Dermatología, Hospital General de Agudos Carlos G. Durand, Ciudad Autónoma de Buenos Aires, Argentina*

^b *Servicio de Dermatología, Hospital Universitario Puerta de Hierro-Majadahonda, Majadahonda, Madrid, Spain*

* Corresponding author.

E-mail address: drafernandezquiroga@gmail.com (C. Fernández-Quiroga).