



ACTAS Dermo-Sifiliográficas

Full English text available at
www.actasdermo.org



BRIEF COMMUNICATION

Series of Fourteen Cases of Topical Imiquimod 5% in Lentigo Maligna: Treatment Modalities and Clues for Detecting Recurrences



I. Poveda-Montoyo^{a,*}, P. Álvarez-Chinchilla^a, L. Schneller-Pavelescu^a, P. Hispán-Ocete^a, J. Bañuls-Roca^{a,b}

^a Departamento de Dermatología, Hospital General Universitario de Alicante, Instituto de Investigación Sanitaria y Biomédica de Alicante (ISABIAL), Alicante, Spain

^b Unidad de Dermatología Área, Departamento de Medicina Clínica, Universidad Miguel Hernández, Sant Joan de Alicante, Alicante, Spain

KEYWORDS

Lentigo maligna;
Melanoma;
Imiquimod;
Treatment;
Recurrence;
Dermoscopy

Abstract Topical imiquimod has been used off-label as monotherapy or adjuvant treatment for lentigo maligna. Our aim is to describe treatment modalities, clinical outcomes, and management of recurrence in patients receiving imiquimod for lentigo maligna.

Patients from our unit with lentigo maligna or lentigo maligna melanoma treated with imiquimod 5% as monotherapy or in combination with surgery were included in this study.

Fourteen cases were recruited (85.7% lentigo maligna and 14.3% lentigo maligna melanoma). Eight patients (57.1%) received imiquimod without surgery, and six (42.9%) underwent narrow excision before beginning treatment. During the follow-up period, pigmentation reappeared in 6 patients (4 postinflammatory hyperpigmentation and 2 relapses). Relapses were managed with very narrow excision (1 mm margin) and retreatment with imiquimod 5%.

All imiquimod modalities showed well-tolerated side effects and low recurrence rates, with long periods of follow-up. Imiquimod appears to be a versatile option for treating LM in suitable candidates.

© 2022 AEDV. Published by Elsevier España, S.L.U. This is an open access article under the CC BY-NC-ND license (<http://creativecommons.org/licenses/by-nc-nd/4.0/>).

* Corresponding author.

E-mail address: inespovedamontoyo@gmail.com (I. Poveda-Montoyo).

PALABRAS CLAVE

Lentigo maligno;
Melanoma;
Imiquimod;
Tratamiento;
Recidiva;
Dermatoscopia

Serie de 14 casos de tratamiento con imiquimod tópico al 5% en lentigo maligno: modalidades terapéuticas y claves para detectar recidivas

Resumen Imiquimod tópico ha sido utilizado como monoterapia o tratamiento adyuvante fuera de indicación para el lentigo maligno (LM). Nuestro objetivo es describir las modalidades de tratamiento, los resultados clínicos y el manejo de la recidiva en los pacientes que reciben imiquimod para lentigo maligno.

Se incluyó en este estudio a los pacientes de nuestra unidad con lentigo maligno o lentigo maligno melanoma tratados con imiquimod 5% en régimen de monoterapia o junto con cirugía.

Se seleccionaron 14 casos (el 85,7% de lentigo maligno y el 14,3% de lentigo maligno melanoma). Ocho pacientes (57,1%) recibieron imiquimod sin cirugía, y seis (42,9%) fueron sometidos a resección antes de iniciar el tratamiento. Durante el periodo de seguimiento, reapareció la pigmentación en seis pacientes (cuatro con hiperpigmentación postinflamatoria y dos recidivas). Las recidivas fueron tratadas con un margen de resección muy estrecho (1 mm) y retratamiento con imiquimod 5%.

Todas las modalidades de imiquimod reflejaron buena tolerancia de efectos secundarios y bajas tasas de recidiva. Imiquimod parece ser una opción muy versátil para tratar LM en candidatos idóneos.

© 2022 AEDV. Publicado por Elsevier España, S.L.U. Este es un artículo Open Access bajo la licencia CC BY-NC-ND (<http://creativecommons.org/licenses/by-nc-nd/4.0/>).

Introduction

Lentigo maligna (LM) is the preinvasive phase of lentigo maligna melanoma (LMM).¹ Surgery is considered its standard treatment.^{2,3} The main non-surgical techniques for LM are radiotherapy, laser, cryotherapy, and imiquimod.^{2,4}

Imiquimod has been used off-label for LM, as a monotherapy or adjuvant treatment.¹⁻⁹ However, there is little information about immediate post-treatment signs, or the detection and management of recurrences. Our aim is to describe our patients treated with imiquimod for LM, with regard to treatment modalities, clinical outcomes, recurrences and adverse effects associated.

Patients and methods

We included all patients from 2006 to 2019 from the Melanoma Unit of our hospital with histological confirmation of LM or LMM treated with imiquimod 5%, alone or as adjuvant.

All patients had been prescribed topical imiquimod, once a day on the lesion and 1 cm around, and 1 cm around the scar in excised lesions. The duration of the treatment varied from 5 to 11 weeks, at least until achieving the desired level of inflammation (erythema with erosions and crusts) and, if not, tazarotene gel 0.05% was added to increase it. One dermatologist (JB) followed the patients every two weeks during the treatment period and then every six months. At each visit, patients underwent close clinical examination, photographic controls and digital dermoscopy.

Variables collected were clinical data (sex, age, location), surgery status, imiquimod regimen, inflammatory reaction, length of follow-up, and reappearance of pigmentation (recurrence or postinflammatory hyperpigmentation).

In all cases, we informed patients that the prescription of imiquimod was off-label and the different alternative treatments available. Informed consent was obtained from all patients.

Results

We included 14 cases in our study. **Table 1** presents sample characteristics. Eleven patients (78.6%) were women. Mean age at disease onset was 69.5 years. Lesions appeared most commonly on the nose (35.7%) and cheeks (28.6%). Twelve participants (85.7%) had a histological diagnosis of LM and two (14.3%) of LMM.

Eight patients (57.1%) received imiquimod without surgery. Of these, three (37.5%) required tazarotene gel 0.05%. Six patients (42.9%, 4 LM and 2 LMM) underwent narrow excision (included the infiltrative component of LMM) followed by imiquimod treatment. One patient received tazarotene.

Imiquimod was applied for a mean of seven weeks. A regular adverse effect was intense erythema with crust (**Fig. 1A–D**). Four patients (28.6%) had a non-infectious conjunctivitis and in one case a transient ectropion due to inflammation. Solar lentigos disappeared on the treated skin.

Mean post-treatment follow-up was 66.4 months. Four cases of postinflammatory hyperpigmentation (**Fig. 1E–G**) were observed and resolved spontaneously within a few weeks. Otherwise, we detected two histologically confirmed relapses, both in patients with imiquimod in monotherapy. The mean time to recurrence was 10 months. Relapses (**Fig. 1H–I**) were managed successfully with an excision with one millimeter margin and retreatment with imiquimod for seven weeks.

Table 1 Case series of imiquimod in lentigo maligna: treatment modalities, and characteristics of the patients.

	Sex ^a	Age (years)	Tumor site	Associated infiltrative component	Other treatments	Imiquimod regimen	Post-treatment follow-up (months)	Evolution and management of the relapses
<i>Monotherapy with imiquimod 5%</i>								
1	F	63	Nose	No	No	Daily 8 weeks	147	-
2	F	76	Right cheek	No	Tazarotene 0.05% gel	Daily 7 weeks	56	Self-limited postinflammatory hyperpigmentation
3	F	84	Left cheek	No	Tazarotene 0.05% gel	Daily 6 weeks	55	-
4	F	68	Back	No	No	Daily 8 weeks	131	-
5	M	53	Nose	No	No	Daily 8 weeks	68 54 following re-treatment	Relapse at 18 months; managed with adjusted excision + 7 weeks imiquimod 5%
6	F	77	Nose	No	No	Daily 5 weeks	85	-
7	M	76	Left paranasal	No	No	Daily 6 weeks	37 36 following re-treatment	Relapse at 2 months; managed with adjusted excision + 7 weeks imiquimod 5%
8	F	72	Nose	No	tazarotene 0,05% gel	Daily 11 weeks	37	Self-limited postinflammatory hyperpigmentation
<i>Imiquimod 5% + narrow excision</i>								

Table 1 (Continued)

	Sex ^a	Age (years)	Tumor site	Associated infiltrative component	Other treatments	Imiquimod regimen	Post-treatment follow-up (months)	Evolution and management of the relapses
9	F	81	Right cheek	Yes 0.47 mm	No	Daily 7 weeks	58	Self-limited postinflammatory hyperpigmentation
10	F	67	Left cheek	No	No	Daily 6 weeks	44	Self-limited postinflammatory hyperpigmentation
11	M	67	Nose	No	No	Daily 8 weeks	59	-
12	F	48	Right temple	No	No	Daily 6 weeks	80	-
13	F	66	Left temple	No	Tazarotene 0.05% gel	Daily 8 weeks	36	-
14	F	75	Upper lip	Yes 0.2 mm	No	Daily 5 weeks	38	-

^a Sex: F: female, M = male.

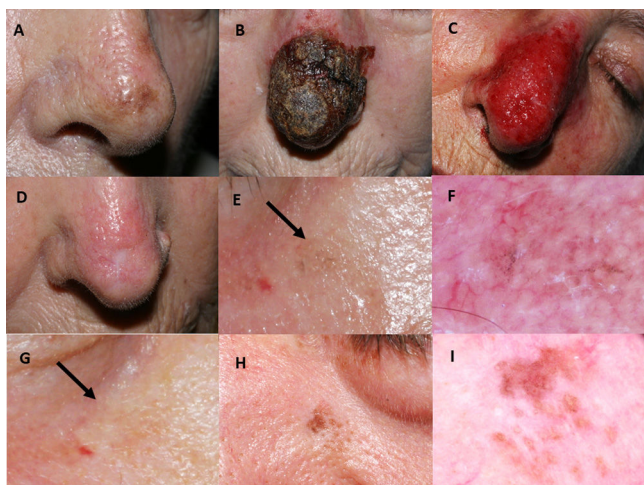


Figure 1 Imiquimod treatment in a lentigo maligna located on the nasal tip in a 77-year-old female (patient 1, see Table 1): (A) Pretreatment; (B) Intense inflammatory reaction during treatment with a thick black hemorrhagic crust; (C) Intense erythema and edema after removing scabs; (D) Resolution following the end of treatment. A residual scar due to the previous skin biopsy is present. 76-year-old female, who had received treatment with 5% imiquimod in monotherapy for a lentigo maligna lesion on her right cheek with self-limited postinflammatory hyperpigmentation (patient 2, see Table 1): (E) Slight gray pigmentation, black arrow; (F) In this dermoscopic photograph, grayish annular-granular structures around the follicles (peppering); (G) Spontaneous disappearance of pigmentation after several weeks, black arrow. 76-year-old man who had a relapse of lentigo maligna at 2 months after finishing treatment with imiquimod 5% in monotherapy (patient 7, see Table 1): (H) Mottled brown pigmentation of irregular distribution on his left paranasal region; (I) Dermoscopic photograph, showing asymmetrical perifollicular brown pigmentation.

Discussion

Imiquimod is not currently approved for treatment in LM, although it has been described as off label for incompletely excised lesions.^{2,3} Imiquimod is not a recommended monotherapy in LMM due to the risk of metastasis,³ but it is an option following excision of the infiltrative component. In our patients, imiquimod showed high efficacy in diverse treatment modalities and the recurrences observed were few (2/14 patients).

Our results are consistent with the reported data on the efficacy of imiquimod for LM. Two systematic reviews of imiquimod in monotherapy, described a clinical response rate of 78%.^{8,10} A systematic review of non-surgical treatments for LM, reported recurrence rates of 11.5% for radiotherapy, 24.5% for imiquimod, and 34.4% for laser therapy.⁴ One study with imiquimod alone or as an adjuvant treatment reported a clinical response rate of 72.7% and 94.4%, respectively.³

We think imiquimod could be useful in patients with LM who refuse a complete surgery because its unacceptable cosmetic results, or in those with comorbidities. We propose an excision of the dermoscopically visible lesion without margins; if this area is too large, we remove only the

darkest area. Finally, we prescribe imiquimod 5%. Otherwise, in patients who refuse any surgery, we use imiquimod as monotherapy. The regimen of imiquimod treatment varies from 2 to 84 weeks.^{5,8,10} Our initial outcome was achieving an intense inflammatory reaction, and then treatment was continued for several weeks, with a total duration of 6–8 weeks. Topical tazarotene 0,05% was added when the initial inflammatory reaction was insufficient. A fortnightly follow-up with removal of the scabs during the treatment improved imiquimod absorption, reassured the patient and improved treatment compliance.

Close dermoscopic follow-up is essential to promptly detect relapses. A brownish pigmentation is suggestive of recurrence if appears in the first two years of follow-up, although in longer term, it could indicate new solar lentigos in the area. In our patients, another dermoscopic finding that oriented relapse was the perifollicular distribution of the pigmentation. A bluish-gray background is indicative of transient postinflammatory hyperpigmentation, occurs within a few weeks after treatment and it correlates histologically with melanophagia.

Reflectance confocal microscopy (RCM) is a good alternative to histological studies for monitoring the lesion. We believe that close follow-up with clinical and digital dermoscopy photography may be a valid substitute to RCM, when it is not available.

Management of an LM recurrence with imiquimod is controversial. Our series included two cases of local recurrence re-treated conservatively with narrow excision and imiquimod, with good outcomes.

The main limitations of the study include the absence of a control group, the small number of patients and the heterogeneity of treatment modalities. This restricts generalizing of our results, although real clinical practice is like this. The strengths of our study reside in that patients were followed for long period (from 3 to 12 years) by the same dermatologist, and the existence of photographic controls every 6 months for monitoring. This allowed the rapid detection of relapses and documenting the early and transient post-inflammatory changes. Our data also contributes to scientific evidence on different treatment modalities in the absence of prospective randomized clinical trials. Also, it allows clinicians to consider diverse options when wide excisions cannot be performed.

Conflict of interests

The authors declare that they have no conflict of interest.

References

1. Donigan JM, Hyde MA, Goldgar DE, Hadley ML, Bowling M, Bowen GM. Rate of recurrence of lentigo maligna treated with off-label neoadjuvant topical imiquimod, 5%, cream prior to conservatively staged excision. *JAMA Dermatol.* 2018;15:885–9.
2. Tio DCKS, van Montfrans C, Ruijter CGH, Hoekzema R, Bekkenk MW. Effectiveness of 5% topical imiquimod for lentigo maligna treatment. *Acta Derm Venereol.* 2019;99:884–8.
3. Swetter SM, Chen FW, Kim DD, Egbert BM. Imiquimod 5% cream as primary or adjuvant therapy for melanoma in situ, lentigo maligna type. *J Am Acad Dermatol.* 2015;72:1047–53.

4. Read T, Noonan C, David M, Wagels M, Foote M, Schaidler H, et al. A systematic review of non-surgical treatments for lentigo maligna. *J Eur Acad Dermatol Venereol*. 2016;30:748–53.
5. Kirtschig G, Van Meurs T, Van Doorn R. Twelve-week treatment of lentigo maligna with imiquimod results in a high and sustained clearance rate. *Acta Derm Venereol*. 2015;95:83–5.
6. Kumar B, Narang T. Local and systemic adverse effects to topical imiquimod due to systemic immune stimulation. *Sex Transm Infect*. 2011;87:432.
7. Cotter MA, McKenna JK, Bowen GM. Treatment of lentigo maligna with imiquimod before staged excision. *Dermatol Surg*. 2008;34:147–51.
8. Mora AN, Karia PS, Nguyen BM. A quantitative systematic review of the efficacy of imiquimod monotherapy for lentigo maligna and an analysis of factors that affect tumor clearance. *J Am Acad Dermatol*. 2015;73:205–12.
9. Swetter SM, Tsao H, Bichakjian CK, Curiel-Lewandrowski C, Elder DE, Gershenwald JE, et al. Guidelines of care for the management of primary cutaneous melanoma. *J Am Acad Dermatol*. 2019;80:208–50.
10. Tio D, Van der Woude J, Prinsen CAC, Jansma EP, Hoekzema R, van Montfrans C. A systematic review on the role of imiquimod in lentigo maligna and lentigo maligna melanoma: need for standardization of treatment schedule and outcome measures. *J Eur Acad Dermatol Venereol*. 2017;31:616–24.