



ACADEMIA ESPAÑOLA
DE DERMATOLOGÍA
Y VENEREOLOGÍA

ACTAS Dermo-Sifiliográficas

Full English text available at
www.actasdermo.org



BRIEF COMMUNICATION

Cemiplimab in Advanced Cutaneous Squamous Cell Carcinoma: Real-World Experience in a Monographic Oncology Center



E. Ríos-Viñuela^{a,*}, P. Álvarez^b, J. Lavernia^b, C. Serra-Guillén^a, C. Requena^a,
E. Bernia^a, A. Diago^c, B. Llombart^a, O. Sanmartín^a

^a Department of Dermatology, Instituto Valenciano de Oncología, Valencia, Spain

^b Department of Oncology, Instituto Valenciano de Oncología, Valencia, Spain

^c Department of Dermatology, Hospital Universitario Miguel Servet, Zaragoza, Spain

KEYWORDS

Advanced cutaneous squamous cell carcinoma;
Metastatic squamous cell carcinoma;
Locally-advanced squamous cell carcinoma;
Cemiplimab;
PD-1 inhibitors

Abstract Management of advanced cSCC is challenging, and many available systemic medications have modest efficacy. Cemiplimab has demonstrated efficacy in the treatment of advanced cSCC in clinical trials, but real-world data are still limited. With the objective of evaluating the efficacy of cemiplimab in a real-world clinical setting, we conducted a prospective observational study of 13 patients with advanced cSCC. Six patients (46%) had locally advanced disease, while 7 (54%) had metastatic disease. A total of 8 patients (62%) responded to cemiplimab. Five (38%) showed a partial response, while 3 (23%) showed a complete response. Four patients with an initial partial response presented subsequent disease progression during follow-up. Six patients (46%) developed AEs, most of which were mild (G1). PFS was 5.9 months, with a median follow-up was 9 months. In conclusion, cemiplimab demonstrated its utility in the treatment of advanced cSCC, with acceptable response rates, a remarkable number of complete responses, and a very good safety profile.

© 2022 AEDV. Published by Elsevier España, S.L.U. This is an open access article under the CC BY-NC-ND license (<http://creativecommons.org/licenses/by-nc-nd/4.0/>).

PALABRAS CLAVE

Carcinoma de células escamosas cutáneo;
Cáncer escamoso metastásico;
Carcinoma de células escamosas localmente avanzado;
Cemiplimab;
Inhibidores PD-1

Cemiplimab en el carcinoma de células escamosas cutáneo avanzado: experiencia del mundo real en un centro oncológico monográfico

Resumen El manejo del carcinoma de células escamosas cutáneo (cSCC) avanzado es complicado, siendo modesta la eficacia de muchos de los fármacos sistémicos disponibles. Cemiplimab ha demostrado su eficacia en el tratamiento del cSCC avanzado en ensayos clínicos, pero los datos del mundo real siguen siendo limitados. Con el objetivo de evaluar la eficacia de cemiplimab en un entorno clínico del mundo real, realizamos un estudio observacional prospectivo de 13 pacientes con cSCC avanzado. Seis pacientes (46%) tenían enfermedad localmente avanzada, mientras que 7 (54%) tenían enfermedad metastásica. Un total de 8 pacientes (62%)

* Corresponding author.

E-mail address: elisariosvi@hotmail.com (E. Ríos-Viñuela).

respondieron a cemiplimab, 5 (38%) mostraron una respuesta parcial y 3 (23%) mostraron una respuesta completa. Cuatro pacientes con respuesta parcial inicial presentaron una progresión de la enfermedad subsiguiente durante el seguimiento. Seis pacientes (46%) desarrollaron efectos secundarios, siendo leve la mayoría de los mismos (G1). La supervivencia libre de progresión fue de 5,9 meses, con un seguimiento medio de 9 meses. En conclusión, cemiplimab demostró su utilidad en el tratamiento del cSCC avanzado, con unas tasas de respuesta aceptables, un número destacable de respuestas completas y un perfil de seguridad muy bueno.

© 2022 AEDV. Publicado por Elsevier España, S.L.U. Este es un artículo Open Access bajo la licencia CC BY-NC-ND (<http://creativecommons.org/licenses/by-nc-nd/4.0/>).

Introduction

Cutaneous squamous cell carcinoma (cSCC) is the second most common cutaneous neoplasm, and its incidence has increased in the last decades.^{1,2} Most cases of cSCC carry a good prognosis and can be treated with complete surgical excision.^{2,3} However, a small percentage of cases fall within the category of advanced cSCC, which is defined as a tumor that is surgically unresectable, that is not susceptible to curative radiation therapy, and/or that has developed nodal or visceral metastases.^{1,4} Management of patients with advanced cSCC is often challenging, and until recently the choice of systemic medications was limited and of modest efficacy.^{3–6} Of late, however, there is increasing evidence on the efficacy of immunotherapy in cSCC. Cemiplimab (an anti-PD1 monoclonal antibody) is the first immunotherapeutic agent approved for the treatment of metastatic or locally advanced cSCC, and it has demonstrated substantial antitumor activity with an acceptable safety profile in clinical trials.^{7–9} Evidence from real-world studies with cemiplimab is still scarce, and consists mainly on single case reports, with only two recent retrospective studies of patients treated with several PD-1 inhibitors (including cemiplimab).^{10,11} In the present study we report the clinical outcomes of 13 patients with advanced cSCC treated with cemiplimab. The main outcome measurement was treatment response. Secondary objectives were to evaluate treatment-related adverse events (AEs) and progression-free survival (PFS).

Methods

A prospective observational study was performed, including 13 patients treated with cemiplimab at Fundación Instituto Valenciano de Oncología between April 2019 and November 2020 (6 with locally advanced disease, 7 with nodal or visceral metastatic disease). Treatment was administered intravenously at the approved dose of 350 mg every 3 weeks. A partial response (PR) was defined as a reduction of $\geq 20\%$ of the clinical and/or radiological diameter, and a complete response (CR) as the complete clinical and radiological disappearance of the tumor. Progression was defined as an increase of the tumoral bulk of $\geq 10\%$. Stable disease did not meet criteria for either progression or complete or partial responses. Patients with disease progression received up to 6 cemiplimab cycles before treatment discontinuation. All patients were followed jointly both by the Oncology and

Dermatology departments, and underwent a thorough physical exam and clinical interview prior to each infusion, as well as control laboratory tests including a complete blood cell count and a basic biochemistry panel (electrolytes, liver and kidney function and lactate dehydrogenase levels). Control clinical pictures were carried out every 6–9 weeks by the Dermatology department. Control imaging studies were performed with variable periodicity: to confirm clinical treatment responses, to assess disease progression, and to verify response maintenance. PDL-1 expression was studied in histological samples of 11 cases. A descriptive statistical analysis was performed with the program IBM-SPSS 25.0. This study was approved by the institutional review board of Fundación Instituto Valenciano de Oncología, and informed consent was obtained from patients or their families following the procedures established by the ethics committee at our hospital.

Results

A total of 13 patients were included in this study. All but one patient were men, and most of them elderly (median age 81, range 56–91). The main clinical characteristics and treatment outcomes are depicted in Table 1. Patients received a median of 6 cycles of cemiplimab (range 1–23). Overall, 8 cases (62%) responded to cemiplimab after a median of 2 cycles (range 2–4). Three patients (23%) showed a complete response and 5 (38%) a PR. Responding patients received a median of 9 treatment cycles. All but one patient with an initial PR presented subsequent disease progression, leading to drug discontinuation. One of the patients with a CR (case 2) died of unrelated causes while still receiving cemiplimab. In case 8, cemiplimab was suspended after 11 cycles (5 cycles after achieving a complete radiological response), with no progression to date. Finally, the last patient with a CR (case 4) is still receiving cemiplimab (23 cycles to date): because of the high-risk location of the tumor, treatment discontinuation seemed too risky. PFS for responding patients was 5.9 months (range 1.9–15.5). Five patients showed no response to treatment (one of whom was lost to follow-up after receiving only one treatment cycle). The median follow-up was 9 months (range 3.5–16). Regarding treatment-related toxicity, 6 patients (46%) developed AEs. Most of them were mild (G1), and none of the patients in our series presented a serious or lethal adverse reaction. No patients discontinued treatment due to AEs. The most common side effects

Table 1 Main clinical characteristics and treatment outcomes.

	Age	Sex	Primary tumor location	Metastases	PDL-1 expression	Best response	Number of cycles	Immunorelated toxicity	Treatment discontinuation	Cause of discontinuation
Patient 1	83	M	Scalp	No	Weak positive (10%)	Progressive disease	3	Grade2 Rash	YES	Tumor progression
Patient 2	82	M	Left cheek	No	Weak positive (5%)	Partial response	14	Grade1 Asthenia	YES	Died from an ischemic stroke (patient with history of a myocardial infarction and a previous ischemic stroke)
Patient 3	73	M	Scalp	Regional lymph nodes	Weak positive (10%)	Partial response	10	No reported toxicity	YES	Tumor progression
Patient 4	80	M	Right forehead (orbital invasion, clinical perineural invasion)	Regional lymph nodes	Strong Positive (90%)	Complete response	23	Grade 1 asthenia and dizziness	NO	
Patient 5	81	M	Neck	Regional lymph nodes	Weak positive (5%)	Partial response	6	Grade 1 dizziness	YES	Tumor progression
Patient 6	86	M	Nose	No	Weak positive (5%)	Progressive disease	2	No reported toxicity	YES	Tumor progression
Patient 7	59	M	Left hand	Regional lymph nodes; pleural carcinomatosis.	Strong Positive (60%)	Progressive disease	4	No reported toxicity	YES	Tumor progression
Patient 8	77	M	Left cheek	No	Weak Positive (20%)	Complete response	11	Grade 1 Diarrhea	YES	Sustained complete response

Table 1 (Continued)

	Age	Sex	Primary tumor location	Metastases	PDL-1 expression	Best response	Number of cycles	Immunorelated toxicity	Treatment discontinuation	Cause of discontinuation
Patient 9	78	M	Scalp	No	Weak positive (5%)	Progressive disease	1	No reported toxicity	YES	Lost to follow-up during the COVID-19 pandemic, subsequent tumor progression
Patient 10	56	M	Left leg	Regional lymph nodes	Strong Positive (55%)	Partial response	8	Dermatologic toxicity (Grade 2 Psoriasis; Grade 1 bullous pemphigoid) Grade 1 Diarrhea	YES	Tumor progression
Patient 11	88	M	Lip	Regional lymph nodes	Not studied	Partial response	3	No reported toxicity	YES	Died from COVID-19 infection
Patient 12	91	F	Nose	No	Weak positive (1%)	Partial Response	6	No reported toxicity	NO	
Patient 13	88	M	Left ear	Regional lymph nodes	No studied	Progressive disease	6	No reported toxicity	YES	Tumor progression

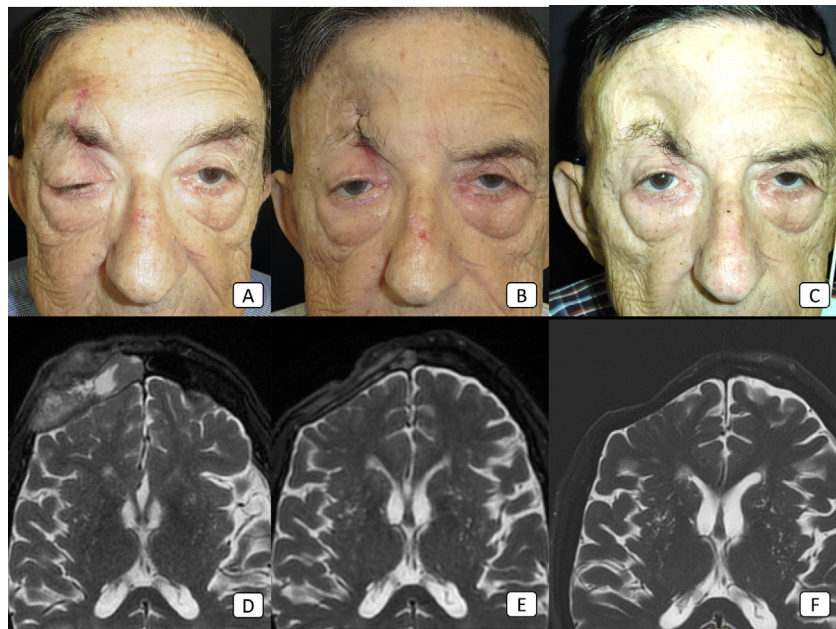


Figure 1 Case 8: advanced cSCC with orbital invasion, clinical perineural invasion, and regional nodal metastases. (A–C): clinical pictures of the patient before the start of therapy, after 2 cycles, and after 8 cycles, respectively. In (A), there is obvious ptosis of the right eyelid because of tumoral perineural invasion. (D–F): T2-weighted MRI images before the start of therapy, after 4 cycles, and after 18 cycles, respectively. The large, frontal mass seen in (D) has disappeared completely in (F), thus showing a complete treatment response.

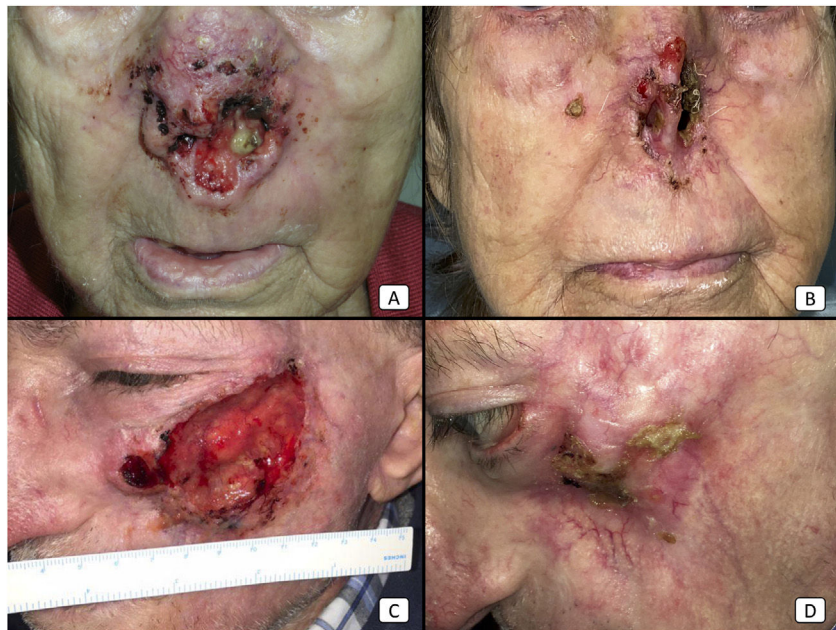

Figure 2 Cases 12 (A, B) and 2 (C, D). (A, B): Locally advanced cSCC in the nose of an elderly woman. There is a dramatical reduction of the tumor bulk after only 2 cycles of cemiplimab (B). (C, D): Locally advanced cSCC of the left cheek in an elderly man. Before starting therapy, the patient presented a large, ulcerated tumor (C). After 10 cycles, the patient showed a complete treatment response, with complete clearance of the tumoral mass and secondary maxillary bone exposure.

were fatigue, dizziness and diarrhea (Table 1). Finally, PD1-L expression was measured in 11 cases, with a median value of 10% (range 1–90%). PD1-L expression did not appear to be related to treatment response.

Discussion

Cemiplimab demonstrated substantial antitumor activity in the clinical trials that lead to its approval, with an

objective response rate of almost 50% in the treatment of locally advanced and metastatic cSCC.^{7–9} In our series, we observed a remarkably high rate of CR (23%), with a higher overall response rate (RR) as compared to clinical trials (62%). Data from the previous two other real-world studies differ: Hanna et al.¹⁰ found a lower overall RR as compared to clinical trials (31.5%), while Salzmann et al.¹¹ reported a higher RR (58.7%). Experience with pembrolizumab and nivolumab is more limited, but preliminary results show very similar RR than those of cemiplimab.^{10,11} It is still unclear why some patients show extraordinary responses to immunotherapy, and others do not respond at all. Focus has been placed in the role of PD-L1 expression and in the presence of TILs.¹¹ Surprisingly, the available data suggests that treatment response does not seem to be related to PD-L1 expression.⁵ Our series further supports these findings, with patients with complete responses showing very variable levels of PD-L1 expression. Optimal treatment duration is still unclear, and there is not enough evidence to determine how long therapy should be maintained after an objective response has been achieved.^{5,10,11} It seems, however, that patients responding to therapy induce a long-term response (especially those with complete responses), with few patients subsequently progressing.¹¹ In our series, this was not the case for patients with partial responses, as all but one of them presented subsequent disease progression in spite of continuing therapy. In patients with a complete response, the decision to continue treatment was made based on their risk profile. In case 5, the high-risk location of the tumor and the fear to a potentially fatal disease recurrence prevented treatment discontinuation. In case 8, because of the tumor's low-risk location (potentially susceptible to surgical treatment in case of recurrence) we decided to discontinue treatment, with no signs of disease progression during follow-up. In this series of primarily elderly patients, cemiplimab demonstrated a very good safety profile, without any serious treatment-related AEs and without any treatment discontinuation due to intolerable AEs (Fig. 1). The most common AEs were similar to those reported in previous studies. Nevertheless, all patients receiving cemiplimab should be monitored for potential side effects, as these could be severe or even lethal. In summary, cemiplimab showed evident antitumor activity, albeit response rates were lower than previously reported in clinical trials. In this case series, the number of complete responses, and the drug's good tolerability profile were significant. The main limitations of this study are the small number of patients included and the relatively short follow-up (Fig. 2).

Conclusions

Cemiplimab has proved to be effective in the treatment of advanced cSCC in real-world clinical practice. Although preliminary data have yielded lower response rates than previously reported in clinical trials, its significant

antitumor activity and its good tolerability place it as one of the first-line therapies for advanced cSCC. Further investigation is needed to define additional treatment approaches (such as adjuvant and neo-adjuvant immunotherapy) and to determine patient profiles that can predict the probability of treatment response.

Conflict of interests

The authors declare that they have no conflict of interest.

References

1. Cañueto J, Tejera-Vaquerizo A, Redondo P, Botella-Estrada R, Puig S, Sanmartín O. A review of terms used to define cutaneous squamous cell carcinoma with a poor prognosis. *Actas Dermosifiliogr*. 2020;111:281–90.
2. Alam M, Armstrong A, Baum C, Bordeaux JS, Brown M, Busam KJ, et al. Guidelines of care for the management of cutaneous squamous cell carcinoma. *J Am Acad Dermatol*. 2018;78:560–78. <http://dx.doi.org/10.1016/j.jaad.2017.10.007>.
3. Gellrich FF, Hüning S, Beissert S, Eigentler T, Stockfleth E, Gutzmer R, et al. Medical treatment of advanced cutaneous squamous-cell carcinoma. *J Eur Acad Dermatol Venereol*. 2019;33:38–43.
4. Keeping S, Xu Y, Chen C-I, Cope S, Mojebi A, Kuznik A, et al. Comparative efficacy of cemiplimab versus other systemic treatments for advanced cutaneous squamous cell carcinoma. *Future Oncol*. 2020.
5. Stratigos AJ, Garbe C, Dessinioti C, Lebbe C, Bataille V, Bastholt L, et al. European interdisciplinary guideline on invasive squamous cell carcinoma of the skin: Part 2. Treatment. *Eur J Cancer*. 2020;128:83–102.
6. Cowey CL, Robert NJ, Espirito JL, Davies K, Frytak J, Lowy I, et al. Clinical outcomes among unresectable, locally advanced, and metastatic cutaneous squamous cell carcinoma patients treated with systemic therapy. *Cancer Med*. 2020;9:7381–7.
7. Rischin D, Migden MR, Lim AM, Schmults CD, Khushalani NI, Hughes BGM, et al. Phase 2 study of cemiplimab in patients with metastatic cutaneous squamous cell carcinoma: primary analysis of fixed-dosing, long-term outcome of weight-based dosing. *J Immunother Cancer*. 2020;8.
8. Migden MR, Khushalani NI, Chang ALS, Lewis KD, Schmults CD, Hernandez-Aya L, et al. Cemiplimab in locally advanced cutaneous squamous cell carcinoma: results from an open-label, phase 2, single-arm trial. *Lancet Oncol*. 2020;21:294–305. [http://dx.doi.org/10.1016/S1470-2045\(19\)30728-4](http://dx.doi.org/10.1016/S1470-2045(19)30728-4).
9. Migden MR, Rischin D, Schmults CD, Guminski A, Hauschild A, Lewis KD, et al. PD-1 blockade with cemiplimab in advanced cutaneous squamous-cell carcinoma. *N Engl J Med*. 2018;341–51.
10. Hanna GJ, Ruiz ES, LeBoeuf NR, Thakuria M, Schmults CD, Decaprio JA, et al. Real-world outcomes treating patients with advanced cutaneous squamous cell carcinoma with immune checkpoint inhibitors (CPI). *Br J Cancer*. 2020;123:1535–42.
11. Salzmann M, Leiter U, Loquai C, Zimmer L, Ugurel S, Gutzmer R, et al. Programmed cell death protein 1 inhibitors in advanced cutaneous squamous cell carcinoma: real-world data of a retrospective, multicenter study. *Eur J Cancer*. 2020;138:125–32.