



# ACTAS Dermo-Sifiliográficas

Full English text available at  
[www.actasdermo.org](http://www.actasdermo.org)



## ORIGINAL ARTICLE

# [Translated article] Characteristics of Acral Lentiginous Melanoma According to Location in Stress- or Non–Stress-Bearing Areas: A Retrospective Study of 95 Patients<sup>☆</sup>



J. Arango Abisaad<sup>a,\*</sup>, V. Arciniegas Grisales<sup>a</sup>, Á. Londoño García<sup>a,b</sup>,  
E.M. Vasquez Trespacios<sup>c</sup>, G. Jiménez Calfat<sup>a,b</sup>, J.M. Cuello López<sup>b</sup>

<sup>a</sup> Servicio de Dermatología, Universidad CES, Medellín, Colombia

<sup>b</sup> Servicio de Oncología, Fundación Clínica Vida, Medellín, Colombia

<sup>c</sup> Epidemiología, Universidad CES, Medellín, Colombia

Received 12 April 2021; accepted 31 August 2021

### KEYWORDS

Acral lentiginous melanoma;  
Subungual;  
Mechanical stress;  
Risk factors

### Abstract

**Background and objective:** Acral lentiginous melanoma (ALM) arises in areas that are not generally exposed to UV radiation. Chronic trauma has been hypothesized to play a role in the development of this tumor. The aim of this study was to analyze the association between the presence and characteristics of ALM and location in stress- and non–stress-bearing areas.

**Material and methods:** Observational, descriptive analysis. For 95 patients with ALM evaluated at Fundación Clínica Vida in Medellín, Colombia between January 2016 and August 2020 we collected demographic, histologic and clinical variables and assigned the patients to 2 groups depending on whether their tumor was located in a stress-bearing area or not.

**Results:** Ninety-five patients (36 men and 59 women) with a median age of 59 years were studied. ALMs were more common in stress-bearing areas than in non–stress-bearing areas (58 [61%] vs. 17 [17.8%]). A history of direct trauma at the site of the tumor was reported in 18.9% of the cases ( $p = .025$ ) and was most common in patients with nail lesions. Invasive ALMs in stress-bearing areas had a greater Breslow thickness ( $p = .006$ ) and higher ulceration rates than those in non–stress-bearing areas ( $p = .018$ ).

**Conclusions:** ALM on both the feet and hands is more common in stress-bearing areas. Our findings support the hypothesis that mechanical stress may have a pathogenic role in ALM.

© 2022 Published by Elsevier España, S.L.U. on behalf of AEDV. This is an open access article under the CC BY-NC-ND license (<http://creativecommons.org/licenses/by-nc-nd/4.0/>).

DOI of original article: <https://doi.org/10.1016/j.ad.2021.08.006>

<sup>☆</sup> Please cite this article as: Arango Abisaad J, Arciniegas Grisales V, Londoño García Á, Vasquez Trespacios EM, Jiménez Calfat G, Cuello López JM. Características del melanoma lentiginoso acral según su relación con la presión. Estudio retrospectivo de 95 pacientes. Actas Dermosifiliogr. 2022;113:134–140.

\* Corresponding author.

E-mail address: [juanitaarangoabisaad@gmail.com](mailto:juanitaarangoabisaad@gmail.com) (J. Arango Abisaad).

<https://doi.org/10.1016/j.ad.2021.08.012>

0001-7310/© 2022 Published by Elsevier España, S.L.U. on behalf of AEDV. This is an open access article under the CC BY-NC-ND license (<http://creativecommons.org/licenses/by-nc-nd/4.0/>).

**PALABRAS CLAVE**

Melanoma lentiginoso acral;  
Subungular;  
Estrés mecánico;  
Factores de riesgo

## Características del melanoma lentiginoso acral según su relación con la presión. Estudio retrospectivo de 95 pacientes

**Resumen**

**Antecedentes y objetivo:** El melanoma lentiginoso acral (MLA) se presenta en zonas con poca exposición a la radiación ultravioleta. Se ha planteado que el trauma crónico puede predisponer a su desarrollo. El objetivo del presente estudio fue relacionar la presencia del MLA y sus características con las zonas acrales que se consideran de presión y de no presión.

**Material y métodos:** Se realizó un estudio observacional, descriptivo, con intención analítica. Se recogieron los datos de 95 pacientes con diagnóstico de MLA evaluados en la Fundación Clínica Vida en Medellín, Colombia, entre enero de 2016 y agosto de 2020. Se recolectaron variables demográficas, histológicas y clínicas del tumor, las cuales se analizaron en dos grupos, según si estaba sometida a fuerzas de presión o no.

**Resultados:** Se incluyeron 95 pacientes con MLA (36 hombres y 59 mujeres), con una mediana de edad de 59 años. Se presentaron más melanomas en las zonas de presión que de no presión (58 [61%] vs. 17 [17,8%]). Se refirió la existencia de un trauma directo previo en 18,9% de los casos, el cual fue más frecuente en las lesiones de las uñas ( $p = 0,025$ ). Los melanomas invasores tuvieron un mayor Breslow ( $p = 0,006$ ) y presencia de ulceración ( $p = 0,018$ ) en las zonas de presión y en las uñas que en las zonas de no presión.

**Conclusiones:** El MLA es más frecuente en zonas de presión que de no presión, tanto en la mano como en el pie. Esto apoya la hipótesis de que el estrés mecánico puede jugar un papel en la patogénesis de este tipo de tumor.

© 2022 Publicado por Elsevier España, S.L.U. en nombre de AEDV. Este es un artículo Open Access bajo la licencia CC BY-NC-ND (<http://creativecommons.org/licenses/by-nc-nd/4.0/>).

## Introduction

Acral lentiginous melanoma (ALM) is a subtype of melanoma that occurs on the palms, soles, and nail bed. While the incidence is the same in all populations, its proportion of the total of all melanomas ranges between 1% and 7% in the Caucasian phenotype,<sup>1</sup> up to 15% in the Hispanic phenotype,<sup>2</sup> between 45% and 58% in the Asian phenotype, and 70% in the black phenotype.<sup>3,4</sup>

The behavior of this tumor is different than that of melanomas in other locations. Specific risk factors have been reported, as ALM is less associated with light phototypes or pre-existing melanocytic nevus and tends to present in areas with little exposure to ultraviolet radiation (UVR).<sup>5-7</sup>

It has been suggested that chronic trauma in acral areas may predispose the patient to presenting this type of tumor.<sup>5</sup> This is because it presents more frequently in areas of greater mechanical stress, the front and rear areas of the foot, suggesting that it is because the pressure leads to greater damage to the skin and, in turn, a higher propensity to develop ALM, in comparison with other areas considered non-stress-bearing areas.<sup>5,6</sup> Although fewer studies of ALM are available, findings have also been observed that support this hypothesis, such as the fact that melanomas, unlike nevus, are not located on the proximal area of the palm but on the pads and on the distal part of the palm, which tends to present greater mechanical stress.<sup>8</sup>

The objective of this study was to link ALM and its characteristics with the acral areas that are considered stress-bearing and non-stress-bearing areas.

## Material and Methods

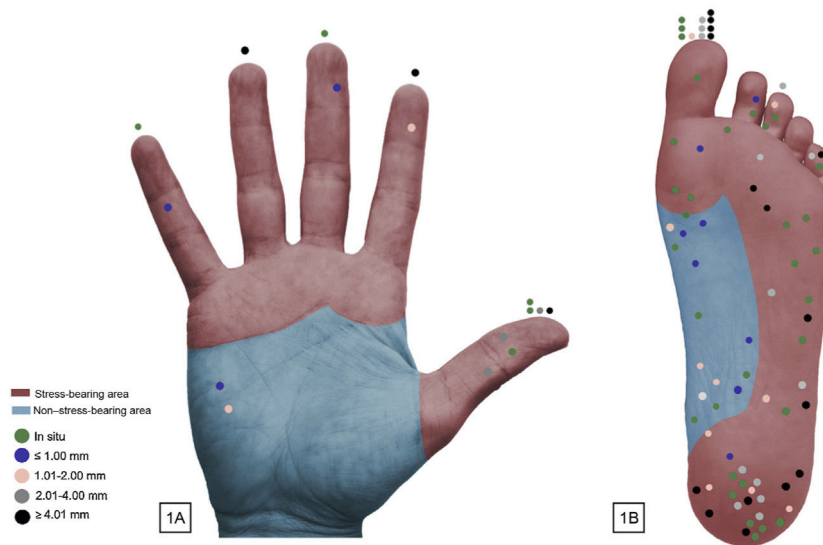
We performed a retrospective observational study following the recommendations of the Strobe guidelines.<sup>9</sup> Data were collected from patients with a diagnosis of ALM who had been evaluated in the Fundación Clínica Vida in Medellín, Colombia, the city's referral center for skin-cancer treatment, between January 2016 and August 2020.

The data were obtained from a mixed source of information through electronic patient records and a telephone questionnaire was administered to complete the missing information. The location of the lesion was specified by means of an image sent to the patient, showing the affected extremity divided into areas so that the patient could indicate the affected area, thus allowing for an objective classification.

Inclusion criteria were patients with a diagnosis of ALM confirmed by histopathology, with no distant metastasis (those patients were excluded, as the event presented in 4 cases, for whom complete histologic staging information of the primary melanoma was not available). Patients who had died at the time of the study were excluded, as were those whom it was not possible to contact to administer the telephone survey.

The study and all its procedures were approved by the ethics committee of Fundación Clínica Vida.

Demographic data such as age and sex were collected. Subjects were asked whether they had a history of direct trauma to the areas of the tumor and about lateral dominance (right-handedness or left-handedness). Furthermore, when the telephone survey was administered, the weight and height of the patient was recorded to calcu-



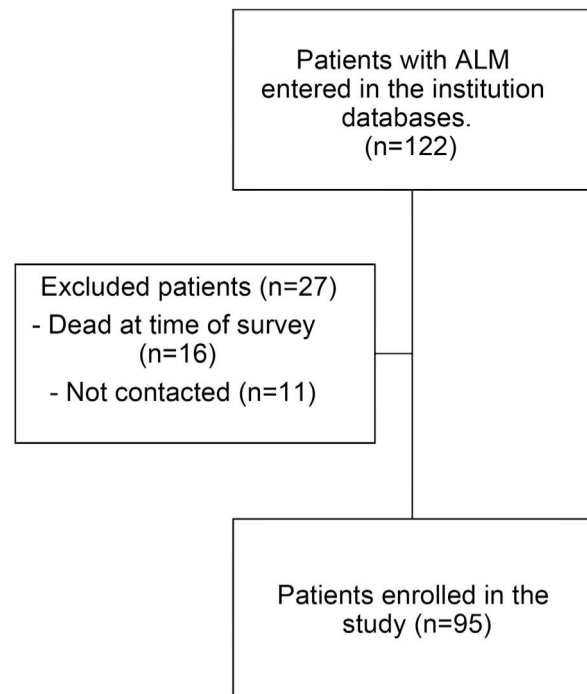
**Figure 1** Distribution of the 95 cases of acral lentiginous melanoma. In the cases of subungual lesions, the mark is on the affected digit.

late the body mass index (BMI), which was categorized according to the overweight and obese classification proposed by the World Health Organization (WHO) expert committee.<sup>10</sup>

The dependent variable was location, according to whether or not it was subject to stress forces (Fig. 1). On the volar surface of the hand, stress-bearing areas were considered to be the pressure areas of the fingers and the head of the metacarpals, as those are the areas subject to the most mechanical stress with grip and where most lesions, such as calluses and blisters tend to present.<sup>8,11,12</sup> By expert consensus, the rest of the palm was classified as a non-stress-bearing area. The nails were analyzed separately. On the plantar surface, depending on the degree of mechanical stress, the plantar surface of the toes, the forefoot, lateral midfoot, and the heel were classified as stress-bearing areas. The plantar arch was defined as a non-stress-bearing area. The nails were analyzed separately.

The following independent variables were taken into consideration. With regard to tumor characteristics, we evaluated location, laterality (right, left), histopathology data including tumor depth (Breslow: recorded as an ordinal qualitative variable with thickness intervals of T0-T4), and ulceration. We also evaluated metastatic lymph-node involvement and the tumor was classified according to the staging system proposed by the American Joint Committee on Cancer (AJCC), eighth edition.<sup>13</sup>

Categorical variables were reported using absolute and relative frequency distribution and quantitative variables were reported using measures of central tendency and dispersion. The association between independent qualitative variables and the dependent variable was evaluated using the  $\chi^2$  test or Fisher's exact test when the expected frequency was less than 5%. Statistical analysis was performed using the SPSS version 21 statistical package (IBM Corp., Armonk, NY, USA). Statistical significance was established for  $P < .05$ .



**Figure 2** Flow diagram of the patients enrolled in the study.

## Results

Ninety-five patients with ALM were enrolled (Fig. 2), with median age (interquartile range [IQR]) of 59 years (50-70 years); of these patients, 59 (62.1%) were female. Prior direct trauma to the area where the melanoma presented was reported in 18 cases (18.9%) (Table 1).

Of the lesions evaluated, 16 (16.8%) presented on the hands and 79 (83.1%) on the feet. Although a slight predominance of the right side was observed for tumors on the hand (56.2% right vs. 43.7% left), on the feet, more acral

**Table 1** Characteristics of Study Patients.

Variable	n (%)
<b>Sex</b>	
Male	36 (37.8%)
Female	59 (62.1%)
<b>Age, y</b>	59.2 ± 15.2
<b>History of trauma</b>	
Yes	18 (18.9%)
No	77 (81%)
<b>Lateral dominance</b>	
Right	86 (90.5%)
Left	9 (9.4%)
<b>BMI</b>	
Low weight	1 (1%)
Normal weight	37 (39%)
Overweight	33 (34.7%)
Obese	15 (15.7%)
No information	9 (9.4%)

Abbreviations: BMI indicates body mass index.

**Table 2** Clinical Characteristics ALM Analyzed.

Characteristics of the melanoma	Hand (n = 16)	Foot (n = 79)
	n (%)	n (%)
<b>Breslow thickness</b>		
<i>In situ</i>	5 (31.2%)	32 (40%)
T1: ≤ 1.0 mm	3 (18.7%)	8 (10.1%)
T2: > 1.0-2.0 mm	2 (12.5%)	10 (12.6%)
T3: > 2.0-4.0 mm	3 (18.7%)	14 (17.7%)
T4: > 4.0 mm	3 (18.7%)	15 (18.9%)
Ulceration*	(n = 11)	(n = 47)
Yes	7 (63.6%)	19 (40.4%)
No	4 (36.3%)	28 (59.5%)
Lymph-node metastasis*	2 (18%)	13 (27.6%)
<b>AJCC staging</b>		
0	5 (31.2%)	32 (40%)
I	4 (25%)	13 (16.4%)
II	5 (31.2%)	21 (26.5%)
III	2 (12.5%)	13 (16.4%)
<b>Tumor laterality</b>		
Right	9 (56.2%)	37 (46.8%)
Left	7 (43.7%)	42 (53.1%)

Abbreviations: AJCC indicates American Joint Committee on Cancer.

\* Only patients with invasive melanoma were included (n = 58).

were observed on the left side (53.1% left vs. 46.8% right). Most of the lesions were *in situ* (37 [38.9%]) (Table 2).

Of the 16 melanomas on the hand, half were located on the nails, 6 (37.5%) in the stress-bearing area, and 2 (12.5%) in the non-stress-bearing area (Fig. 1A). Of the 79 melanomas on the foot, the stress-bearing area was the most affected, with 52 cases (65.8%), in which the heel was the location with the greatest number of melanomas. A total of

15 of the lesions (18.9%) presented in the non-stress-bearing area and 12 (15.1%) on the nails (Fig. 1B).

A history of direct trauma to the area where the melanoma presented was more frequent in patients with lesions on the nails. The invasive melanomas had a higher Breslow thickness and a higher presence of ulceration in the stress-bearing areas and on the nails than in the non-stress-bearing areas ( $P = .006$  and  $P = .018$ , respectively). The distribution pattern of the melanoma was not associated with the other variables evaluated (Table 3).

## Discussion

ALM differs from melanomas in other locations by its presentation and associated risk factors.<sup>5,14</sup> In our study, we analyzed the clinical and pathologic characteristics of ALM in 95 patients, taking into account the location of the tumors. Our analysis shows that, both on the hand and the foot, ALM is more frequent in areas subject to greater stress, which are also associated with greater tumor depth in comparison with non-stress-bearing areas. A history of direct trauma to the area where the melanoma presented was more frequent in patients with lesions on the nails, which was also the area with more frequent ulceration.

The mean age of the patients in the study was lower than that described in some Asian<sup>6,15,16</sup> and Latin American countries.<sup>17,18</sup> The ratio of male to female was 1:1.6, which is comparable to data from other authors,<sup>1,18,19</sup> and unlike the study by Duarte<sup>20</sup> in Colombia, more cases of ALM were recorded in men than in women.

The etiology of ALM continues to be unclear. Because of its location, the acral surface of the body suffers the least damage from sunlight. Indeed, one study has shown that acral melanomas have different genetic characteristics, with a lower frequency of alternations induced by UV light.<sup>21</sup>

It is also important to note that the palms and soles are more hypopigmented areas compared to other areas of the body, including in darker phenotypes. This may play a role in the cause of melanomas on volar skin because, as mentioned by Saida,<sup>22</sup> melanin is known to act by blocking the production of free radicals.

It has also been suggested that the acral areas are subject to greater mechanical stress, especially in the front and rear of the foot, which may lead to greater damage to the skin in these areas, thus favoring the development of melanoma.<sup>5,6</sup> Indeed, the literature reports that most acral melanomas are located on the sole of the foot,<sup>1,23,24</sup> which may be explained by the greater mechanical stress that occurs in this region, in comparison with the palm of the hand.<sup>8</sup> In line with these data, most of the tumors in our series were located on the feet. Nevertheless, some studies have reported that subungular melanomas present with greater frequency on the fingers than on the toes,<sup>1,25</sup> unlike in our study, where subungular melanomas were also more frequent on the foot, principally the big toe. The thumb nail was also the most frequently affected on the hand (data not shown in tables), which is in line with the information reported to date.<sup>15,26</sup> Möhrle and Häfner<sup>27</sup> suggest that acute or chronic trauma may be associated with the pathogenesis of acral melanoma, as the thumb and big toe are the digits

**Table 3** Association Between Tumor Characteristics and Location.

Parameter	Stress-bearing area (n = 58, 61%)	Non-stress-bearing area (n = 17, 17.8%)	Nail (n = 20, 21%)	Total (n = 95, 100%)	P
<b>Sex</b>					.728
Female	35 (60.3%)	12 (70.6%)	12 (60%)	59 (62.1%)	
Male	23 (39.7%)	5 (29.4%)	8 (40%)	36 (37.9%)	
<b>BMI</b>					.345
Low	0	1 (5.9%)	0	1 (1%)	
Normal	20 (34.4%)	9 (52.9%)	8 (40%)	37 (38.9%)	
Overweight	24 (41.4%)	4 (23.5%)	5 (25%)	33 (34.7%)	
Obese	9 (15.5%)	2 (11.8%)	4 (20%)	15 (15.8%)	
No information	5 (8.6%)	1 (5.9%)	3 (15%)	9 (9.5%)	
<b>History of trauma</b>					.025
Yes	8 (13.8%)	2 (11.8%)	8 (40%)	18 (18.9%)	
No	50 (86.2%)	15 (88.2%)	12 (60%)	77 (81.1%)	
<b>Breslow thickness</b>					.006
<i>In situ</i>	24 (41.4%)	6 (35.3%)	7 (35%)	37 (38.9%)	
≤ 1 mm	5 (8.6%)	6 (35.3%)	0	11 (11.6%)	
> 1.0-2.0 mm	7 (12.1%)	4 (23.5%)	1 (5%)	12 (12.6%)	
> 2.0-4.0 mm	11 (19%)	1 (5.9%)	5 (25%)	17 (17.9%)	
> 4.0 mm	11 (19%)	0	7 (35%)	18 (18.9%)	
<b>Ulceration*</b>					.018
Yes	12 (35.3%)	3 (27.3%)	10 (76.9%)	25 (43.1%)	
No	22 (64.7%)	8 (72.7%)	3 (23.1%)	33 (56.9%)	
<b>Lymph-node metastasis*</b>					.470
Yes	8 (23.5%)	2 (18.2%)	5 (38.5%)	15 (25.9%)	
No	26 (76.5%)	9 (81.8%)	8 (61.5%)	43 (74.1%)	
<b>Stage</b>					.128
0	24 (41.4%)	6 (35.3%)	7 (35%)	37 (38.9%)	
I	11 (19%)	6 (35.3%)	0	17 (17.9%)	
II	15 (25.9%)	3 (17.6%)	8 (40%)	26 (27.4%)	
III	8 (13.8%)	2 (11.8%)	5 (25%)	15 (15.8%)	

Abbreviations: BMI indicates body mass index.

\* Only patients with invasive melanoma were included (n = 58).

most commonly affected by trauma and are those that most frequently present melanoma.

In our patients, the percentage with a history of prior direct trauma at the site of the tumor was greater than that published in other studies.<sup>15,25</sup> Similar to that reported by Holman,<sup>28</sup> we found that a history of trauma was more frequent in lesions of the nails than lesion in other acral areas.

We found that ALM presented more frequently in stress-bearing areas of the feet, mainly on the heel, which is in line with the information published in different populations.<sup>6,16,29</sup> In a study performed at the Mayo Clinic, no significant differences were found between the distribution of the acral lesions, by stress-bearing and non-stress-bearing area. However, the study found that approximately half of patients with melanomas on the arch of the foot were obese, which may be associated with flattening of the plantar arch. The authors therefore excluded these cases from the analysis and found a reduction in the P value (P = .39 vs. P = .11), although without reaching statistical significance.<sup>30</sup> Our study found no association between BMI and tumor location, unlike Costello et al,<sup>30</sup> who assume that obese patients

(BMI > 30) present flattening and subsequent loss of the plantar arch. Our study did not determine this outcome and it was not therefore possible to reach this conclusion.

Nishiguchi et al<sup>8</sup> evaluated the difference in distribution between nevus and melanoma of the palm and fingers and found that nevus presents on the area proximal to the distal transversal fold of the palm, whereas melanoma presents on the pads and distal to the transversal distal arch of the palm—areas associated with greater mechanical stress. In our study, melanoma of the hand also presented predominantly on the volar surface of the fingers and on the nails. Only 2 cases were found on the hypothenar eminence. These findings support the fact that it is useful to use location to guide a suspected diagnosis of malignancy when the lesion presents in the more distal areas, especially on the digits and nails. Nevertheless, the fact that the lesion presents in a non-stress-bearing or more proximal area cannot rule out a diagnosis of melanoma, as shown in our study.

Given that the behavior of melanomas on the nails has been reported to be different in some respects in comparison to other acral melanomas,<sup>25,28</sup> in our study, we analyzed subungual melanomas separately and found that invasive

melanomas tended to present greater tumor depth, greater presence of ulceration, and a higher percentage of metastasis in the lymph nodes compared to other acral locations. This was in contrast to the study by Moon et al,<sup>31</sup> who found that the nails presented less ulceration than lesions on the digits, palms, and soles.

In terms of the histopathologic characteristics of the tumor, in our series, most of the lesions, on both hands and feet, were in situ, unlike the studies by Barrera Jácome et al<sup>18</sup> and Costello et al,<sup>30</sup> in which cases of noninvasive acral melanoma correspond to low rates of 8.3%. Among invasive melanoma, we found that the highest percentage presented a Breslow thickness of greater than 4 mm, comparable with that reported in populations such as Korea<sup>25</sup> but higher than that found in the US<sup>23,30</sup> and Taiwan.<sup>6</sup>

Unlike studies published by other authors, who found no link between tumor location and Breslow thickness or the presence of ulceration,<sup>6,25,30</sup> our study did find a significant difference between the presence of ulceration, Breslow thickness, and a history of trauma when comparing melanomas located in stress-bearing areas, non-stress-bearing areas, and the nails. It is interesting to see how the percentage among invasive melanomas increased as the Breslow thickness increased in lesions located in stress-bearing areas, unlike non-stress-bearing areas, where the percentage of lesions decreased as depth increased. No association was found, however, between location of ALM and sex, BMI, metastasis in lymph nodes, or tumor stage.

The limitations of our study include the fact that some data were obtained from secondary sources. The BMI variable was calculated based on the weight of the patient at the time of the telephone survey, as the clinical records did not contain weight and height at the time of diagnosis; patients may, therefore, have had different body weight at the time the melanoma was diagnosed. Moreover, the number of lesions on the hand was low and it was difficult to classify the palm into stress-bearing and non-stress-bearing areas, as this may be affected by the activity carried out by the patient, which makes it hard to derive conclusions regarding the melanomas located in this area. As the cases were recent, it was not possible to evaluate survival at 5 years in these patients, data that would make an interesting comparison with other populations.

The findings of our study show that the acral areas considered stress-bearing areas and those with greater predisposition to direct trauma, such as the nail of the big toe and the thumb are associated with ALM, which also suggests that both acute and chronic stress may be associated with developing this subtype of melanoma. Although in our study, location of the lesion was associated significantly with the Breslow thickness, no link was found with tumor stage, which may indicate that location does not affect outcome in these patients. Nevertheless, studies are required that include a greater number of cases, especially on the hand, to analyze the differences between location and survival in these patients. It is also important to investigate the work performed by the patients, which may involve greater mechanical stress in the acral areas, in order to link those activities with ALM.

In conclusion, the predominant location of ALM in stress-bearing areas, consistent with the findings of other studies,

supports the hypothesis that mechanical stress may play a role in the pathogenesis of this type of tumor.

## Funding

This study has not received funding of any kind.

## Conflicts of Interest

The authors declare that they have no conflicts of interest.

## Acknowledgments

The authors would like to thank Dr. Sergio Lozano Gómez and María Adelaida Piedrahita.

## References

- Phan A, Touzet S, Dalle S, Ronger-Savle S, Balme B, Thomas L. Acral lentiginous melanoma: a clinicoprognostic study of 126 cases. *Br J Dermatol*. 2006;155:561–9, <http://dx.doi.org/10.1111/j.1365-2133.2006.07368.x>.
- Duarte C, Lopez H. Melanoma acral lentiginoso: revisión bibliográfica. *Rev Colomb Cir [Internet]*. 2014;29:155–66 [accessed 14 Oct 2020]. Available from: <https://www.revistacirugia.org/index.php/cirugia/article/view/412>.
- Bologna JL, Schaffer JV, Cerroni L. *Dermatology*. Elsevier; 2018.
- Chang JWC, Yeh KY, Wang CH, Yang TS, Chiang HF, Wei FC, et al. Malignant melanoma in Taiwan: a prognostic study of 181 cases. *Melanoma Res*. 2004;14:537–41, <http://dx.doi.org/10.1097/00008390-200412000-00016>.
- Goydos JS, Shoen SL. Acral Lentiginous Melanoma. In: Kaufman HL, Mehnert JM, editors. *Melanoma. Cancer Treatment and Research*, 167. Springer International Publishing; 2016. p. 321–9, [http://dx.doi.org/10.1007/978-3-319-22539-5\\_14](http://dx.doi.org/10.1007/978-3-319-22539-5_14).
- Sheen YS, Liao YH, Lin MH, Chen JS, Liao JY, Tseng YJ, et al. A clinicopathological analysis of 153 acral melanomas and the relevance of mechanical stress. *Sci Rep*. 2017;7, <http://dx.doi.org/10.1038/s41598-017-05809-9>.
- Nagore E, Pereda C, Botella-Estrada R, Requena C, Guillén C. Acral lentiginous melanoma presents distinct clinical profile with high cancer susceptibility. *Cancer Causes Control*. 2009;20:115–9, <http://dx.doi.org/10.1007/s10552-008-9221-y>.
- Nishiguchi M, Yamamoto Y, Hara T, Okuhira H, Inaba Y, Kunitomo K, et al. Difference in distribution of malignant melanoma and melanocytic nevus in the palm and finger. *Biosci Trends*. 2019;13:361–3, <http://dx.doi.org/10.5582/bst.2019.01221>.
- STROBE Statement—Checklist of items that should be included in reports of cross-sectional studies; 2007 [accessed 29 Oct 2020]. Available from: [https://www.strobe-statement.org/fileadmin/Strobe/uploads/checklists/STROBE\\_checklist\\_v4\\_cross-sectional.pdf](https://www.strobe-statement.org/fileadmin/Strobe/uploads/checklists/STROBE_checklist_v4_cross-sectional.pdf).
- Obesity: Preventing and Managing the Global Epidemic: Report of a WHO Consultation. *World Health Organ Tech Rep Ser*. 2000;894:1–253.
- Stellman JM. *Enciclopedia de Salud y Seguridad en el Trabajo*. Ministerio de Trabajo y Asuntos Sociales; 1998 [accessed 5 Abr 2021]. Available from: <https://www.insst.es/tomo-i>.
- McNamara AR, Ensell S, Farley TD. Hand Blisters in Major League Baseball Pitchers: Current Concepts and Management. *Am J Orthop Belle Mead NJ*. 2016;45:134–6.
- Keung EZ, Gershenwald JE. The eighth edition American Joint Committee on Cancer (AJCC) melanoma

- staging system: implications for melanoma treatment and care. *Expert Rev Anticancer Ther.* 2018;18:775–84, <http://dx.doi.org/10.1080/14737140.2018.1489246>.
14. Bristow I, Bower C. Melanoma of the Foot. *Clin Podiatr Med Surg.* 2016;33:409–22, <http://dx.doi.org/10.1016/j.cpm.2016.02.008>.
  15. Lv J, Dai B, Kong Y, Shen X, Kong J. Acral Melanoma in Chinese: A Clinicopathological and Prognostic Study of 142 cases. *Sci Rep.* 2016;6:31432, <http://dx.doi.org/10.1038/srep31432>.
  16. Minagawa A, Omodaka T, Okuyama R. Melanomas and Mechanical Stress Points on the Plantar Surface of the Foot. *N Engl J Med.* 2016;374:2404–6, <http://dx.doi.org/10.1056/NEJMc1512354>.
  17. Nunes LF, Quintella Mendes GL, Koifman RJ. Acral melanoma: a retrospective cohort from the Brazilian National Cancer Institute (INCA). *Melanoma Res.* 2018;28:458–64, <http://dx.doi.org/10.1097/CMR.0000000000000476>.
  18. Barrera Jácome A, Herrera González NE, Fernández Ramírez F, Mercadillo Pérez P. Características clínicas e histopatológicas del melanoma nodular y acral lentiginoso en pacientes mexicanos. *Dermatología Cosmet Médica Quir.* 2019;17:166–71.
  19. Bello DM, Chou JF, Panageas KS, Brady MS, Coit DG, Carvajal RD, et al. Prognosis of Acral Melanoma: A Series of 281 Patients. *Ann Surg Oncol.* 2013;20:3618–25, <http://dx.doi.org/10.1245/s10434-013-3089-0>.
  20. Duarte CA, Flórez JP, López HG, Meneses MX, de Vries E. Survival of acral lentiginous melanoma in the National Cancer Institute of Colombia. *J Eur Acad Dermatol Venereol.* 2017;31:438–42, <http://dx.doi.org/10.1111/jdv.13913>.
  21. Liu L, Zhang W, Gao T, Li C. Is UV an etiological factor of acral melanoma? *J Expo Sci Environ Epidemiol.* 2016;26:539–45, <http://dx.doi.org/10.1038/jes.2015.60>.
  22. Saida T. Morphological and molecular uniqueness of acral melanoma. *Expert Rev Dermatol.* 2007;2:125–31, <http://dx.doi.org/10.1586/17469872.2.2.125>.
  23. Bradford PT, Goldstein AM, McMaster ML, Tucker MA. Acral Lentiginous Melanoma: Incidence and Survival Patterns in the United States, 1986–2005. *Arch Dermatol.* 2009;145(4):427–34, <http://dx.doi.org/10.1001/archdermatol.2008.609>.
  24. Huang K, Fan J, Misra S. Acral Lentiginous Melanoma: Incidence and Survival in the United States, 2006–2015, an Analysis of the SEER Registry. *J Surg Res.* 2020;251:329–39, <http://dx.doi.org/10.1016/j.jss.2020.02.010>.
  25. Jung HJ, Kweon SS, Lee JB, Lee SC, Yun SJ. A Clinicopathologic Analysis of 177 Acral Melanomas in Koreans: Relevance of Spreading Pattern and Physical Stress. *JAMA Dermatol.* 2013;149:1281, <http://dx.doi.org/10.1001/jamadermatol.2013.5853>.
  26. Talavera-Belmonte A, Bonfill-Ortí M, Martínez-Molina L, Fornons-Servent R, Bauer-Alonso A, Ferreres-Riera JR, et al. Melanoma subungueal: estudio descriptivo de 34 pacientes. *Actas Dermosifiliogr.* 2018;109:801–6, <http://dx.doi.org/10.1016/j.ad.2018.06.010>.
  27. Möhrle M, Häfner HM. Is Subungual Melanoma Related to Trauma? *Dermatology.* 2002;204:259–61, <http://dx.doi.org/10.1159/000063354>.
  28. Holman BN, Van Gulick RJ, Amato CM, MacBeth ML, Davies KD, Aisner DL, et al. Clinical and molecular features of subungual melanomas are site-specific and distinct from acral melanomas. *Melanoma Res.* 2020;30:562–73, <http://dx.doi.org/10.1097/CMR.0000000000000688>.
  29. Dwyer PK, Mackie RM, Watt DC, Aitchison TC. Plantar malignant melanoma in a white Caucasian population. *Br J Dermatol.* 1993;128:115–20, <http://dx.doi.org/10.1111/j.1365-2133.1993.tb15138.x>.
  30. Costello CM, Pittelkow MR, Mangold AR. Acral Melanoma and Mechanical Stress on the Plantar Surface of the Foot. *N Engl J Med.* 2017;377:395–6, <http://dx.doi.org/10.1056/NEJMc1706162>.
  31. Moon HR, Kang HJ, Won CH, Chang SE, Lee MW, Choi JH, et al. Heterogeneous spectrum of acral melanoma: A clinicoprognostic study of 213 acral melanomas according to tumor site. *J Am Acad Dermatol.* 2018;78:179–82.e3, <http://dx.doi.org/10.1016/j.jaad.2017.07.029>.