

## CASE AND RESEARCH LETTER

### Sporadic Keratoacanthomas in Young Patients: A Case Series and a Proposed Diagnostic Algorithm



### Queratoacantomas esporádicos en pacientes jóvenes: serie de casos y propuesta de algoritmo diagnóstico

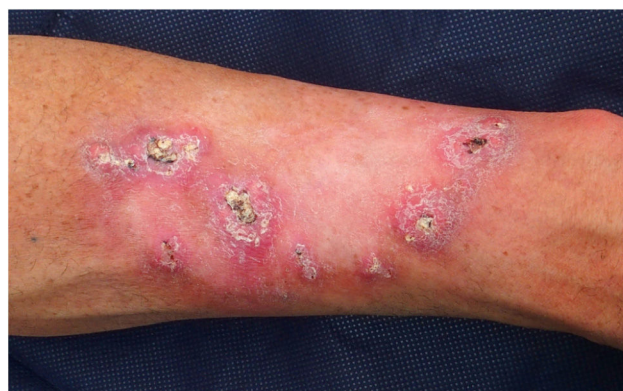Dear Editor,

Keratoacanthomas (KAs) are usually sporadic and solitary lesions appearing in patients on sun-exposed areas. Chronic sun-exposure, imiquimod, BRAF inhibitors and hedgehog pathway inhibitors can be triggering agents. Genetic causes of KAs such as Ferguson-Smith syndrome (multiple self-healing squamous epitheliomas -MSSE) and generalized eruptive keratoacanthoma (Grzybowski syndrome) are characterized by the development of dozens to hundreds of KAs at a young age and are not associated with other cutaneous or extracutaneous tumours<sup>1</sup>. Other associated genetic diseases are xeroderma pigmentosum (XP) and Muir-Torre syndrome (MTS).

We sought to describe the clinical-epidemiological characteristics and associated genetic disorders of young patients with KAs in our centers, and to develop a diagnostic algorithm. We describe three patients who developed KAs before age 40 and who harbored unrecognized genetic diseases predisposing to these cutaneous lesions.

Patient 1 was a 54-year-old male with no relevant family history and a personal history of intense sunlight exposure who had had more than ten KAs since age 39. He developed growing centrifugal lesions on the left forearm after radiotherapy for a solitary KA. The lesions were clinically and histologically suggestive of keratoacanthoma marginatum centrifugum (KMC) (Fig. 1). No loss of MMR immunohistochemical markers was observed in the tumors, and the lesions were successfully treated with intralesional 5-fluorouracil and oral retinoids. A screen analysis of the *TGFBR1* gene and a likely pathogenic c.301 T>C heterozygous variant was detected.

Patient 2 was an otherwise healthy 38-year-old male who developed a rapidly growing KA measuring 13 mm on the nose. His father had died at age 53 after developing metastatic colon cancer. MMR immunohistochemical



**Figure 1** Keratoacanthoma marginatum centrifugum. Dome-shaped keratinizing pink to skin-colored nodules 1 to 2 centimeters in diameter with a central keratotic plug, distributed at the periphery of the previous radiation field (left forearm).

showed loss of MSH2 and MSH6. The lesion was treated with intralesional methotrexate, showing complete regression in a 12-week period. A constitutional c.142G>T heterozygous mutation in the *MSH2* gene (predicted to generate a truncating protein, p.Glu48\*) was identified by means of a next generation sequencing panel and a Sanger sequencing validation, confirming the diagnosis of Lynch syndrome.

Patient 3 was an otherwise healthy male with no family history who developed a 17 mm diameter KA in the cervical region at age 38. The lesion was surgically excised and MMR immunohistochemical stains showed loss of MSH2 and MSH6. A germinal MMR gene study showed a large deletion (c.(?..68)..1276+?del) involving exons 1 to 7 in the *MSH2* gene, confirming the diagnosis of Lynch syndrome, MTS subtype. The patient developed a high grade pT2 carcinoma in the ureter at age 41. Several facial sebaceous adenomas and a KA in the cervical region have also been removed to date.

The development of solitary or multiple KAs at a young age may be the presenting sign of genetic disorders which may be associated with malignant neoplasms. Recognizing such associations is important in order to prevent possible complications.

MSSE, an autosomal dominant disease, is caused by mutations in the *TGFBR1* gene together with permissive variants at a locus near the *TGFBR1* locus on chromosome 9<sup>2</sup>. Patients

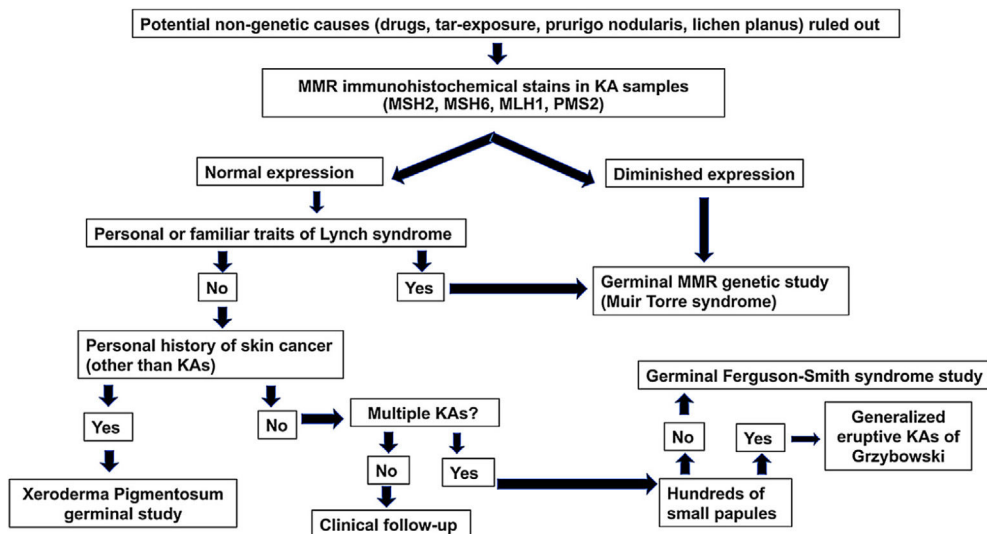
<https://doi.org/10.1016/j.ad.2020.09.017>

0001-7310/© 2021 AEDV. Published by Elsevier España, S.L.U. This is an open access article under the CC BY-NC-ND license (<http://creativecommons.org/licenses/by-nc-nd/4.0/>).

**Table 1** Cases reported in the literature of patients with Muir-Torre syndrome-associated keratoacanthomas.

Author, year	Sex	Number of KAs	Age of presentation (years)	Location	Loss MMR (IHC) In KA	MSI	Other skin lesions	Visceral tumour in the proband (age in years)	Family history of visceral malignancies	Germinal mutation
Muir et al, 1967 <sup>7</sup>	M	6	32	Face	NR	NR	NR	-Larynx squamous cell carcinoma (38) -Adenocarcinoma duodenum/ileum (40)	No	NR
Mangold et al, 2004 <sup>6</sup>	NR	1	50	NR	MSH2	Yes	-Sebaceous adenoma	-Transitional cell carcinoma ureter (66)	-Uterine cancer, small intestinal cancer, abdominal cancer (mother)	MSH2 (c.1578delC)
Mangold et al, 2004 <sup>6</sup>	NR	Multiple	57	NR	NR	Yes	-Squamous cell carcinoma	-Carcinoma of jejunum (66)	-Breast cancer (maternal uncle)	MSH2 (Deletion exons 9,10)
Mangold et al, 2004 <sup>6</sup>	NR	1	67	NR	NR	NR	Multiple sebaceous tumours	-Urothelial carcinoma (56)	-Colorectal cancer (brother)	MSH2 (c.2005. 2T>C)
Mangold et al, 2004 <sup>6</sup>	NR	Multiple	52	NR	No	Yes	Sebaceous hyperplasias	-Multiple colon carcinomas (age unknown)	-Colorectal cancer (father, brother)	MSH2 (c1571. G>C)
Ponti et al, 2005 <sup>8</sup>	M	4	-34 -44	-Neck -Chest -Head	MSH2/MSH6	Yes	Sebaceous cysts	-Urothelial cancer (52). -Bladder cancer. (53) -Colon carcinomas (54)	-Colon carcinoma (father)	MSH2(c2131C>T)
Ponti et al, 2005 <sup>8</sup>	F	2	-86	Head	-MLH1	Yes	NR	-Renal pelvis (54)	-Bladder -Breast	NR
Stella et al, 2007 <sup>11</sup>	NR	NR	NR	NR	NR	NR	NR	Gastric (89)	-Breast -Gastric	NR
South et al, 2008 <sup>5</sup>	F	1	39	NR	-MLH1	NR	-Sebaceous adenoma	Colon (46)	NR	MSH2 (exons 1-6 deletion) MLH1 (c.1489delC)
South et al, 2008 <sup>5</sup>	M	1	57	NR	NR	NR	NR	None	Colon (daughter)	MSH2 (c942. 3A>T)
South et al, 2008 <sup>5</sup>	M	1	41	NR	NR	NR	NR	Colon (41)	NR	MSH2 (c942. 3A>T)
South et al, 2008 <sup>5</sup>	F	1	63	NR	NR	NR	NR	-Endometrial (64) -Colon (71)	NR	MSH2 (c942. 3A>T)
South et al, 2008 <sup>5</sup>	M	1	56	NR	NR	NR	NR	-Colon (58)	NR	MSH2 (c942. 3A>T)
South et al, 2008 <sup>5</sup>	M	1	50	NR	NR	NR	NR	-Colon (60)	NR	MSH2 (Exon 1-6, delet)
Frogatt et al, 1995 <sup>10</sup>	F	1	50	NR	NR	NR	NR	Colon (50)	NR	MSH2 linkage
Current report	M	1	38	Nose	MSH2/MSH6	NP	No	Uterine (50) None	-Colon adenocarcinoma (father)	MSH2 (c142 G>T)
Current report	M	2	38	Neck	MSH2/MSH6	NP	Sebaceous adenomas	Urothelial carcinoma (41)	None	MSH2 (c.(?.68)_1276+?del)

Abbreviations: KA: Keratoacanthoma; M: Male; F: Female; NR: Not reported; MMR: Mismatch repair protein expression; IHC: Immunohistochemistry.



**Figure 2** Diagnostic algorithm for patients who are 50 years or younger and develop sporadic KAs. Abbreviations: MMR, mismatch repair.

with MSSE develop multiple lesions which grow slowly and resolve within months, while new lesions appear. There is variable penetrance, ranging from asymptomatic carriers to patients developing lesions from the first to the seventh decade of life. Some patients may show KCM lesions, characterized by the development of coral reef-like lesions with progressive peripheral expansion and atrophic central healing. The development of KCM after radiotherapy, should suggest the diagnosis of MSSE<sup>3</sup>. Alternative treatment modalities such as oral retinoids, corticosteroids or intralesional/systemic methotrexate can be used.<sup>4</sup>

XP is associated with the early development of skin cancer but KAs are seldom the first tumor manifestation. MTS is reported in 10-30% of families with Lynch syndrome mainly harboring mutations of *MSH2* or *MLH1* genes<sup>5,6</sup>. MMR immunohistochemical markers should be assayed on tumor samples from patients with sebaceous cutaneous neoplasms, multiple KAs and/or appearing at a young age. However, the lack of expression of MMR proteins in sebaceous neoplasms is not exclusive to patients with MTS and some cases which maintain the expression of the MMR proteins have an underlying germline DNA repair defect.

A literature review shows that approximately 89% of the patients with MTS-associated KAs harbor *MSH2* mutations, (Table 1), which is in accordance with the reported mutational prevalence of non-KA cutaneous neoplasms in MTS<sup>5–10</sup>. MTS-associated KAs<sup>7</sup> are often indistinguishable histologically from sporadic KAs. KAs in patients with MTS usually develop before the diagnosis of visceral neoplasms is performed, while sebaceous tumors in MTS are commonly detected after the diagnosis of visceral malignancies.

A diagnostic algorithm (Fig. 2) for patients who are 50 years or younger and develop sporadic KAs is proposed. This algorithm rests on three pillars: the presence of a family history of KAs/colorectal cancer, immunohistochemical stains for MMR proteins and genetic studies of MMR genes and germline alterations in the *TGFBR1* gene.

## Acknowledgements

We thank Dr Marta Pineda, Joan Brunet, Eleanor Reavey and David Goudie for assistance with the genetic study of the cases reported in this work and for comments that improved the manuscript.

## References

1. Kwiek B, Schwartz RA. Keratoacanthoma (KA): an update and review. *J Am Acad Dermatol*. 2016;74:1220–33.
2. Kang HC, Quigley DA, Kim I-J, Wakabayashi Y, Ferguson-Smith MA, D'Alessandro M, et al. Multiple self-healing squamous epithelioma (MSSE): rare variants in an adjacent region of chromosome 9q22.3 to known *TGFBR1* mutations suggest a digenic or multilocus etiology. *J Invest Dermatol*. 2013;133:1907–10.
3. Lindsay DP, Kharofa J, Junck M, Olasz E, Wilson JF. Eruptive keratoacanthomas after radiation therapy for keratoacanthoma centrifugum marginatum. *Pract Radiat Oncol*. 2015;5:203–6.
4. Mangas C, Bielsa I, Ribera M, Fernández-Figueras MT, Ferrándiz C. A case of multiple keratoacanthoma centrifugum marginatum. *Dermatol Surg Off Publ Am Soc Dermatol Surg Al*. 2004;30:803–6.
5. South CD, Hampel H, Comeras I, Westman JA, Frankel WL, de la Chapelle A. The frequency of Muir-Torre syndrome among Lynch syndrome families. *J Natl Cancer Inst*. 2008;100:277–81.
6. Mangold E, Pagenstecher C, Leister M, Mathiak M, Rütten A, Friedl W, et al. A genotype-phenotype correlation in HNPCC: strong predominance of *msh2* mutations in 41 patients with Muir-Torre syndrome. *J Med Genet*. 2004;41:567–72.
7. Muir EG, Bell AJ, Barlow KA. Multiple primary carcinomata of the colon, duodenum, and larynx associated with keratoacanthomata of the face. *Br J Surg*. 1967;54:191–5.
8. Ponti G, Losi L, Di Gregorio C, Roncucci L, Pedroni M, Scarselli A, et al. Identification of Muir-Torre syndrome among patients with sebaceous tumors and keratoacanthomas: role of clinical features, microsatellite instability, and immunohistochemistry. *Cancer*. 2005;103:1018–25.

9. Stella A, Surdo NC, Lastella P, Barana D, Oliani C, Tibiletti MG, et al. Germline novel MSH2 deletions and a founder MSH2 deletion associated with anticipation effects in HNPCC. *Clin Genet.* 2007;71:130–9.
10. Froggatt NJ, Koch J, Davies R, Evans DG, Clamp A, Quarrell OW, et al. Genetic linkage analysis in hereditary non-polyposis colon cancer syndrome. *J Med Genet.* 1995;32:352–7.
11. Stella A, Surdo NC, Lastella P, Barana D, Oliani C, Tibiletti MG, et al. Germline novel MSH2 deletions and a founder MSH2 deletion associated with anticipation effects in HNPCC. *Clin Genet.* 2007;71:130–9.

<sup>b</sup> *Departamento de Dermatología, Hospital Universitari Josep Trueta, Girona, Spain*

<sup>c</sup> *Departamento de Dermatología, Hospital del Mar, Universitat Autònoma de Barcelona (UAB), Barcelona, Spain*

<sup>d</sup> *Grupo de Enfermedades Dermatológicas Inflammatorias y Neoplásicas, IMIM (Hospital del Mar Medical Research Institute), Barcelona, Spain*

Corresponding author.

E-mail address: [atoll@clinic.cat](mailto:atoll@clinic.cat) (A. Toll).

A. Toll<sup>a,\*</sup>, D. Sitjas<sup>b</sup>, D. Morgado-Carrasco<sup>a</sup>, R.M. Pujol<sup>c,d</sup>

<sup>a</sup> *Departamento de Dermatología, Hospital Clínic de Barcelona, Universidad de Barcelona, Barcelona, Spain*