

asistencia sanitaria pública. Son necesarias series más amplias que constaten la utilidad real de esa medicación.

Conflicto de intereses

Los autores declaran no tener ningún conflicto de intereses.

Bibliografía

1. Del Boz J. Tratamiento sistémico de la hiperhidrosis. *Actas Dermosifiliogr.* 2015;106:271-7.
2. Toledo-Pastrana T. Nuevas perspectivas en hiperhidrosis. *Piel.* 2016;31:360-4.
3. Schollhammer M, Brenaut E, Menard-Andivot N, Pillette-Delarue M, Zagnoli A, Chassain-Le Lay M, et al. Oxybutynin as a treatment for generalized hyperhidrosis: A randomized, placebo-controlled trial. *Br J Dermatol.* 2015;173:1163-8.
4. Wolosker N, Krutman M, Teivelis MP, Campbell TP, Kauffman P, de Campos JR, et al. Quality of life before hyperhidrosis treatment as a predictive factor for oxybutynin treatment outcomes in palmar and axillary hyperhidrosis. *Ann Vasc Surg.* 2014;28:970-6.
5. Millan-Cayetano JF, del Boz J, Rivas-Ruiz F, Blázquez-Sánchez N, Hernández Ibáñez C, de Troya-Martín M. Oral oxybutynin for

the treatment of hyperhidrosis: Outcomes after one-year follow-up. *Australas J Dermatol.* 2016, <http://dx.doi.org/10.1111/ajd.12473>.

T. Toledo-Pastrana^{a,*}, J. Márquez-Enríquez^b y J.F. Millán-Cayetano^c

^a Servicio de Dermatología, Hospital Universitario Donostia, San Sebastián, Guipúzcoa, España

^b Unidad de Gestión Clínica de Medicina Interna-Dermatología, Hospital de Jerez, Jerez de la Frontera, Cádiz, España

^c Servicio de Dermatología, Hospital Costa del Sol, Marbella, Málaga, España

* Autor para correspondencia.

Correo electrónico: ttoledop@gmail.com (T. Toledo-Pastrana).

<http://dx.doi.org/10.1016/j.ad.2016.11.013>
0001-7310/

© 2016 AEDV.

Publicado por Elsevier España, S.L.U. Todos los derechos reservados.

Sorafenib-induced Acute Generalized Exanthematous Pustulosis: An Increasing Association?



Pustulosis exantemática generalizada aguda por sorafenib: ¿una relación en aumento?

Dear Editor,

Acute Generalized Exanthematous Pustulosis (AGEP) is an acute eruption considered as a severe cutaneous adverse reaction (SCAR) related to drugs. Although antibiotics are the most common triggers, many other drugs have been associated with AGEP. More rarely, cases of non-drug-related AGEP have been reported, due to viral or bacterial infections, spider bites or mercury hypersensitivity.¹ Here, we present the case of an AGEP triggered by the kinase-inhibitor

Sorafenib and we expose a brief review of similar cases reported.

A 78-year-old woman presented to the Emergency Department with a 6-week history of an extensive, pruriginous exanthema consisting of erythematous and edematous plaques in the face, chest and upper extremities, with small isolated pustules (Fig. 1). Mucous membrane involvement was confined to the lips. Neither fever nor other systemic symptoms were evident. Two months before, she had initiated treatment with sorafenib due to an unresectable hepatocarcinoma. Skin reaction developed gradually two days after initiating the treatment.

Laboratory examination revealed a hypereosinophilia of $1.4 \times 10^9/L$. A skin biopsy was performed, rendering typical histological features of AGEP (Fig. 2). Attending to the validated EuroSCAR scoring system,² our case was then classified as a *Probable* AGEP. Sorafenib was discontinued immediately, and treatment with intravenous methylprednisolone 1 mg/kg was initiated. Cutaneous lesions improved

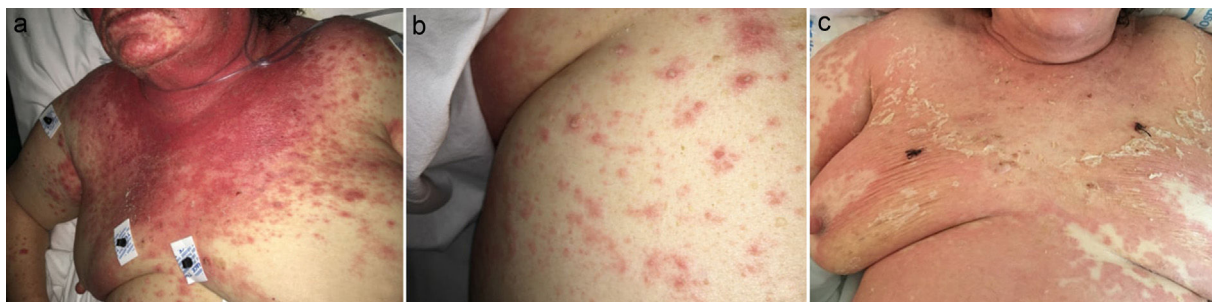

Figure 1 Clinical evolution. (a) Exanthema affecting mainly face, upper trunk, superior limbs with isolated patches on abdomen and lower extremities. (b) Closer image showing isolated pustules surrounded by erythema. (c) Evolution of the exanthema 5 days after Sorafenib discontinuation. Mild erythema and desquamation on upper trunk with pustules resolution.

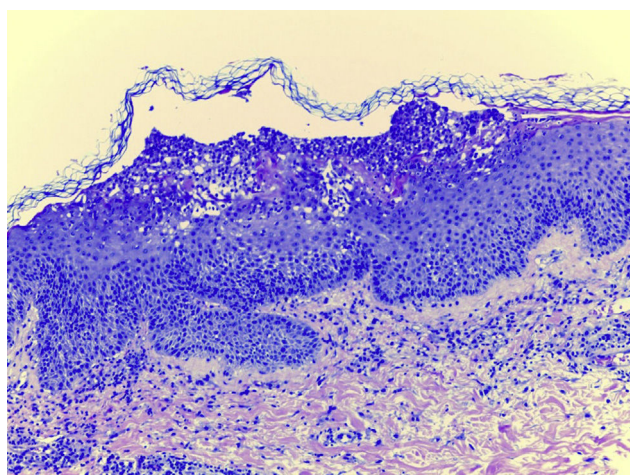


Figure 2 Histopathology. HE 10×. Neutrophilic spongiotic subcorneal pustules. Perivascular infiltrate with lymphocytes and eosinophiles.

rapidly and were almost totally resolved after a week. This clinical evolution strongly supports the diagnosis of sorafenib-induced AGEF.

AGEF is characterized by numerous, small, non-follicular and sterile pustules arising within extensive areas of edematous erythema. Fever and leukocytosis are common findings and severe cases of AGEF can associate visceral involvement. Mucous membrane might also be affected. Time interval between drug administration and the skin eruption onset is typically 48h, although it varies from 1 day to 4 weeks. It typically resolves in two weeks after drug discontinuation.^{1,2} Main differential diagnoses of AGEF are other pustular diseases, such as pustular psoriasis, and other severe cutaneous adverse reactions, such as Stevens Johnson syndrome (SJS) or Toxic Epidermal Necrolysis. Compared to AGEF, in SJS/NET, mucosal involvement and skin detachment (Nikolsky sign) are a constant. However, the possibility of overlap of different severe cutaneous reactions have been recently discussed in the literature.³

Sorafenib is a multikinase inhibitor that mainly target tumor cell angiogenesis, first used in advanced renal cell cancer and unresectable hepatocellular carcinoma with recent indications in other cancers.⁴ It inhibits multiple tyrosine-kinases, such as RAF-1 and B-RAF, and it blocks tyrosine-kinases receptors, such as platelet-derived growth factor receptor (PDGFR), related with carcinogenesis.⁷

Patients under treatment with multikinase inhibitors usually develop cutaneous reactions. In a prospective study, up to 72% of the patients taking sorafenib presented dermatological symptoms.^{4,7} Most of these reactions are maculopapular rashes and other grade 1–2 severity adverse reactions that can be easily managed. Other non-severe skin reactions that can be found are hand–foot skin reaction, stomatitis, subungual splinter hemorrhages, facial erythema or alopecia.^{4,7}

However, some of these patients develop SCARs related to sorafenib, such as Drug Reaction with Eosynophilia and Systemic Symptoms (DRESS), SJS or AGEF.^{5,6,8,9}

To our knowledge, only 2 more cases of sorafenib-induced acute exanthematous pustulosis have been published, being one of them an acute localized exanthematous pustulosis

Table 1 Demographical and clinical features of sorafenib-induced AGEF/ALEP cases.

Case	Sex, age (years old)	Sorafenib indication	Latency	Distribution	Fever	Laboratory abnormalities	Mucosal involvement	Skin biopsy	Resolution
Liang, CP et al. (2011) ⁵	Woman, 59 yo	Hepatocarcinoma	2 weeks	Localized: lower limbs	No	No	No	Subcorneal pustules with intraepidermal spongiform	Spontaneous improvement after sorafenib discontinuation
Pretel, M et al. (2014) ⁶	Woman, 50 yo	Hepatocarcinoma	4 weeks	Generalized: neck, abdomen, buttocks and lower limbs	No	Neutrophilia $7.1 \times 10^9/L$	No	Subcorneal pustules with papillary edema	Spontaneous improvement after sorafenib discontinuation
Our case (2016)	Woman, 78 yo	Hepatocarcinoma	2 days	Generalized: chest, neck, facial area and upper limbs	No	Eosinophilia $1.4 \times 10^9/L$	Labial mucosa desquamation	Subcorneal pustules with papillary edema. Low necrosis keratinocyte and isolated eosinophils	Improvement after sorafenib discontinuation and corticosteroids treatment

(ALEP) and the other one a complete AGEF.^{5,6} The main features of these cases are presented in Table 1. Interestingly, all the three cases occurred in women who were under treatment with sorafenib due to unresectable hepatocarcinoma. Cases of AGEF have also been reported associated with other multikinase inhibitors such as imatinib.¹⁰ Therefore; we believe that the association between kinase-inhibitors and AGEF might be an under-reported entity with an increasing incidence due to the appearance of new drugs of this nature.

In conclusion, we report a new case of sorafenib-induced AGEF. We should be aware of this cutaneous side effect of sorafenib and other multikinase inhibitors, given that drug discontinuation is the key point on AGEF treatment.

Conflict of interests

The authors declare no conflict of interest.

Bibliografía

- Szatkowski J, Schwartz RA. Acute generalized exanthematous pustulosis (AGEP): a review and update. *J Am Dermatol*. 2015;73:843–8.
 - Sidoroff A, Halevy S, Bavinck JN, Vaillant L, Roujeau JC. Acute generalized exanthematous pustulosis (AGEP): a clinical reaction pattern? *J Cutan Pathol*. 2001;28:113–9.
 - Horcajada-Reales C, Pulido-Pérez A, Suárez-Fernández R. Toxicodermias graves: ¿existen las formas combinadas? *Actas Dermo-sifiliográficas*. 2016;107:23–33.
 - Robert C, Mateus C, Spatz A, Wechsler J, Escudier B. Dermatologic symptoms associated with the multikinase inhibitor sorafenib. *J Am Dermatol*. 2009;60:299–305.
 - Liang CP, Yang CS, Shen JL, Chen YJ. Sorafenib-induced acute localized exanthematous pustulosis in a patient with hepatocellular carcinoma. *Br J Dermatol*. 2011;165:443–5.
 - Pretel M, Iñarrairaegui M, Lera JM, Aguado L, Idoate MA. Acute generalized exanthematous pustulosis induced by sorafenib. *JAMA Dermatol*. 2014;150:664–6.
 - Reyes-Habito CM, Roh EK. Cutaneous reactions to chemotherapeutic drugs and targeted therapies for cancer. Part II. Targeted therapies. *J Am Dermatol*. 2014;71:217.e1–11.
 - Kim DK, Lee SW, Nam HS, Jeon DS, Park NR, Nam YH, et al. A case of Sorafenib-induced DRESS syndrome in hepatocellular carcinoma. *Korean J Gastroenterol*. 2016;67:337–40. <http://dx.doi.org/10.4166/kjg.2016.67.6.337>.
 - Sohn KH, Oh SY, Lim KW, Kim MY, Lee SY, Kang HR. Sorafenib induces delayed-onset cutaneous hypersensitivity: a case series. *Allergy Asthma Immunol Res*. 2015;7:304–7. <http://dx.doi.org/10.4168/aaair.2015.7.3.304>.
 - Scott AD, Lee M, Kubba F, Chu A. Acute generalized exanthematous pustulosis (AGEP) secondary to imatinib in a patient with chronic myeloid leukaemia. *Clin Exp Dermatol*. 2015;40:926–7.
- A. Alegre-Sánchez^{a,*}, D. de Perosanz-Lobo^a,
I. Pinilla-Pagnon^b, E. Muñoz-Zato^a
- ^a *Dermatology Service, Ramon y Cajal Hospital, Madrid, Spain*
^b *Pathology Service, Ramon y Cajal Hospital, Madrid, Spain*
- *Corresponding author.
E-mail address: adrian.alegresanchez@gmail.com
(A. Alegre-Sánchez).
- <http://dx.doi.org/10.1016/j.ad.2016.11.018>
0001-7310/
© 2017 AEDV. Published by Elsevier España, S.L.U. All rights reserved.

Expanding the Genotype of Sjögren–Larsson Syndrome: A New Case Due to Two Novel Mutations



Ampliando el genotipo del síndrome de Sjögren-Larsson: un nuevo caso causado por dos nuevas mutaciones

Dear Editor,

Sjögren–Larsson syndrome (SLS) is a rare genetic disorder with autosomal recessive inheritance,^{1,2} characterized by clinical triad of congenital ichthyosis, spastic diplegia or tetraplegia and mental retardation.^{1,3,4} We report a new patient affected by SLS due to two unreported mutations.

A 6 months male child was referred to our hospital because of congenital erythroderma and subsequent development of generalized fine scaling and persistent pruritus. He was the first child of non-consanguineous parents, born at 33 weeks of gestation. There was no history suggestive of a collodion membrane at birth, and no family history of ichthyosis. On physical examination we observed

generalized fine desquamation on the limbs and trunk without underlying erythema (Fig. 1A) and hyperkeratotic skin on the armpits (Fig. 1B), palms and soles (Fig. 1C). Hair and nails appeared normal. Given that an ichthyosis was the diagnosis suspected, a skin biopsy from an armpit was made. Histological study showed hyperkeratosis, psoriasiform epidermal hyperplasia, a prominent granular layer in some areas of the epidermis and mild perivascular inflammatory infiltrate of mononuclear cells in papillary dermis (Fig. 2), resulting compatible with a congenital ichthyosis. The rest of the physical exam showed the patient had macrocephaly, mild psychomotor retardation, mild axial hypotonia, incipient signs of spasticity in the lower limbs, and occasional spasms. A transfontanelar ultrasound showed benign external hydrocephaly, which was confirmed in a brain magnetic resonance imaging where others anomalies were not observed. Given the coexistence of congenital ichthyosis and neurological signs, our clinical suspicion was a neurocutaneous disorder. Ophthalmologic examination, peripheral blood smear, peripheral blood analysis and abdominal ultrasound were normal. Genetic analysis of the patient confirmed the diagnosis of Sjögren–Larsson syndrome (SLS) by identifying two unreported heterozygous ALDH3A2 mutations, a deletion mutation c.154_155delAG