



# ACTAS Dermo-Sifiliográficas

Full English text available at  
[www.actasdermo.org](http://www.actasdermo.org)



## IMAGE IN DERMATOLOGY

### [Translated article] Ultrasound of Storiform Collagenoma

#### Ecografía del collagenoma estoriforme

L. Fernández-Fuente\*, S. Herrero-Ruiz, B. Echeverría-García

*Servicio de Dermatología, Hospital Universitario de Fuenlabrada, Madrid, Spain*

A 23-year-old man, with PTEN hamartoma tumor syndrome (loss of exon 6 of the PTEN gene), presented with a 1-year history of asymptomatic lesion on his right forearm.

Upon examination, a well-demarcated, pink, exophytic nodule 18 mm in diameter, and of elastic consistency is observed on the dorsum of the right forearm. Dermoscopy reveals the presence of a nodular lesion with a homogeneous whitish background, with perilesional erythema and arborizing vessels on the surface.

With the clinical diagnosis of either a sclerotic fibroma or a basal cell carcinoma, a cutaneous ultrasound is performed. With 18 and 22 MHz probes, a hypoechoic, well-demarcated 13.1 mm × 19 mm × 22 mm tumor is revealed, located in the dermal plane and subcutaneous cellular tissue. Doppler mode shows increased peripheral vascularization with small vessels of arterial flow characteristics (Fig. 1).

These findings allow us to rule out the presence of basal cell carcinoma, given the absence of hyperechoic punctation on the ultrasound and, in the patient's clinical context, guide diagnosis towards a storiform collagenoma. The ultrasound image is consistent with previous descriptions of storiform collagenoma, adding the increased peripheral

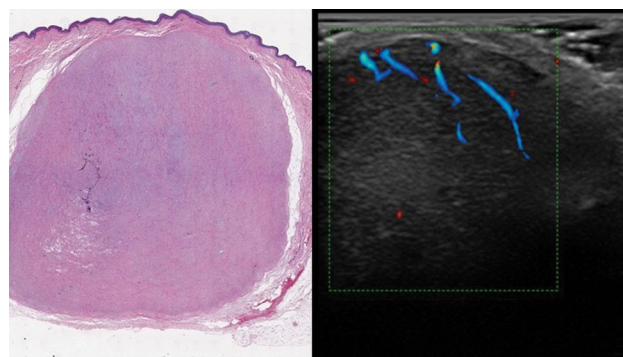


Figure 1

vascularization, which is consistent with telangiectasias in the histology and dermoscopy of the lesion.

The ultrasound of storiform collagenoma correlates with the clinical diagnosis and the dermoscopic and histological characteristics previously described for this lesion and supports its diagnosis, avoiding biopsies in selected cases.

DOI of original article:

<https://doi.org/10.1016/j.ad.2023.10.058>

\* Corresponding author.

E-mail address: [lfdelafuente@salud.madrid.org](mailto:lfdelafuente@salud.madrid.org)

(L. Fernández-Fuente).

<https://doi.org/10.1016/j.ad.2025.03.022>

0001-7310/© 2025 AEDV. Published by Elsevier España, S.L.U. This is an open access article under the CC BY-NC-ND license (<http://creativecommons.org/licenses/by-nc-nd/4.0/>).

Please cite this article as: L. Fernández-Fuente, S. Herrero-Ruiz and B. Echeverría-García, [Translated article] Ultrasound of Storiform Collagenoma, ACTAS Dermo-Sifiliográficas, <https://doi.org/10.1016/j.ad.2025.03.022>