

A Case of Eruptive Disseminated Porokeratosis in a Cancer Patient after Trastuzumab and Exemestane Treatment: Cancer Related or Drug Induced Phenomenon?☆



Un caso de poroqueratosis diseminada eruptiva en un paciente oncológico tratado con trastuzumab y exemestano: ¿fenómeno asociado al cáncer o inducido por fármacos?

To the editor:

We report a rare skin toxicity in a 62-years-old white female with a history of an estrogen receptor- and progesterone receptor-positive (95% and 50% of tumor cells, respectively) human epidermal growth factor receptor 2 (HER2)-positive invasive ductal carcinoma of the left breast (initial stage pT2 pN1a M0). She underwent radical modified mastectomy plus axillary node dissection followed by adjuvant treatment with 1 year of trastuzumab and 5 years of the aromatase inhibitor letrozole. Six years after the diagnosis, the patient developed bone and internal mammary lymph node metastases treated with exemestane and trastuzumab. Two months after starting treatment, she developed non-painful but slightly itching diffuse skin lesions. She showed multiple, disseminated, brown-grey oval macules, slightly palpable, well delimited, 2-5 mm in diameter, many with collarettes of scale. Lesions were located in both sun-exposed and non-sun-exposed sites, predominantly in the back, trunk and upper extremities (Figure 1). The biopsy of a back lesion revealed a focal thinning of the epidermis, with loss of the granular layer and a discrete column of parakeratosis (Figure 2). Symptomatic treatment with topical bethametasone and salicyl acid was initiated with resolution of pruritus. Patient did not accept the proposed systemic treatment with Acitretinon nor Tacalcitol ointment. The patient is still receiving the combined therapy after achieving a complete disease remission and macules persist unchanged without dose reductions or lengthening of treatment intervals. No new skin adverse reactions were observed.

Trastuzumab is a monoclonal antibody that binds to the extracellular domain of HER2 and exemestane is an aromatase inhibitor which suppresses plasma oestrogen levels by inhibition of the enzyme aromatase. Acne vulgaris, nail changes, pruritus, leukopenia and more rarely cellulitis, dermal ulcer and erysipela have been described under trastuzumab treatment. Alopecia, dermatitis, itching, acute generalized exanthematous pustulosis, pruritus and urticaria were reported for exemestane.¹

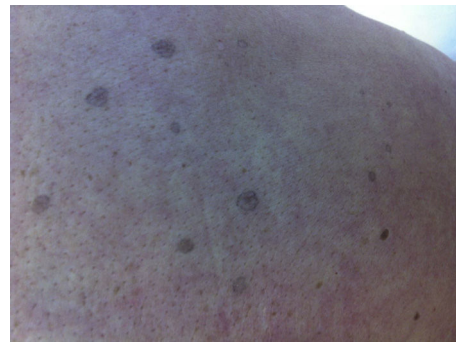

Figure 1 Brown-grey oval macules, slightly palpable, well delimited, 2-to-5mm in diameter, many with collarettes of scale.

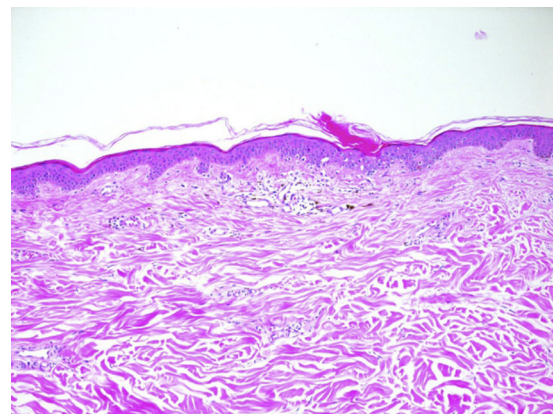


Figure 2 Histopathology (hematoxylin and eosin; magnification 10x) shows the typical pattern of porokeratosis with central column of parakeratosis (cornoid lamella) and dyskeratotic keratinocytes.

Porokeratosis is a heterogeneous group of hereditary or acquired disorders of keratinization believed to arise from an expansion of abnormal keratinocytes. Multiple variants of porokeratosis have been described.^{2,3} Recently, a new entity named Eruptive porokeratosis has been reported to describe cases of acute, disseminated eruptions.³ Pathogenesis is not well understood. Some proposed triggering factors include genetics, ultraviolet light exposure, infection, and immunosuppression (ie, transplant recipients, retroviral disease).^{2,4-6} Some reports of drug-induced cases are also reported, mainly due to immunosuppressing drugs (ie, prednisone, antirheumatic drugs, biologics).³⁻⁵ Some authors speculate that porokeratosis, specially the eruptive form, may represent a paraneoplastic manifestation since it has been described in association with hematopoietic malignancies or solid organ tumors (ie, hepatocellular carcinoma, cholangiocarcinoma, ovarian cancer).³⁻⁷ The typical histological feature of porokeratosis is the cornoid lamella, which corresponds to the border between normal epidermis and the clone of mutant keratinocytes. Prognosis of porokeratosis is generally good but some cases of squamous cell carcinoma developed on porokeratosis have been described, suggesting porokeratosis as a possible pre-cancer situation. Proposed treatments are photodynamic

☆ Please cite this article as: Mangas C, Espeli V, Blum R. Un caso de poroqueratosis diseminada eruptiva en un paciente oncológico tratado con trastuzumab y exemestano: ¿fenómeno asociado al cáncer o inducido por fármacos?. *Actas Dermosifiliogr.* 2018;109:559-560.

therapy, local tacalcitol or Acitretinoin for disseminated variants.^{2,3}

No data have been reported so far about the link between porokeratosis and exemestane or trastuzumab. As the patient is still receiving the same oncological treatment, persistence of the lesions could be linked with either the immunotherapy or the antihormonal therapy. Porokeratosis is a disorder of keratinization and antibodies targeting the HER-family receptors can cause disorders at this level. The possibility that eruptive porokeratosis must be considered as a paraneoplastic phenomenon in our case cannot be completely ruled out. Nevertheless, the long period of time between both conditions, the fact that skin eruption persists although tumor response to the treatment and a time association with the treatment starting supports a drug induced phenomenon in our opinion.

Références

1. Macdonald JB, Macdonald B, Golitz LE, LoRusso P, Sekulic A. Cutaneous adverse effects of targeted therapies: Part II: Inhibitors of intracellular molecular signaling pathways. *J Am Acad Dermatol*. 2015;72:221–36.
2. Brauer JA, Mandal R, Walters R, Solomon G, Kundu RV, Strober BE. Disseminated superficial porokeratosis. *Dermatol Online J*. 2010 15;16:20.
3. Shoimer I, Robertson LH, Storwick G, Haber RM. Eruptive disseminated porokeratosis: A new classification system. *J Am Acad Dermatol*. 2014;71:398–400.
4. Jung JY, Yeon JH, Ryu HS, Youn SW, Park KC, Huh CH. Disseminated superficial porokeratosis developed by immunosuppression due to rheumatoid arthritis treatment. *J Dermatol*. 2009;36:466–7.
5. Buhl T, Wienrich BG, Sieblist C, Schön MP, Seitz CS. Development of segmental superficial actinic porokeratosis during immunosuppressive therapy for pemphigus vulgaris. *Acta Derm Venereol*. 2010;90:212–3.
6. Goulding JM, Teoh JK, Carr RA, Humphreys F, Gee BC. Eruptive disseminated superficial porokeratosis with rapid resolution: A drug-induced phenomenon? *Clin Exp Dermatol*. 2009;34:875–95.
7. Torres T, Velho GC, Selores M. Disseminated superficial porokeratosis in a patient with cholangiocarcinoma: A paraneoplastic manifestation? *An Bras Dermatol*. 2010;85:229–31.

C. Mangas,^{a,*} V. Espeli,^b R. Blum^c

^a *Unidad de Dermatología, Hospital Regional de Bellinzona e Valli, Bellinzona, Suiza*

^b *Oncology Institute of Italian Switzerland (IOSI), Bellinzona, Suiza*

^c *Unidad de Dermatología, Inselspital, Hospital Universitario de Berna, Berna, Suiza*

* Corresponding author.

E-mail addresses: cris.mangas@yahoo.es, cristina.mangas@eoc.ch (C. Mangas).

1578-2190/

© 2017 Elsevier España, S.L.U. and AEDV. All rights reserved.

Expanding the genetic profile of Hay-Wells syndrome[☆]



Ampliando el perfil genético del síndrome de Hay-Wells

To the Editor:

Hay-Wells syndrome, also known as AEC syndrome (ankyloplepharon-ectodermal dysplasia-clefting syndrome, Online Mendelian Inheritance in Man [OMIM] 106260) is a rare, autosomal dominant genetic disorder, associated with a heterozygous mutation in the TP63 gene. AEC syndrome is defined by ectodermal abnormalities of the skin, teeth, hair, and nails, in combination with characteristic eyelid fusion and facial clefting.^{1,2} Other distinct autosomal dominant developmental disorders have been associated with the TP63 gene, including Rapp-Hodgkin syndrome (RHS; OMIM 129400), ectrodactyly-ectodermal dysplasia-cleft lip/palate syndrome (EEC syndrome; OMIM 604292), acro-dermato-ungual-lacrimal-tooth syndrome (ADULT syndrome; OMIM 103285), limb-mammary-syndrome (LMS; OMIM 603543) and split hand/foot malformation

syndrome (SHFM syndrome; OMIM 605289). As clinical and even molecular features commonly overlap, it has been proposed that some of these syndromes represent a variable spectrum of the same genetic disorder.³

A 57-year-old woman with a personal history of numerous ophthalmologic surgical procedures was referred to her ophthalmologist for a biopsy of buccal mucosa to rule out cicatricial pemphigoid. Physical examination revealed patchy alopecia of the scalp, eyebrows and eyelids (Figure 1), nail dystrophy, hypodontia and hypohidrosis, all these conditions present since childhood or birth. Furthermore, there was a decreased eye diameter and a tendency to adhesion of the ciliary edges of the eyelids. This situation caused severe photosensitivity (Figure 2). More recently, the patient presented palmoplantar hyperkeratosis. Neither cleft lip nor palate was present.

Diagnosis of ectodermal dysplasia syndrome was proposed, more specifically of Hay-Wells (AEC) syndrome. A punch biopsy specimen from the scalp revealed the presence of rudimentary hair structures, some of which gave rise to *vellus type* hair, and total absence of sebaceous glands (Figure 3).

The patient was offered genetic testing and was found to have an heterozygous Arg243Trp mutation in the TP63 gene (c.727C>T), which was previously reported in the *Human Gene Mutation Database* only associated with a phenotype of EEC syndrome, but never with a phenotype of AEC syndrome. Genetic counselling in family members was offered on several occasions but the patient always refused.

[☆] Please cite this article as: Romero-Pérez D, Encabo-Durán B, Ramón-Sapena R. Ampliando el perfil genético del síndrome de Hay-Wells. *Actas Dermosifiliogr*. 2018;109:560–562.