




ACTAS Derma-Sifiliográficas

Full English text available at
www.actasdermo.org



CASE FOR DIAGNOSIS

Large Hyperpigmented Macule on the Leg of an Adolescent Girl[☆]



Mácula hiperpigmentada extensa en la pierna de una mujer adolescente

Medical History

The patient was a 19-year-old woman with no past history of interest. She came to our outpatients for an asymptomatic brownish macule on the left leg that had appeared at puberty and had progressively increased in size with the patient's growth, until it stabilized. The patient had applied emollients with no improvement.

Physical Examination

In the left pretibial region, extending onto the medial and lateral surfaces of the leg, there was a macular

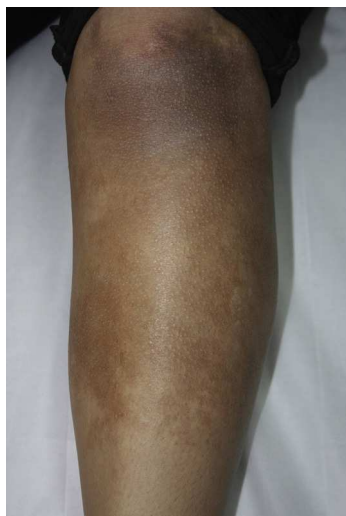

Figure 1

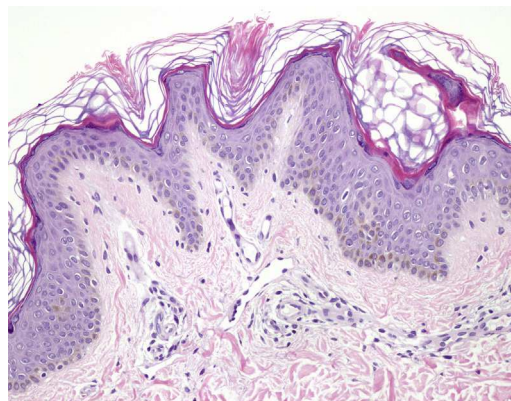


Figure 2 Hematoxylin-eosin, original magnification $\times 20$.

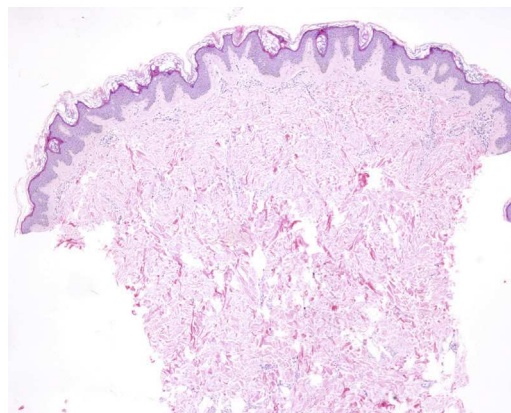


Figure 3 Hematoxylin-eosin, original magnification $\times 4$.

lesion with a homogeneous light-brown color and irregular well-defined borders, measuring approximately 20 cm in diameter (Fig. 1).

Histopathology

Histology of the biopsy revealed an epidermis with orthokeratotic hyperkeratosis, papillomatous hyperplasia, and prominent pigmentation of the basal layer (Fig. 2), with no alterations of the dermis (Fig. 3).

[☆] Please cite this article as: Calderón-Komáromy A, Romero-Maté A, Moreno A. Mácula hiperpigmentada extensa en la pierna de una mujer adolescente. Actas Dermosifiliogr. 2014;105:867–868.

What Is Your Diagnosis?

Diagnosis

Pretibial Becker nevus.

Comment

Becker nevus is a pigmented hamartoma of the skin first described by Becker in 1969. It mainly affects men and typically appears during adolescence. It usually occurs sporadically, though familial cases have been reported. The estimated prevalence is 1% in the general population, but a higher incidence has been recorded in the white population.¹

The etiology is unknown, but androgens have a recognized effect on the development of these lesions. Compared with normal skin, Becker nevus has been shown to have a larger number of androgen receptors.²

Becker nevus usually presents as a single, hyperpigmented macule of several centimeters in diameter, with a unilateral distribution. The lesions tend to arise on the upper region of the trunk and on the proximal areas of the upper limbs. Hypertrichosis is observed in only approximately 50% of cases and typically appears after the hyperpigmentation.

Histology reveals acanthosis, papillomatous hyperplasia, hyperkeratosis, and hyperpigmentation of the basal layer of the epidermis, with no melanocytic proliferation. Hypertrophy of the erector pili muscle may be observed, in addition to fascicles of smooth muscle in the dermis not associated with skin adnexa, but these changes are not always present, as in our patient.

Becker nevus is uncommon on the lower limbs, but it has not been possible to establish whether the low prevalence in this region is genuine or is due to underdiagnosis or to a lack of reports in the literature. Twelve cases of Becker nevus arising in the proximal regions of the lower limbs (above the knees) have been described in the English-language literature³; the patients were 11 men and 1 woman, and hypertrichosis was observed in only 2 cases. There is only 1 previous report in the literature of Becker nevus arising

below the knee. That was in a 16-year-old patient with mental retardation who presented 3 lesions (right forearm and both pretibial regions) clinically and histologically compatible with Becker nevus, with a microdeletion of chromosome 5.⁴

We have presented a patient with a lesion clinically and histologically compatible with Becker nevus in the pretibial region. This is the second case of Becker nevus at this site described in the literature. It is not possible to determine the true prevalence of this condition at this site, nor its prognostic value as a marker for other abnormalities, for which it would be necessary to perform larger studies. We consider that Becker nevus at this site may be less uncommon than is thought, and both diagnostic error and a failure to publish could explain a possible under-recording of such cases.

References

1. Ballone E, Fazii P, Lappa G, Di Mascio R, Di Mascio C, Schioppa F. Prevalence of Becker's nevi in a population of young men in central Italy. *J Am Acad Dermatol*. 2003;48:795.
2. Kim YJ, Han JH, Kang HY, Lee ES, Kim YC. Androgen receptor overexpression in Becker nevus: Histopathologic and immunohistochemical analysis. *J Cutan Pathol*. 2008;35:1121-6.
3. Alhusayen R, Kanigsberg N, Jackson R. Becker nevus on the lower limb: Case report and review of the literature. *J Cutan Med Surg*. 2008;12:31-4.
4. Schepis C, Lentini M, Failla P, Castiglia L, Fichera M, Romano C. An unusual presentation of Becker nevus. *Eur J Dermatol*. 2010;20:522-3.

A. Calderón-Komáromy,^{a,*} A. Romero-Maté,^a A. Moreno^b

^a *Servicio de Dermatología, Hospital Universitario de Fuenlabrada, Madrid, Spain*

^b *Servicio de Anatomía Patológica, Hospital Universitario de Fuenlabrada, Madrid, Spain*

* Corresponding author.

E-mail address: komaromy20@hotmail.com

(A. Calderón-Komáromy).