



CASE AND RESEARCH LETTER

Advancement and Inferior Rotation Nasal Sidewall Flap for Lateral Nasal Tip Reconstruction

Colgajo de rotación inferior y avance del lateral nasal para reconstrucción de defecto lateral de punta nasal

To the Editor,

This article explores the application of the Advancement and Inferior Rotation of the Nasal Sidewall (AIRNS) flap technique to address nasal tip defects. While not a new technique, the AIRNS flap offers several advantages for reconstructing this esthetically important area. The significance of achieving successful reconstruction in the nasal tip highlights the relevance of this approach in dermatological surgery.

This is the case of a healthy 67-year-old woman that presented at our dermatology department with a basal cell carcinoma on her nasal tip. Tumor clearance was achieved through 2 stages of Mohs micrographic surgery resulting in a 1.8 cm wide defect. We designed an AIRNS flap (Fig. 1A).

The AIRNS flap is a local advancement and rotation flap, which uses skin and subcutaneous tissue from the upper nasal sidewall to cover defects preferably oriented horizontally on the nasal tip. The curvature of the flap must extend adequately to cover the entire height of the surgical defect. At the junction of the cheek and the nasal sidewall, this curved portion is, then, connected to a forward extension. A key aspect in creating the AIRNS flap is making sure that the width of the forward extension (the bottom of the triangle) closely matches the vertical measurement of the surgical defect. As the skin replacement is performed with neighboring skin, a good tissue match is ensured (Fig. 1B–D). At 6 months, an excellent functional and esthetic result was obtained (Fig. 1E, F).

The nasal tip is a frequent location for skin cancer which can be extremely challenging to reconstruct.¹ A successful repair in this esthetically important location remains essential in these patients. Consequently, numerous flaps have been described in the literature for the reconstruction of this site defect,² being the bilobed flap one of the most frequently used.³ However, since it has a high propensity to pincushion, it requires a meticulous design and performance to achieve a good functional and esthetic outcome. Two of the main advantages of the AIRNS flap are its low tendency to

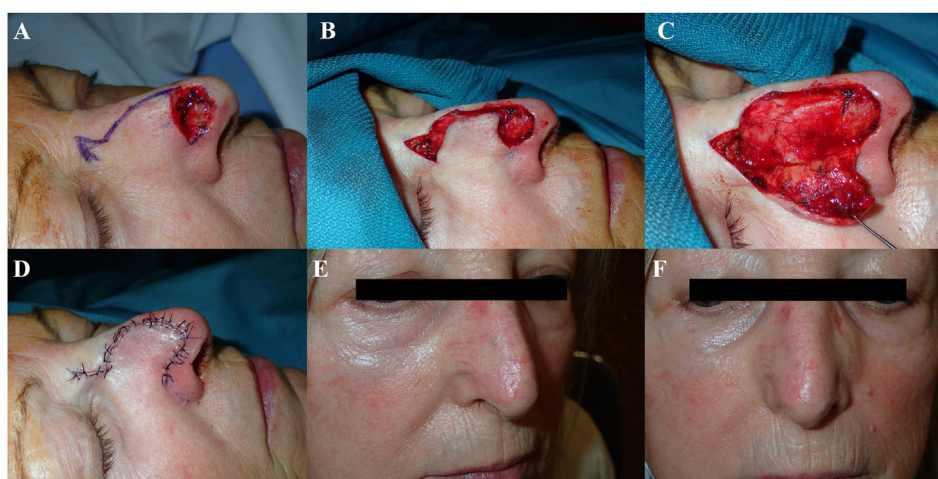


Figure 1 (A) AIRNS flap design. (B, C) Intraoperative view after mobilization of the flap. (D) Intraoperative view after closing the defect. (E, F) Clinical images at 6 months.

<https://doi.org/10.1016/j.ad.2024.01.029>

0001-7310/© 2025 AEDV. Published by Elsevier España, S.L.U. This is an open access article under the CC BY-NC-ND license (<http://creativecommons.org/licenses/by-nc-nd/4.0/>).

Please cite this article as: I. Oteiza-Rius, A. Morelló-Vicente, E.M. Gómez González et al., Advancement and Inferior Rotation Nasal Sidewall Flap for Lateral Nasal Tip Reconstruction, ACTAS Dermo-Sifiliográficas, <https://doi.org/10.1016/j.ad.2024.01.029>

pincushion and its abundant vascularization, which assures the viability of the flap in most cases.⁴

Although the AIRNS flap can be a great option for most defects affecting the nose tip, surgeons should be aware that it should not be considered in lateral defects involving the ala, where the alar rim should be spared.⁵

In conclusion, the AIRNS flap offers an excellent and simple reconstructive option for small or medium nasal tip defects. In our experience, most cases show excellent results, along with preservation of nasal function and symmetry.

Conflict of interest

The authors declare that they have no conflict of interest.

References

1. Burget GC. Aesthetic reconstruction of the tip of the nose. *Dermatol Surg.* 1995;21:419–29.

2. Skaria AM. Rotation flap reconstruction for nasal tip defect after Mohs surgery. *Dermatology.* 2006;213:118–22.
3. Zitelli JA. The bilobed flap for nasal reconstruction. *Arch Dermatol.* 1989;125:957–9.
4. Hafiji J, Salmon P, Hussain W. The AIRNS flap: an alternative to bilobed flap for the repair of defects of the distal nose. *J Am Acad Dermatol.* 2012;67:712–6.
5. Kirkland B, Zitelli JA. The bilobed flap versus the AIRNS flap for repair of distal nose defects. *J Am Acad Dermatol.* 2013;68:684–5.

I. Oteiza-Rius*, A. Morelló-Vicente, E.M. Gómez González, R. Salido-Vallejo

Dermatology Department of Clínica Universidad de Navarra, Navarre, Spain

* Corresponding author.

E-mail address: ioteiza@unav.es (I. Oteiza-Rius).