

CASES FOR DIAGNOSIS

Slow-growing Tumor on the Right Iliac Region of an 11-Year-old Girl



Tumor de crecimiento lento en la región ilíaca derecha en una niña de 11 años

Medical history

A 11-year-old girl presented with a 3 cm slow-growing lesion on the right iliac region since birth. She reported intermittent episodes of pain, bleeding, and swelling. The patient was otherwise healthy, and no family member exhibited such anomalies.

Physical examination

Physical examination revealed the presence of a localized tumor composed of scattered aggregates of small translucent yellowish, reddish, and dark reddish vesicles and papules that occasionally bled and oozed serosanguinous fluid (Fig. 1).

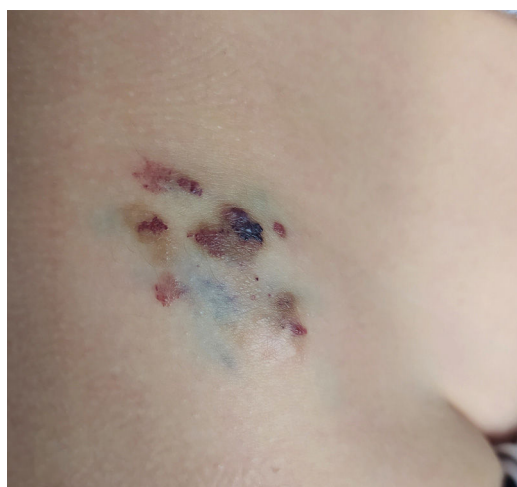

Figure 1 Clinical image. Localized tumor on the right iliac region composed of scattered aggregates of small translucent yellowish, reddish and dark reddish vesicles and papules.

<https://doi.org/10.1016/j.ad.2024.05.028>

0001-7310/© 2024 Published by Elsevier España, S.L.U. on behalf of AEDV. This is an open access article under the CC BY-NC-ND license (<http://creativecommons.org/licenses/by-nc-nd/4.0/>).

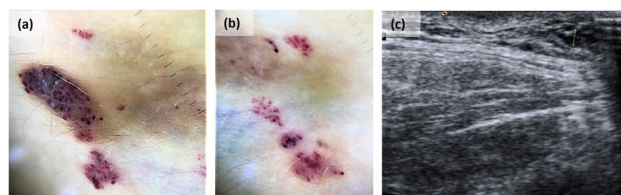


Figure 2 Dermoscopy and ultrasound images. (a) Dermoscopy of the dark reddish vesicles showed dark red/bluish lagoons. (b) Dermoscopy of the translucent vesicles showed light brown lacunas surrounded by paler septa, focal reddish areas, and hypopyon-like features. (c) Doppler ultrasound revealed a 3 mm slight thickening of subcutaneous tissue, composed of millimetric cystic structures without a Doppler signal inside consistent with a slow-flow vascular malformation.

Additional tests

Dermoscopy of the dark reddish vesicles showed dark red/bluish lagoons while the dermoscopy of the translucent vesicles revealed light brown lacunas surrounded by paler septa, focal reddish areas, and hypopyon-like features (Fig. 2a and b). Doppler ultrasound revealed a 3 mm slight thickening of subcutaneous tissue composed of millimetric cystic structures without a Doppler signal inside, which was consistent with a slow-flow vascular malformation (Fig. 2c).

Histopathological findings

Histopathology showed dilated thin-walled lymphatic vessels of variable size on the superficial dermis and hypodermis, positive for CD31 and CD34, focally positive for podoplanin D2-40, and negative for epithelial markers and WT-1 (Fig. 3).

What is your diagnosis?

Cutaneous microcystic lymphatic malformation.

Course of the disease and treatment

Due to the presence of intermittent episodes of pain and bleeding, a pulsed dye laser was used on the superficial hemorrhagic components of the lesion with posterior surgical excision of the lesion, which turned out uneventful. No lesion recurrence has been reported at the 18-month follow-up.

Comment

Cystic lymphatic malformations are rare low-flow congenital vascular malformations resulting from abnormal embryologic development of lymphatic vessels that can affect the viscera, soft tissues, and/or skin.¹ According to the International Society for the Study of Vascular Anomalies, they are now categorized based on the size of each cyst as microcystic, macrocystic, and mixed cystic.^{1,2}

Lymphatic malformations (LM) can occur as an isolated finding or as a part of syndromes such as Turner syndrome, Noonan syndrome, Klippel–Trenaunay syndrome, and Down syndrome.¹ Recently, somatic activating mutations in the phosphatidylinositol-4,5-bisphosphate 3-kinase catalytic subunit alpha (PIK3CA) gene have been reported in many patients with LM in the endothelial cells lining the malformed lymphatic vessels.¹

Cutaneous microcystic lymphatic malformations occur at birth or during infancy or early childhood. They present as clusters of translucent vesicles to flesh-colored papules that may become purple or black in the presence of bleeding. The surface of the lesions may exhibit warty hyperkeratosis. These lesions are usually found on the buttocks, inguinal region, axillary folds, proximal extremities, and oral cavity.

The most common complications are oozing, bleeding, pain, swelling, and secondary infection.³

Dermoscopy shows the presence of a lacunar/saccular pattern. Lesions containing clear fluid dermoscopically show light brown lacunae surrounded by pale septas. The different amounts of blood inside the lagoons cause focal reddish areas, diffuse pink coloration, reddish/violaceous/bluish lacunar structures, and/or hypopyon-like features.⁴

Histopathology is characterized by acanthosis and papillomatosis of the epidermis with numerous dilated lymphatic channels on the upper dermis, which may often extend to the lower dermis and even to subcutaneous tissue. The lymphatic endothelial marker podoplanin D2-40 highlights the channels. More reliable markers for lymphatic endothelium are prospero-related homeobox-1 (Prox-1), lymphatic vessel hyaluronan receptor-1 (LYVE-1), and vascular endothelial growth factor receptor 3 (VEGFR3), but they are rarely available.⁵

The treatment of microcystic lymphatic malformations is challenging due to soft tissue infiltration by micro-lymphatic channels that cannot be visualized well with current imaging modalities. Although there are no clinical practice guidelines for the management of these malformations, surgical excision is often considered the first-line therapy and has been reported to cure 75% of cutaneous lymphangiomas. Other therapeutic modalities can be chosen based on location, extension, and symptoms, such as sclerotherapy, radiofrequency ablation, carbon dioxide laser, long-pulsed Nd-YAG laser, pulsed-dye laser, cauterization, and cryotherapy with variable outcomes. Finally, sirolimus – a potent inhibitor of mTOR – is truly promising in the treatment of LM.^{2,3,6}

Informed consent

The patient in this manuscript has given written informed consent to the publication of their case details.

Funding

This research has not received specific aid from agencies of the public sector, commercial sector or non-profit entities.

Conflict of interest

The authors have no conflicts of interest to declare.

Acknowledgments

We thank the patient for providing his written consent for using clinical photographs.

We thank Rodrigo Carvalho, MD, from the Dermatology Department of Centro Hospitalar Lisboa Central, for the patient's initial assessment and skin biopsy performance.

We thank André Pinto, MD of the Plastic and Reconstructive Surgery Service of Centro Hospitalar Lisboa Norte, for the surgical excision of the lesion.

We thank Katarína Kieselová, MD, from the Dermatology Department of Centro Hospitalar Garcia de Orta, for providing the dermoscopy images.

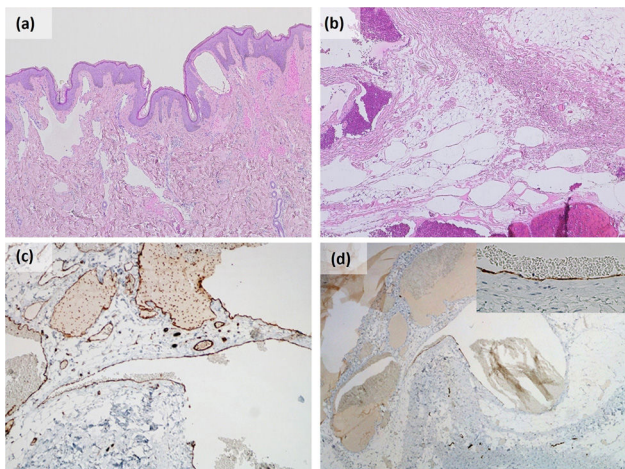


Figure 3 Histological examination revealed the presence of a benign vascular proliferation composed of irregular dilated vascular channels of variable size in dermis and hypodermis. Vascular structures are mostly thin endothelium-lined channels (c) positive for CD31 and focally positive for (d) podoplanin D2-40 with no supporting stroma. (a and b) Haematoxylin and eosin, original magnification (a) 40×; (b) 100×; (c) CD31 100×; (d) podoplanin D2-40 100×.

Data availability

Data sharing is not applicable to this article as no new data were created or analyzed in this study.

References

1. Kunimoto K, Yamamoto Y, Jinnin M. ISSVA classification of vascular anomalies and molecular biology. *Int J Mol Sci.* 2022;23:2358, <http://dx.doi.org/10.3390/ijms23042358>.
2. Hyvönen H, Salminen P, Kyrklund K. Long-term outcomes of lymphatic malformations in children: an 11-year experience from a tertiary referral center. *J Pediatr Surg.* 2022;57:1005–10, <http://dx.doi.org/10.1016/j.jpedsurg.2022.07.024>.
3. Çalışkan E, Altunel CT, Özkan CK, Tunca M. A case of microcystic lymphatic malformation successfully treated with topical sirolimus. *Dermatol Ther.* 2018;31:1–3, <http://dx.doi.org/10.1111/dth.12673>.
4. Gencoglan G, Inanir I, Ermertcan AT. Hypopyon-like features: new dermoscopic criteria in the differential diagnosis of cutaneous lymphangioma circumscriptum and haemangiomas? *J Eur Acad Dermatol Venereol.* 2012;26:1023–5, <http://dx.doi.org/10.1111/j.1468-3083.2011.04136.x>.
5. Bhawan J, Silva C, Taungjaruwina WM. Inconsistent immunohistochemical expression of lymphatic and blood endothelial cell markers in cutaneous lymphangiomas. *J Cutan Pathol.* 2013;40:801–6, <http://dx.doi.org/10.1111/cup.12184>.
6. Khunger N, Pahwa M. Microcystic lymphatic malformation (lymphangioma circumscriptum) treated using a minimally invasive technique of radiofrequency ablation and sclerotherapy. *Dermatol Surg.* 2010;36:1711–7, <http://dx.doi.org/10.1111/j.1524-4725.2010.01723.x>.

C. Correia^{a,b,*}, M. Pinho^c, S. Fernandes^{a,b}

^a *Dermatology Department, Centro Hospitalar Universitário Lisboa Norte, Lisbon, Portugal*

^b *Dermatology University Clinic, Faculty of Medicine, University of Lisbon, Lisbon, Portugal*

^c *Pathological Anatomy Laboratory, Centro Hospitalar Universitário Lisboa Norte, Lisbon, Portugal*

* Corresponding author.

E-mail address: catarinacorreia03@gmail.com (C. Correia).